



# **IBO Diplomate Examination Candidate Handbook**

**2024.2 Revision**

## Changelog

- 03/01/2016 – Initial version (2017.0)
- 04/12/2017 – Updated sample case data to match Caseworx software, added hints for Caseworx users, added detail to scoring information, updated IBO Ceph value sheet, corrected A-Pg in ceph sheet instructions from A-Po (2017.1; NM)
- 05/03/2017 – Updated changes from 2017 Annual meeting: changed Section IX scoring item “7’s in occlusion” to “7’s in occlusion / Midlines”; changed Section IX scoring item “Facial-Dental Midlines” to “Cosmetic Finishing and Detailing”; added new requirement for case submission deadline (2017.2; NM)
- 08/01/2018 – Updated imaging samples to match Caseworx sample case images (2018.2; NM)
- 08/26/2018 – Added suggestion for ceph imaging to include scale device / imprint (2018.3; NM)
- 03/29/2019 – Updated superimposition to reflect IBO changes for alignment at S-N @ S. Updated requirement for ruler to be visible and present in every radiograph (2019.1; NM)
- 05/28/2019 – Corrected UAFH/LAFH points on page 45. Previous listed LAFH points as ANS-Pg, corrected to ANS-Me (2019.2; NM)
- 03/01/2020 – Updated sample ceph values page to reflect newest score sheet (2019.3; NM)
- 06/10/2020 – Updated IBO ceph data sheet to newest version (2019.4; NM)
- 06/20/2022 – Updated definition of *lower lip to Rickett’s E-Line* with additional detail and corrected norm value in description (2019.5; NM)
- 03/08/2023 – Updated scoring to v3 with new IBO 2022 changes. Changes in scoring for sections 7, 8 (A), and 9. Changes to mailing and e-mail addresses. Updated sample case with new data, imaging, photos. (Initial release, 2023.1; NM)
- 4/28/2023 – Update required landmarks (10 points) from B point to A point in requirements and scoring (2023 IBO changes, 2023.2; NM)
- 12/2/2023 – Updated superimposition image and requirements. Updated verbiage in Diplomate Case Evaluation to emphasize case requirements. (2023 IBO changes, 2023.4; NM)
- 5/12/2024 – Updated case diagnosis (8A) skeletal to facial analysis. Updated details and hints for candidates. (2024 IBO changes, 2024.1; NM)
- 9/4/2024 – Updated IAO office mailing address (2024 IBO changes, 2024.2; NM)

## TABLE OF CONTENTS

<b>INTRODUCTION</b> .....	1
<b>ABOUT THE EXAMINATION</b> .....	1
<b>CANDIDATE ELIGIBILITY</b> .....	2
<b>APPLICATION PROCESS</b> .....	3
<b>Examination Schedule and Application Status</b> .....	3
Application Fees .....	3
<b>IBO WRITTEN EXAMINATION</b> .....	4
IBO Written Examination Development .....	4
IBO Practice Analysis.....	4
IBO Written Examination Knowledge Domains .....	4
IBO Written Examination Reading List.....	5
IBO Written Examination Sample Questions .....	5
<b>1. Case-based questions</b> .....	5
<b>2. Paired True/False questions</b> .....	5
<b>3. Exception item questions</b> .....	6
<b>4. Stand-alone questions</b> .....	6
<b>CLINICAL CASE EXAMINATION</b> .....	7
<i>Evaluation Criteria and Scoring</i> .....	7
<i>Calibration of Examiners</i> .....	8
<b>DIPLOMATE CASE EVALUATION</b> .....	9
Case SUBMISSION DEADLINE.....	10
<b>IBO Case Presentation Scoring Sheet</b> .....	11
Section One: <i>Problem List</i> – 2 Points .....	11
Section Two: <i>History</i> – 1 Point .....	12
Section Three: <i>Cephalometric Quality</i> – 2 Points .....	12
Section Four: <i>Other Radiographs</i> – 1 Point .....	13
Section Five: <i>Photographic Quality</i> – 2 Points .....	13
Section Six: <i>Study Models</i> – 2 points .....	14
Section Seven: <i>Ceph Tracings / IBO SUMMARY- 10 Points</i> .....	15
<b>Section 7 – Cephalometric Tracings (10 points)</b> .....	15
Section Eight: <i>Diagnosis and Treatment Plan- 30 Points</i> .....	17
<b>Section 8A – Diagnosis/Case analysis (20 points, each item up to 2 points)</b> .....	17

<b>Section 8B - Treatment (Tx) Plan- 10 Points (each area 2 pts)</b> .....	17
Section Nine: <i>Results – 40 Points (4 pts for each area Unless noted)</i> .....	18
Section Ten: <i>Case Analysis - 10 Points (2 pts for each area)</i> .....	19
<b>Review Criteria in Detail</b> .....	20
OVERBITE/OVERJET .....	20
CLASS I MOLAR/CANINE RELATION .....	21
PLANE OF OCCLUSION (Curve of Spee).....	21
SECOND MOLARS IN OCCLUSION .....	21
MARGINAL RIDGES .....	22
ROTATIONS .....	22
SPACES .....	23
ROOT PARALLELISM .....	23
INTRAORAL SOFT TISSUE .....	24
FACIAL AND DENTAL MIDLINES .....	24
<b>IBO CASE PRESENTATION DIPLOMATE NOTEBOOK - TEMPLATE WITH EXPLANATIONS</b> .....	25
IBO NOTEBOOK TEMPLATE SECTIONS .....	26
TABLE OF CONTENTS .....	28
Section I: Comprehensive Description of the Dentition, Complaint History, and Patient Expectations .....	29
Section II: Medical, Dental, and Case History .....	32
Section III: Cephalometric Radiographs, Tracings, and Superimpositions.....	33
Section IV: Panoramic or Full-Mouth Series RADIOGRAPHS .....	35
Section V: Patient Photographs .....	36
IBO Photographic Standards.....	37
Section VI: Study Models .....	38
Section VII: Analysis of Cephalometric Radiographs and Diagnosis .....	39
Section VIII: Case Diagnosis / Treatment Objectives, Planning , Modalities.....	54
Section IX: Case Finishing and Treatment Results .....	56
Section X: Discussion of the case .....	56
<b>IBO Policies</b> .....	59
IBO Confidentiality Policy .....	59
<b>Candidate Identity</b> .....	59
<b>Test Scores</b> .....	59
<b>Test Data Analysis and Sharing</b> .....	59
IBO Disciplinary Policy .....	59

<b>Publication of the IBO Disciplinary Policy</b> .....	59
<i>Disciplinary Procedure for Diplomate Candidates</i> .....	59
<i>Disciplinary Procedure for Diplomates</i> .....	60
IBO Appeals Policy .....	61
IBO Policy on Ethical and Professional Conduct .....	62
IBO Diplomate Recertification Policy.....	62
<b>Maintenance of Diplomate Requirements</b> .....	62
<b>CE Hours Submission Process</b> .....	62
<b>Failure to Comply with the IBO Recertification Policy</b> .....	63
Appendix A: Application Forms .....	64
Appendix B: Sample Case .....	69
Appendix C: IBO Practice Analysis Summary .....	111
Appendix D: IBO Table of Specifications Worksheet .....	114

## **Legend**

**Items in Red** indicate important information and details for each section that the candidate should pay attention to while preparing data for each item

**Items in Blue** tips to help the candidate in preparation of their case

**Items in Green** indicate information specific to candidates who are using the Casework software to prepare their cases

## INTRODUCTION

The International Board of Orthodontics (IBO) is the official certifying body of the International Association for Orthodontics (IAO) and consists of eight (8) Diplomate Members nominated by the IBO Board and confirmed by the IAO Executive Committee.

### *IBO Mission Statement*

To elevate Functional Jaw Orthopedics and Orthodontics to the highest standards of clinical excellence as provided by IAO members and to support IAO members in their Professional Advancement to Diplomate status.

### *Who Should Take the Diplomate Examination?*

The IBO is the final level of the IAO Professional Advancement Program. Members of the IAO, primarily licensed general and pediatric dentists who provide orthodontic treatment for their patients, and who have chosen to participate in the IAO Professional Advancement Program may choose to complete the Professional Advancement program by obtaining Diplomate Status.

The purpose of this manual is to provide clear and simple directions to all Diplomate candidates in their preparation for the Written and Clinical Case Examinations that comprise the Diplomate Examination.

## ABOUT THE EXAMINATION

The International Association for Orthodontics (IAO) conducts a multi-step credentialing process that assures that the individuals who qualify for Diplomate status are credible practitioners of orthodontics. The written aspect of this examination is designed to provide a reliable and a valid measure of several key knowledge areas that are related to effective orthodontic care. These areas include the following primary content domains:

- I. The underlying biomedical and clinical foundation knowledge that supports orthodontic treatment.
- II. Knowledge of the diagnostic procedures that are commonly used to assess a patient's orthodontic needs.
- III. The ability to apply diagnostic procedures to a case example including knowledge and interpretation of various diagnostic tests.
- IV. Analysis of treatment planning decisions for a variety of orthodontic cases such that the candidate may design an appropriate treatment plan or recognize deficiencies in treatment planning of existing cases.

- V. Analysis of that information which is used to facilitate diagnosis of problems with the temporomandibular joint and to design and manage treatment of those problems.

This written examination therefore provides baseline evidence of competency for the credentialing of IAO members. It is followed with evidence of effective case treatment through presentation of 10 clinical cases which demonstrate the candidate's diagnostic and treatment planning skills. The process as a whole demonstrates that an individual with a Diplomate credential has both the underlying knowledge and practice capacity necessary for such recognition.

## CANDIDATE ELIGIBILITY

To be eligible to apply for Diplomate, an IAO Member in good-standing must have completed and submitted 500 hours of orthodontic CE to IAO Headquarters and have achieved IAO Fellow Status. Finally, a candidate must present ten (10) orthodontic finished cases that he or she treated, five (5) of which must have two (2) years post-treatment records.

### Orthodontists

Specialists, who are IAO Members and seek Diplomate status are welcome to apply according to the following requirements.

#### *Board Certified Orthodontists*

An orthodontist who is an IAO Member in good standing and who has passed the boards successfully in their respective country is welcome to apply for the IBO Diplomate recognition without having to present the usual case and written examination requirements. The orthodontist must present a copy of their orthodontic certificate and board certificate with a completed specialist application for International Association for Orthodontics (IAO) Professional Advancement Diplomate recognition. The orthodontist applying for IBO Diplomate Status will be asked to publish an article in the International Association for Orthodontics' International Journal of Orthodontics. The orthodontist must present at least one (1) case at the IAO Annual Meeting.

#### *Non-Board Certified Orthodontists*

Orthodontists who are not board certified in their country of practice must meet the same requirements for obtaining the IBO Diplomate status as outlined for any other IAO Member.

## APPLICATION PROCESS

Candidates must apply to take the IBO Diplomate Examination no later than 30 days in advance of the next examination date. The application forms for both IAO Members and Specialist Members are available in appendix A of the Candidate Handbook. The applications are also available upon request from IAO Headquarters and for download online at [www.iaortho.org/diplomate](http://www.iaortho.org/diplomate). Completed applications should be returned along with the required application fee and a current photo to [worldheadquarters@iaortho.org](mailto:worldheadquarters@iaortho.org) or by post to:

IAO Headquarters

**Attn: Professional Advancement**

3610 N Oakland Ave, Ste #1n

Shorewood, WI 53211 USA

## EXAMINATION SCHEDULE AND APPLICATION STATUS

The IBO Diplomate Examination is conducted each year at the IAO Annual Meeting which is held in late March/early April in the United States. For more information on the next examination date, please contact IAO Headquarters. Candidates must pass the IBO Written Examination prior to taking the IBO Clinical Case Examination. Both exams may be taken during the same Annual Meeting or they may be taken at separate meetings. Under certain circumstances, special accommodation has been made to have IBO Clinical Cases reviewed at another time and location from the Annual Meeting, but this is subject to availability of reviewers. Please contact IAO Headquarters should you wish to request a special review of IBO Clinical Cases outside of the Annual Meeting.

After submitting a completed application candidates will receive confirmation from the IAO Headquarters that the application has been received. Prior to the Annual Meeting all candidates will be notified of the time and location of their examination.

## APPLICATION FEES

Application fees are the following:

- IBO Written Examination and IBO Clinical Case Examination (US \$700.00)
- IBO Written Examination ONLY (US \$100.00)
- IBO Clinical Case Examination ONLY (US \$600.00)\*
- IBO Diplomate Application for Specialists (US \$500.00)

*\*Candidates must have passed the IBO Written Examination prior to taking the IBO Clinical Case Examination.*



## IBO WRITTEN EXAMINATION

The first phase of the IBO Diplomate Examination is the IBO Written Examination. Every IBO Diplomate candidate must pass this examination on general orthodontic knowledge. This test can be taken after having achieved IAO Fellow status and attaining 300 hours of approved CE in Orthodontics. Once a candidate achieves a passing score of 70%, this test result remains valid for five (5) years towards your fulfilling the Diplomate requirements.

## IBO WRITTEN EXAMINATION DEVELOPMENT

The IBO Written Examination was developed by identifying key knowledge areas necessary for a general dental practitioner to have for them to provide effective orthodontic care. These knowledge areas were further expanded to include specific practice areas and techniques reported to be relevant to orthodontic treatment on a Practice Analysis Survey. The survey was distributed to approximately 50 current IBO Diplomate members.

## IBO PRACTICE ANALYSIS

The IBO Practice Analysis Survey results are included as Appendix C in the Candidate Handbook. The Survey Results are also published as a separate document available for download on the IAO website.

## IBO WRITTEN EXAMINATION KNOWLEDGE DOMAINS

The IBO Written Examination evaluates the following knowledge domains:

- Underlying Science
  - Biological Foundation
  - Growth and Development
  - Fixed Orthodontic Mechanics
- Diagnostic Procedures
  - Diagnostic Methods
  - Airway Considerations
- Treatment Planning and Outcomes
  - Functional Orthopedics
  - Finishing Procedures
  - Retention

## IBO WRITTEN EXAMINATION READING LIST

To aid in preparation for the IBO Written Examination, the IBO recommends all candidates study the following literature.

1. *Contemporary Orthodontics (4<sup>th</sup> edition)*, Proffit, et al
2. *Orthodontic and Orthopedic Treatment*, McNamara & Brudon
3. *Clinical Management of Basic Maxillofacial Appliances –Vols. 1,2,3*, Witzig/Spahl
4. *Guide to the differential Straight-Arch Technique 5<sup>th</sup> Ed.*, Peter Kesling
5. *Biomechanics and Esthetic Strategies in Clinical Orthodontics*, R. Nanda
6. *Straightwire*, McLaughlin & Bennett
7. *Begg Orthodontic Theory and Technique*, edited by Peter Kesling
8. *Orthodontics, Current Principles & Techniques*, Graber, Vanarsdall, Vig
9. *Essentials of Facial Growth*, Enlow and Hans

## IBO WRITTEN EXAMINATION SAMPLE QUESTIONS

The IBO Written Examination may contain several different types of multiple choice questions including, but not limited to, case-based questions, paired true/false questions, Exception Item questions, and stand-alone questions. The following are sample questions that will help you become familiar with the types of questions included on the IBO Written Examination.

---

### 1. CASE-BASED QUESTIONS

For case-based questions, you will be given Cephalometric measurements, photos, models and other records

Sample Question 1 - Review of the patient's records depicts a profile that would benefit from which of the following outcomes?

- A. Deepen bite
- B. Additional lip support
- C. No modification of the esthetic plane
- D. Intrusion of maxillary incisors

---

### 2. PAIRED TRUE/FALSE QUESTIONS

Sample Question 2 - The measurement, lower incisor to A-Pg indicates the need to extract in this case. The patient's soft tissue profile indicates the need to extract teeth.

- A. Both statements are true
- B. Both statements are false
- C. The first statement is true, the second false

D. The first statement is false, the second true

---

### 3. EXCEPTION ITEM QUESTIONS

Sample Question 3 - All of the factors below would affect head posture EXCEPT one? Which is that EXCEPTION?

- A. Maxillary frenum impingement
- B. Enlarged adenoidal tissue
- C. Deviated nasal septum
- D. Maxillary retention cyst – maxillary right sinus

---

### 4. STAND-ALONE QUESTIONS

Sample Question 4 - In a mixed-dentition case with a retrognathic mandible and a Class II dental relation, which of the following radiographs allows you to assess the direction of growth?

- A. Panoramic
- B. Occlusal
- C. Bite-wing
- D. Cephalometric\*
- E. Wrist

## CLINICAL CASE EXAMINATION

The IBO has developed the current IBO Clinical Case Examination to ensure that all Diplomate clinical case evaluations are scored objectively and anonymously according to standardized set of evaluation criteria. A standardized case presentation format is provided as a model to all candidates when organizing and presenting cases, and will be explored in this section of the Candidate Handbook.

With the introduction of the Caseworx software, the IBO recommends submitting your cases electronically utilizing the Caseworx software. These cases can be submitted at any time during the year and can greatly reduce the time, effort, and cost of submitting your clinical cases. Caseworx also allows examiners to score cases faster and more efficiently, returning results to the candidate with full feedback and comments, with far less hassle than physical case scoring at the Annual meeting.

The Caseworx software is available at no cost to any IAO member, for both diplomate and fellow level advancement. It can be obtained by logging into your IAO Members Only section of the IAO website. A token will be needed to activate your account. This token will be provided to you upon registration of your intent to pursue professional advancement with the IAO headquarters.

Users of Caseworx will have hints, notes, and suggestions shown to them directly in the software as they progress through their cases. The software has divided each item into detailed sections to help guide the candidate through building their case. Automated checking will be performed by the software to help minimize common case errors

## EVALUATION CRITERIA AND SCORING

Based on the standardized case presentation format, a revised set of evaluation criteria was developed and is employed and applied to all clinical evaluations. All cases are scored out of a total of 100 points, with 100 being a perfect score. The scoring system is also explored in greater detail in this section of the Candidate Handbook.

### **CALIBRATION OF EXAMINERS**

Diplomate is the culmination of the IAO Professional Advancement Program and is immediately preceded by Fellow Status, which also requires case presentations. To ensure consistency in scoring between IBO Examiners and the IAO Education Committee Case Examiners that score Fellow cases, a system of calibration has been developed. Calibration is intended to yield consistent reliable evaluation results among all case examiners, while at the same time reducing the risk of bias in scoring.

In calibration, a “Diplomate-quality” case is presented to the group. Each examiner grades the case according to the standardized set of criteria used for case evaluation. After grading, each examiner reveals their score for the case and any discrepancies in scoring are discussed in the group setting. Finally, the group arrives at a consensus for the score of the case to provide examiners with a baseline for the scoring of future cases. IBO Examiners are calibrated once a year and IAO Education Committee Examiners are calibrated on a rotating cycle, with at least half the Examiners calibrated once a year, so that the full group of IAO Education Committee Examiners is calibrated every two years.

The following section will explore the structure and content of a successful clinical case presentation, as well as the criteria used to score each case, to help candidates better understand the expectations for a successful case presentation.

## DIPLOMATE CASE EVALUATION

At this juncture, it is important to emphasize that all cases presented for the IBO Diplomate clinical examination MUST have at a minimum of the following pre-treatment and post-treatment orthodontic records:

1. Cephalometric radiographs (traced using the IBO cephalometric analysis)
2. Panoramic radiographs (or FMX),
3. Soaped or digital models
4. Photographs (intraoral and extraoral).

At least five (5) of the cases must also contain two year or greater post-treatment records. Cases lacking any of the above will NOT be evaluated.

Casework users can submit digital radiographs and cephalometric tracings via the software. Most digital radiograph systems and ceph tracing systems allow export of images in JPG or BMP format. Both file formats can be imported into your case within the software. Candidates who are utilizing film-based radiographs and/or hand-traced cephalometrics can scan their tracings with a scanner or photograph their images for inclusion. If photographing the images, be sure to look at your files on a computer and ensure that they are of high quality. Look to be sure that landmarks, annotations, and text are completely legible before using the image.

Digital models are also accepted and can be exported from most software. Users with soaped models should photograph their models on a BLACK background with macro lens and appropriate lighting.

As of April 20<sup>th</sup>, 2012, the IBO approved a change in the number of required cases for the IBO Diplomate Clinical Case Examination from at least fifteen (15) cases to at least ten (10) cases; The reason for this change was recognition that modern testing methodology suggests in an examination determining high skill, such as the IBO Diplomate, ten (10) tests of proficiency are sufficient to determine this level of skill. **Of the required ten (10) cases, five (5) must have two (2) years (or greater) post-treatment orthodontic records. The remaining five (5) cases may be “recently” finished, meaning presenting less than two (2) two years post-treatment. The IBO requires that a variety of skeletal types in the mix of cases presented.** It is strongly advised that candidates prepare IBO Board Cases for presentation by following the format presented in the Diplomate "Sample Case" (Appendix A) to ensure IBO Examiners are able to effectively review the cases.

The following is the current IBO approved case scoring sheet. This is a copy of the actual sheet used by all examiners in the evaluation of the diplomate clinical case presentations. It should be clear that it is patterned to follow the actual case presentation write-up. One important item to

note is the number of points awarded to each section. All sections should be completed as thoroughly as possible, with no areas left incomplete which would result in a point deduction.

Electronically submitted cases via Caseworx will be scored in an identical fashion, with a few minor changes. Candidates who submit electronically will get notification of their results immediately upon the examiner completing the scoring of the case and can retrieve the equivalent of this scoring sheet from within the Caseworx software under the “View Output” link of each case.

#### CASE SUBMISSION DEADLINE

All cases must be submitted **no later than three (3) weeks** before the beginning of the IAO Annual Meeting to be counted towards a candidate’s cases and any award for that year. Cases that are submitted beyond that time period may not have scoring completed in time to count towards the candidate’s completion for that year. Cases scored after the deadline will be counted in the candidate’s record, but will delay the candidate’s successful completion of their fellow/diplomate until the following year’s annual meeting.

Users who will be presenting physical cases must also follow this deadline in notification of the IAO Headquarters that they will be presenting their cases at the annual meeting. Notification after this deadline can result in the candidate not receiving a time slot for scoring. Candidates are also responsible and required to register a time slot for scoring their cases upon arrival at the annual meeting.

Caseworx users are encouraged to submit cases as they are completed on the user’s side. Caseworx cases can be submitted at any time throughout the year and examiner’s will be notified immediately of new cases to be scored. It is highly recommended to utilize Caseworx and submit cases early to ensure that cases will be completed, passed, and recorded on time.

# IBO Case Presentation Scoring Sheet

**Candidate/Case Number:** \_\_\_\_\_

← Each candidate is assigned a unique identification number to maintain strict anonymity between the candidate and the examiners.

**Title Page** \_\_\_\_\_

← Examiners will indicate if these two elements are included in the case presentation

**Table of Contents** \_\_\_\_\_

- Casework users will have these items automatically generated based on case information when a new case is started

---

**SECTION ONE: PROBLEM LIST – 2 POINTS**

→ In Section One, examiners will look for a brief summary of problems reported by the patient. A detailed evaluation of the patient should be provided to draw a complete picture of the patient’s case; remember, the examiner was not present for your patient’s treatment progress.

Skeletal Features	_____	Other	_____
Dental Features	_____	Chief Complaint	_____
Soft Tissue Features	_____	Pt Expectations	_____
Occlusion	_____	Habits	_____

\_\_\_\_\_ **Section One Subtotal**  
*(Max 2 points)*



**SECTION TWO: HISTORY – 1 POINT**

→ In Section Two, examiners will look for brief relevant comments about the medical and dental history of the patient. A detailed history of the patient should be provided to draw a complete picture of the patient’s case; remember, the examiner was not present for your patient’s treatment progress, so “paint a good picture” of your patient!

Med Hx \_\_\_\_\_

Dent Hx \_\_\_\_\_

\_\_\_\_\_ **Section Two Subtotal**

*(Max 1 point)*

**SECTION THREE: CEPHALOMETRIC QUALITY – 2 POINTS**

→ In Section Three, examiners evaluate the quality of the cephalograms.

Cephalogram Quality \_\_\_\_\_

All Hard Tissue Visible \_\_\_\_\_

All Soft Tissue Visible \_\_\_\_\_

\_\_\_\_\_ **Section Three Subtotal**

*(Max 2 points)*

- Be sure that digital radiographs are clear and all pertinent details are visible. Most digital radiographic software allows the user to make numerous adjustments to imaging, but such “tweaking” can result in loss of detail or information.

## SECTION FOUR: OTHER RADIOGRAPHS – 1 POINT

→ In Section Four, examiners evaluate the quality of the panoramic or other provided radiographs. Only the pano is required, but include others as needed to support your case especially if TMD, apnea, or other complex cases.

Pan &/or FMX	_____
TC &/or Tomogram, if needed	_____
Other (MRI, Occlusal x-ray, photo tracing, etc)	_____

\_\_\_\_\_ **Section Four Subtotal**

*(Max 1 point)*

- Be sure that digital radiographs are clear and all pertinent details are visible. Most digital radiographic software allows the user to make numerous adjustments to imaging, but such “tweaking” can result in loss of detail or information.

## SECTION FIVE: PHOTOGRAPHIC QUALITY – 2 POINTS

→ In Section Five, examiners evaluate the quality of the photographs.

Extra-oral	_____
Intra-oral	_____

\_\_\_\_\_ **Section Five Subtotal**

*(Max 2 points)*

- Be sure that digital photographs are clear, sharp, properly colored, and cropped appropriately. Also, be sure that your images are at correct angles with no obstructions and show all required features.

**SECTION SIX: STUDY MODELS – 2 POINTS**

→ In Section Six, examiners evaluate the quality of soaped models.

Pre-treatment	_____
Post-treatment	_____
2-year post-treatment	_____

\_\_\_\_\_ **Section Six Subtotal**

*(Max 2 points)*

- Digital models can be exported from the source software for inclusion into your Caseworx case file. Physical models can be photographed for inclusion. Be sure that the required imaging guidelines are followed for either method.

**Review**

Up to this point there have been a total of 10 possible points that can be awarded

**SECTION SEVEN: CEPH TRACINGS / IBO SUMMARY- 10 POINTS**

→ A proper and complete ceph tracing allows gathering accurate objective data for your diagnosis. As such, points in this section are awarded with:

- 1) Properly and accurately selected landmarks on the ceph radiograph – a dedicated sheet with just the landmarks
- 2) Proper selection of landmarks on all tracings, overlays, superimpositions resulting in accurate measurements
- 3) A **complete** IBO Cephalometric Summary and relevant data values & comments in **all** areas

---

**SECTION 7 – CEPHALOMETRIC TRACINGS (10 POINTS)**

→ Are the landmarks located correctly? Each correctly identified tracing point is worth one point. **NOTE: landmarks should be identified on a separate overlay of the ceph image showing only the landmarks!**

ANS	_____
condylion	_____
gonion	_____
menton	_____
nasion	_____
orbitale	_____
PNS	_____
pogonion	_____
A point	_____
sella	_____

\_\_\_\_\_ **Section 7 Subtotal**

The following represents a copy of the Data Sheet:



### IBO Cephalometric Data Sheet

	Norm	Pre-Tx	Post-Tx	Post +2 Yr												
<b>1. Analysis of Growth</b>																
A. Stage of Growth (CVMS)	I – VI	_____	_____	_____												
B. Direction of Growth																
Y-Axis to SN	66° ± 3°	_____	_____	_____												
Y-Axis to FH	59° ± 2°	_____	_____	_____												
<b>2. Analysis of Airway</b>																
A. Upper Airway (Nasopharynx)	8-18mm	_____	_____	_____												
B. Lower Airway (Oropharynx)	10-12mm	_____	_____	_____												
<b>3. Analysis of Skeletal Vertical</b>																
A. FMA	25° ± 4°	_____	_____	_____												
B. LAFH (ANS to Mn), mm	58-72mm	_____	_____	_____												
C. UAFH-LAFH / TAFH Ratio, percent	45-55% Adult 50-50% Child	_____	_____	_____												
D. SN to GoMe (Steiner)	32° ± 3°	_____	_____	_____												
<b>4. Analysis of Skeletal Sagittal</b>																
A. Co-A (Mx Len), mm		_____	_____	_____												
B. Co-Gn (Mn Len), mm		_____	_____	_____												
C. Difference (Mn – Mx Len), mm		_____	_____	_____												
<table border="1" style="display: inline-table; margin-right: 20px;"> <thead> <tr><th>Age</th><th>Mm</th></tr> </thead> <tbody> <tr><td>6</td><td>17</td></tr> <tr><td>9</td><td>20</td></tr> <tr><td>12</td><td>23</td></tr> <tr><td>14</td><td>25</td></tr> <tr><td>16</td><td>27</td></tr> </tbody> </table>					Age	Mm	6	17	9	20	12	23	14	25	16	27
Age	Mm															
6	17															
9	20															
12	23															
14	25															
16	27															
D. Wits (Jacobson), mm		_____	_____	_____												
<table border="1" style="display: inline-table; margin-right: 20px;"> <thead> <tr><th>Class</th><th>Mm</th></tr> </thead> <tbody> <tr><td>I</td><td>-2 to 2</td></tr> <tr><td>II</td><td>&gt;= 3</td></tr> <tr><td>III</td><td>&lt;= -3</td></tr> </tbody> </table>					Class	Mm	I	-2 to 2	II	>= 3	III	<= -3				
Class	Mm															
I	-2 to 2															
II	>= 3															
III	<= -3															
E. SNA, deg	82° ± 3°	_____	_____	_____												
F. SNB, deg	80° ± 3°	_____	_____	_____												
G. ANB, deg		_____	_____	_____												
<table border="1" style="display: inline-table; margin-right: 20px;"> <thead> <tr><th>Class</th><th>Deg</th></tr> </thead> <tbody> <tr><td>I</td><td>0-4°</td></tr> <tr><td>II</td><td>&gt;= 5°</td></tr> <tr><td>III</td><td>&lt;= 0°</td></tr> </tbody> </table>					Class	Deg	I	0-4°	II	>= 5°	III	<= 0°				
Class	Deg															
I	0-4°															
II	>= 5°															
III	<= 0°															
H. Na ⊥ - A pt	1mm ± 2mm	_____	_____	_____												
<b>5. Analysis of Dento-Alveolar Relations</b>																
A. IMPA (Incisor Mn Plane Angle), deg	90° ± 5°	_____	_____	_____												
B. Interincisal Angle (Upper 1 – Lower 1), deg	131° ± 4°	_____	_____	_____												
C. Mx Incisor (Upper 1) – SN, deg	103° ± 2°	_____	_____	_____												
D. Mn Incisor (Lower 1) to A-Pg, mm	-1 to 3mm	_____	_____	_____												
<b>6. Analysis of Soft Tissue</b>																
A. Esthetic Line (Rickett's), mm	-2mm ± 2mm	_____	_____	_____												
B. Naso-labial Angle, deg	102° ± 6°	_____	_____	_____												
C. Lip Seal	Yes	Yes / No	Yes / No	Yes / No												

**SECTION EIGHT: DIAGNOSIS AND TREATMENT PLAN- 30 POINTS**

**SECTION 8A – DIAGNOSIS/CASE ANALYSIS (20 POINTS, EACH ITEM UP TO 2 POINTS)**

- These items are based on your ceph measurements as well as narratives. Casework provides text boxes for the candidate to enter the details into. Each section provides a short description and hints to help the candidate determine the required data. Be sure to be as detailed as possible in your answers

→ This section examines the quality and resultant diagnosis of the case. Two (2) points are possible for each criterion that is addressed sufficiently and effectively.

Growth Stage/Direction	_____	Sagittal	_____
Functional	_____	Transverse	_____
Airway	_____	Dental	_____
Facial Analysis	_____	Soft Tissue	_____
Vertical	_____	TMJ/TMD	_____

\_\_\_\_\_ **Section 8A Subtotal**

**SECTION 8B - TREATMENT (TX) PLAN- 10 POINTS (EACH AREA 2 PTS)**

- These items are all narratives. Casework provides text boxes for the candidate to enter the details into. Each section provides a short description and hints to help the candidate determine the required data. Be sure to be as detailed as possible in your answers

→ This section requires a description of all five aspects of the treatment in order to receive points for each section.

Treatment Objectives	_____
Treatment Plan	_____
Limitations	_____
Mechano-therapy	_____
Evaluation of Tx Progress	_____

\_\_\_\_\_ **Section 8-2 Subtotal**

**SECTION NINE: RESULTS – 40 POINTS (4 PTS FOR EACH AREA UNLESS NOTED)**

→ This section will be evaluated using case details provided in the previous sections

Plane of Occlusion (2 pts)	_____
Marginal Ridges (2 pts)	_____
Soft Tissue (2 pts)	_____
Retention (2 pts)	_____
OJ/OB	_____
Cuspid/Molar	_____
7's in occlusion/Midlines	_____
No Rotations	_____
Spaces Closed	_____
Root Parallelism	_____
Cosmetic Finishing & Detailing	_____
Long-term Stability	_____

\_\_\_\_\_ **Section 9 Subtotal**

- This section is also a narrative section that requires the candidate to enter detailed text information. Casework provides descriptions and hints for each section to help the candidate navigate these fields. Be sure answers are as detailed as possible with measurements, values, and data included.

**SECTION TEN: CASE ANALYSIS - 10 POINTS (2 PTS FOR EACH AREA)**

→ This section will evaluate your finished “case analysis” include aspects that relate the case, from finished esthetic results, skeletal and dental goals, relate the superimpositions to the case pre-treatment and post-treatment, assess the case in degree of difficulty and finally was the objective of treatment achieved.

Facial Esthetics	_____
Skeletal/Dental	_____
Superimpositions	_____
Difficulty of Case	_____
Tx Objectives Achieved or Not Achieved	_____

\_\_\_\_\_ **Section 10 Subtotal**

- This section is also a narrative section that requires the candidate to enter detailed text information. Casework provides descriptions and hints for each section to help the candidate navigate these fields. Be as clear and honest as possible while formulating your answers. Also be detailed in answers to provide supporting information to any items discussed.

**FINAL RESULTS**

**TOTAL POINTS (sum of the 10 subtotals)** \_\_\_\_\_

**Examiner** \_\_\_\_\_ **Date:** \_\_\_\_\_



## REVIEW CRITERIA IN DETAIL

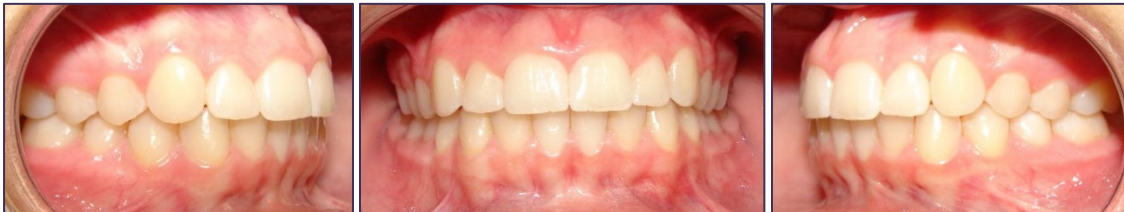You can clearly see that both Section VII and VIII (10 & 30 points each) and Section IX (40 points) of a case presented are the categories that carry the most point potential (80 possible points). The IBO has developed specific criteria that are used in the evaluation of the Section IX criteria.

- Acceptable Overbite/ Overjet?
- Proper plane of occlusion
- Class I molar/canine function?
- Flat plane of occlusion?
- 2nd molars in occlusion?
- Marginal height discrepancies?
- Rotations?
- Spaces?
- Root parallelism?
- Intraoral soft tissue considerations?
- Facial and dental midlines?
- Correct and complete cosmetic finishing and detailing?
- Good long-term stability?

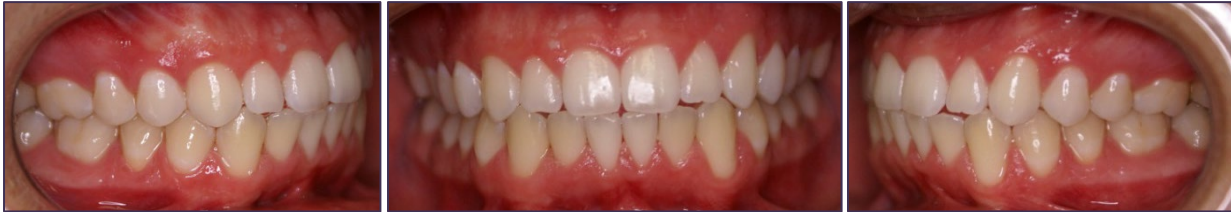The following pages discuss each criterion in more detail and more clearly describes how each is graded and measured.

### OVERBITE/OVERJET

The IBO standard accepted range is 1-3mm in either for there to be NO deductions; the **overjet** will be measured from the labial surface of the lower central incisor to the lingual incisal edge of the upper central incisor. The **overbite** will be measured from the incisal edge of the lower central incisor to the incisal edge of the upper incisor when models are in maximum intercuspation (MI); the simplest way to arrive at this is to place models in MI then carefully with a fine pencil tip mark a horizontal line across the upper incisor edge drawing onto the lower labial surface-then measure from the lower incisal edge to this line. Any deviation from that range, such as 4mm of overbite and/or overjet will incur a 2-point deduction. Conversely, a zero overbite/overjet will incur a 2-point deduction. In this section the MAXIMUM combined point deduction will be 4 points.



(These photos demonstrate acceptable overjet/overbite, Class I canine and molar relation)



(These photos demonstrate Unacceptable overjet/overbite, yet acceptable Class I canine and molar relation; this case would incur full 4-point deduction in the OB/OJ area)

### CLASS I MOLAR/CANINE RELATION

Class I molar relation is considered ideal when the maxillary first molar mesial buccal cusp intimately intercuspatates into the buccal groove of the lower first molar. A Class I cuspid relation is described as when the canine tip fits intimately between the distal incisal edge of the lower canine and the mesial surface of the buccal cusp of the lower first bicuspid. The IBO standard accepted range for either is 1mm in EITHER direction; that is the molars or canines can be 1mm in either the Class II or III direction to incur NO deductions. Any further deviation per 1mm in either direction by either canines or molars will incur a 1-point deduction per tooth; the maximum total deductions will also be 4 points in this category.

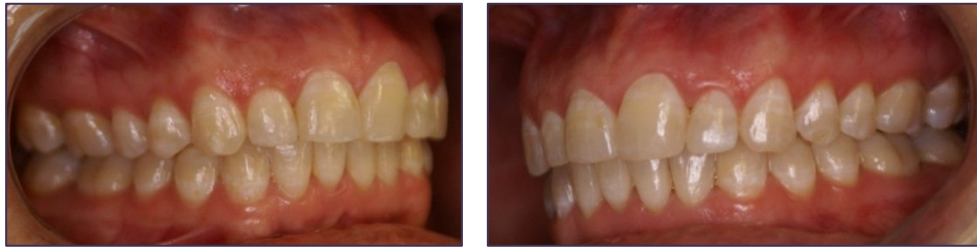### PLANE OF OCCLUSION (CURVE OF SPEE)

The IBO accepted standard is a plane of occlusion that when measured from second molars to canines with a flat instrument (both right and left sides independently), at its DEEPEST point will be 0-2 mm to incur NO deductions. Any deviation per 1mm will incur a 1-point deduction per side up to a maximum of 2 points in this category.

### SECOND MOLARS IN OCCLUSION

The IBO considers the second molar occlusion important. The cases that have been recently evaluated have demonstrated that more often than not, the second molars are in INCOMPLETE occlusion. Therefore, any measurable disclusion in mm from the lingual cusp tip to the depth of

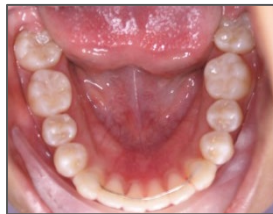the central fossa will incur a corresponding 1mm deduction per 1mm of disclusion; once again to a maximum of 4 points in this area.



(The photos demonstrate acceptable second molar occlusion)

### MARGINAL RIDGES

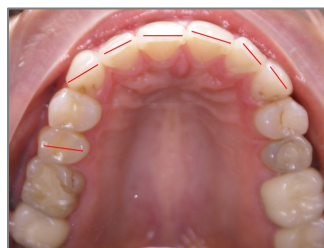The IBO standard is LEVEL marginal ridges up to 1mm to incur NO deductions. Any marginal height discrepancies beyond 1mm will incur a 1-point deduction per tooth, up to a maximum 2 points in this section. (Common areas of marginal ridge discrepancies are found in both upper and lower 6-7, 4-5 areas.)



(This lower arch demonstrates marginal ridge discrepancies between the 6-7 areas as well as unacceptable mesio-rotations of the L6's)

### ROTATIONS

The IBO considers as acceptable that all teeth be aligned along the long axis and centered buccolingually; this position will be referred to as ZERO degrees. Any deviation of 15 degrees in either distal or mesial direction will incur a 1-point deduction (per tooth), a 30-degree rotation will incur a 2-point deduction (per tooth), and a 45-degree rotation will incur a 4-point deduction. This section will also have a maximum 4-point deduction.



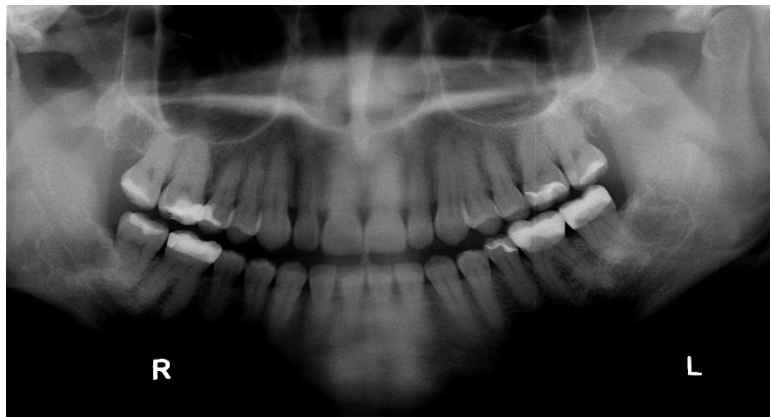(This arch demonstrates several teeth with varying degrees of rotations. This case would incur the maximum deduction of 4 points in this section.)

## SPACES

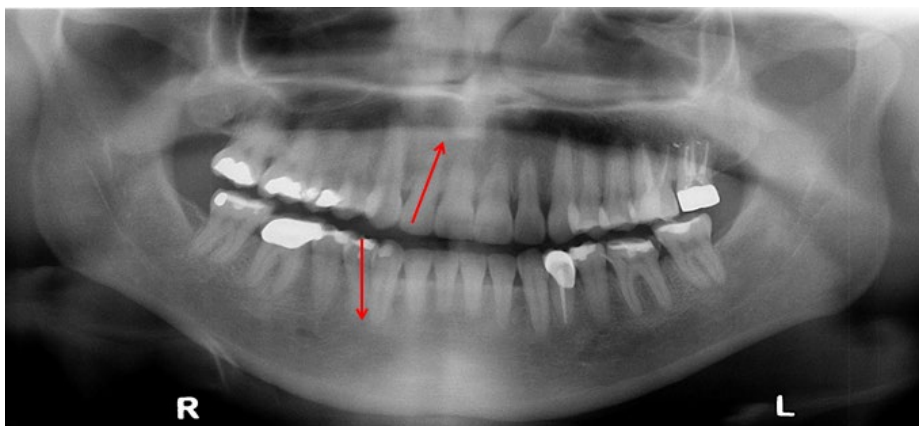
The IBO standard is NO spaces. Any measurable space of 1mm or more will incur a corresponding 1-point deduction or more depending on the measured space. Once again this will have a maximum 4-point deduction in this category.

## ROOT PARALLELISM

This section will be evaluated on the basis of the panoramic radiograph; the IBO recognizes the limitations of this method to clearly evaluate root alignment in the upper canine/first bicuspid and the lower canine/lateral areas. The IBO standard is parallel roots with a slight distal angulation. Any tooth which deviates from this parallel relation will incur a 1-point deduction per tooth (except the above-mentioned areas); any area where there is root contact will incur a 2 point deduction to a maximum 4 point deduction in this section.



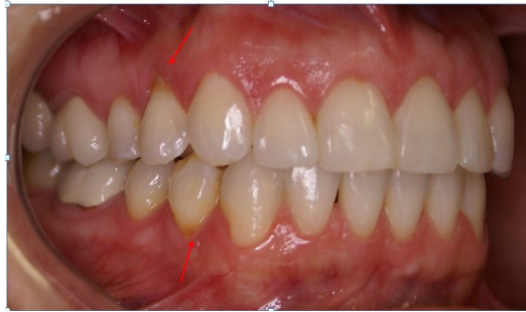(The above panoramic radiograph demonstrates acceptable root angulation even when both the upper canine and upper first bicuspid roots appear to be in contact.)



Root angulation problems UR2 and LR4


### INTRAORAL SOFT TISSUE

This section will be evaluated using soaped models and photographs. The IBO considers intraoral tissue to be in health when there is **NO** evidence of **POST** treatment soft tissue dehiscence (recession) anywhere. Any tooth that demonstrates a post-treatment soft tissue recession will be deducted 1 point per 1mm per area to a maximum of 2 points in this section.



### FACIAL AND DENTAL MIDLINES

The IBO considers it a worthy treatment goal to end with both skeletal and dental midlines to be coincident; pre-treatment conditions and age of patient will be considered when evaluating skeletal midline evaluation. The IBO dental midline standard is 0-1mm in either direction to incur **NO** deductions. Any additional increase in deviation will incur a 1-point deduction per area to a maximum of 4-point deduction in this section.



(Based on the above photos this patient appears to have both upper dental midline deviated to the right side ~1-2mm, as well the lower dental midline deviated to the right 4-5 mm; significant skeletal midline deviation and cant to the right side- this would not be an acceptable diplomate case)

## IBO CASE PRESENTATION DIPLOMATE NOTEBOOK - TEMPLATE WITH EXPLANATIONS

The following notebook template shows the case presentation format that the IBO requires for all presented cases. There is basic information presented in each section in **red** and is meant to help clarify what is expected to be included. **Blue boxes** include notebook preparation tips. **Green items** indicate tips and procedures for digital case preparation using the Caseworx software. There is also information below each cephalometric measurement section to help familiarize the candidate with the IBO cephalometric analysis. Please try to understand that these measurements are not intended to suggest that this is the only or best way to evaluate a case, but is the consensus result of expert opinions within our present and past boards.

---

### TEMPLATE START

→ A cover sheet is required for each case presentation notebook, similar to the one below. The cover sheet is automatically generated in Caseworx.

**COVER SHEET**

# THE INTERNATIONAL BOARD OF ORTHODONTICS

## DIPLOMATE CASE PRESENTATION NOTEBOOK TEMPLATE

## IBO NOTEBOOK TEMPLATE SECTIONS

THE TITLE PAGE

TABLE OF CONTENTS

### PREPARATION TIP

A table of contents should be included after the cover sheet for physical case presentation

Caseworx users do not need a table of contents as it is automatically generated

SECTION ONE: Comprehensive description of the Dentition, Chief Complaint and Patient Expectations

SECTION TWO: Pertinent Medical and Dental History

SECTION THREE: Cephalometric Radiographs

SECTION FOUR: Panoramic, Full Mouth Series, Transcranial or Tomographic radiographs, other radiographs or records

SECTION FIVE: Patient Photographs

SECTION SIX: Study Models

SECTION SEVEN: Analysis of Cephalometric Radiographs and IBO Ceph Values Summary

SECTION EIGHT: Case Diagnosis, Treatment Objectives, Treatment Planning and Treatment Modalities

SECTION NINE: Case Finishing and Treatment Results

SECTION TEN: Discussion of the Case

**Preparation Tip**

Text highlighted in yellow is provided as an example and should be replaced with information unique to each case.

**IBO CASE I.D. JJ 83-103****AGE; 12 years, 3 months****June 17, 1983**

→Case ID and age should be provided here.

**Caseworx Users**

These fields are generated automatically based on values entered or selected during the creation of the digital case

**THE FUNCTIONAL AND FIXED ORTHODONTIC  
TREATMENT OF THIS CLASS II DIVISION 2 PATIENT**

→The text above should describe the type of case presented)

**IS PRESENTED IN PARTIAL  
FULFILLMENT OF THE CLINICAL DIPLOMATE  
REQUIREMENTS OF THE INTERNATIONAL BOARD OF  
ORTHODONTICS**

**PATIENT ETHNICITY: ASIAN/Chinese** (describe accurately as some measurement norms are dependent on the patient's ethnicity)

**DOCTOR I.D. CODE: BR548** (This should be your IBO ID Code)

**Caseworx Users**

The Doctor ID code is automatically generated when you create your Caseworx account



**Preparation Tip**

Replace all X's with the page numbers in your own notebook.

# TABLE OF CONTENTS

**Section I:** Comprehensive Description of the Dentition, Chief Complaint and Patient Expectations ..... Page X

**Section II:** Pertinent Medical and Dental History ..... Page X

**Section III:** Cephalometric Radiographs and Hand Tracings ..... Page X

**Section IV:** Panoramic, Full Mouth Series, Transcranial or Tomographic Radiographs ..... Page X

**Section V:** Patient Photographs ..... Page X

**Section VI:** Study Models ..... Page X

**Section VII:** Analysis of Cephalometric Radiographs and Diagnosis ..... Page X

**Section VIII:** Treatment Objectives, Treatment Planning and Treatment Modalities ..... Page X

**Section IX:** Case Finishing and Treatment Results ..... Page X

**Section X:** Discussion of the Case ..... Page X

**Casework Users**

Pagination of a digital file is unavailable, as the file is technically one large page. Only if the document is printed would physical page numbers exist. Candidates who are submitting their cases electronically can leave the 'X' in the TOC. However, users that will be printing their case MUST match the page numbers accordingly before printing.

## SECTION I: COMPREHENSIVE DESCRIPTION OF THE DENTITION, COMPLAINT HISTORY, AND PATIENT EXPECTATIONS

This section will include soft tissue evaluation, skeletal evaluation, dental evaluation, functional evaluation, description of special considerations, chief complaint(s), and expectations.

### Soft Tissue Evaluation

- Facial type:  
→ dolichocephalic, mesocephalic, brachycephalic? Vertical, horizontal, neutral?
- Facial symmetry:  
→ Describe your findings for the case
- Profile:  
→ Examples: Straight, convex, concave
- Nose:  
→ Examples: Acceptable, large, small
- Nasolabial angle:  
→ Examples: Open, closed, aesthetic
- Lips:  
→ Examples: Shape, position, competency
- Smile line:  
→ Examples: High, low, normal
- Gingival Display:  
→ Examples: Deficient, acceptable, moderate excessive, excessive
- Tonsillar tissue:  
→ Examples: Describe your findings
- Mento-labial sulcus:  
→ Examples: Evaluation of mento-labial crease

### Soft Tissue Evaluation (cont.)

- Soft tissue chin:  
→ Examples: Acceptable, small, or large

- Other:
  - Include any other soft tissue information you wish to mention

### Skeletal Evaluation

- Maxilla:
  - Examples: Orthognathic, retrognathic, prognathic, other
- Mandible:
  - Examples: Orthognathic, retrognathic, prognathic, growth direction
- Facial height:
  - Describe your findings for this case
- Palate:
  - Examples: Size, shape, depth
- Skeletal midlines:
  - Indicate whether midlines are on or off, and your findings
- Genetic conditions:
  - Describe your findings for this case
- Radiographic findings:
  - Describe your findings for this case
- Bony chin:
  - Describe your findings for the case
- Skeletal bite:
  - Describe your findings for the case

### Dental Evaluation

- Dental classification:
  - Dental Classification – Class I, Class II, Class III, Div. 1, Div. 2
- Midlines:
  - Indicate if the midlines are on or off and describe
- Overbite/overjet:
  - Describe your findings for the case

- Open bite:  
→ Examples: Anterior, posterior
- Closed bite:  
→ Indicate if there is a crossbite (yes or no) and describe
- Cross bite:  
→ Examples: Anterior, posterior
- Model analysis:  
→ Describe your findings for this case
- Arch shapes:  
→ Describe your findings for this case
- Arch length:  
→ Describe your findings for the case
- Caries Index:  
→ Describe number of restorations, periodontal condition, hygiene, etc.
- Radiographic findings:  
→ Describe number of restorations, missing teeth, supernumerary teeth, impacted teeth, mesiodens, etc.

#### Functional Evaluation (TMJ? Occlusion?)

Describe your findings of the muscles and movements of the TM joint.

#### Special Considerations

In this section, describe any extraordinary circumstances that may affect the case as a whole.

#### Patient's Chief Complaint

In this section, include a written account of the patient's needs and complaints about their teeth and smile.

#### Patient's Expectations

In this section, include a written account of the patient's wants for the treatment you will provide.

## SECTION II: MEDICAL, DENTAL, AND CASE HISTORY

This section will include the medical, dental, and other histories of the patient. Remember that the examiner has never seen or examined the patient! These narratives need to paint an accurate and clear picture of the patient.

Be sure to note items do not have anything to report as “within normal parameters” or “nothing extraordinary”.

### Medical History

In this section, include any medical history information that you feel is pertinent this case. Include a copy of the patient’s self-reported health history document that the patient completed at your office.

### Dental History

In this section, include any dental history information that you feel is pertinent to this case. Include a copy of the patient chart showing a charting of all teeth that are present.

### Accident/Causative History

Describe anything reported by the patient that may have been a cause of the condition they are seeking treatment for. For TMD or apnea cases, this may be the condition that resulted in their situation.

### Physical Examination

Note and describe any conditions observed during a physical examination of the patient.

### Complaints History

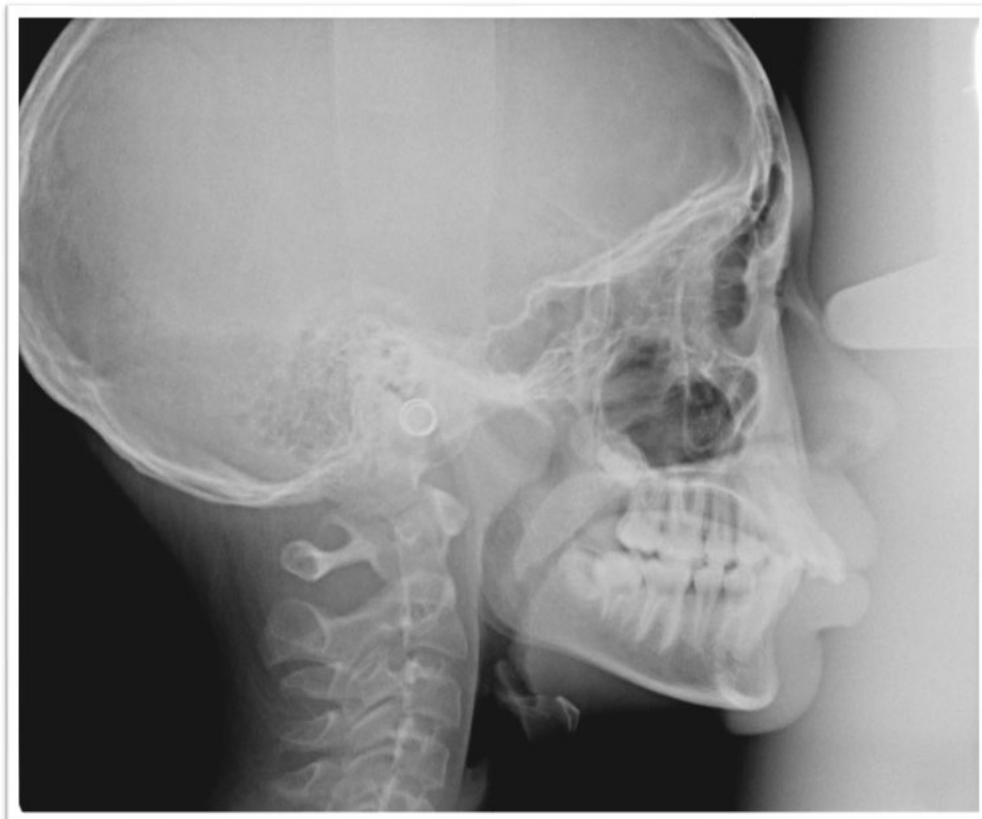
Describe the complaints of the patient seeking treatment. This is especially important for TMD and apnea cases!

### Clinical Observations and Vital Statistics

Describe observations of the patient that may contribute to their condition and abnormalities in vitals observed. Especially important in TMD and apnea cases.

### SECTION III: CEPHALOMETRIC RADIOGRAPHS, TRACINGS, AND SUPERIMPOSITIONS

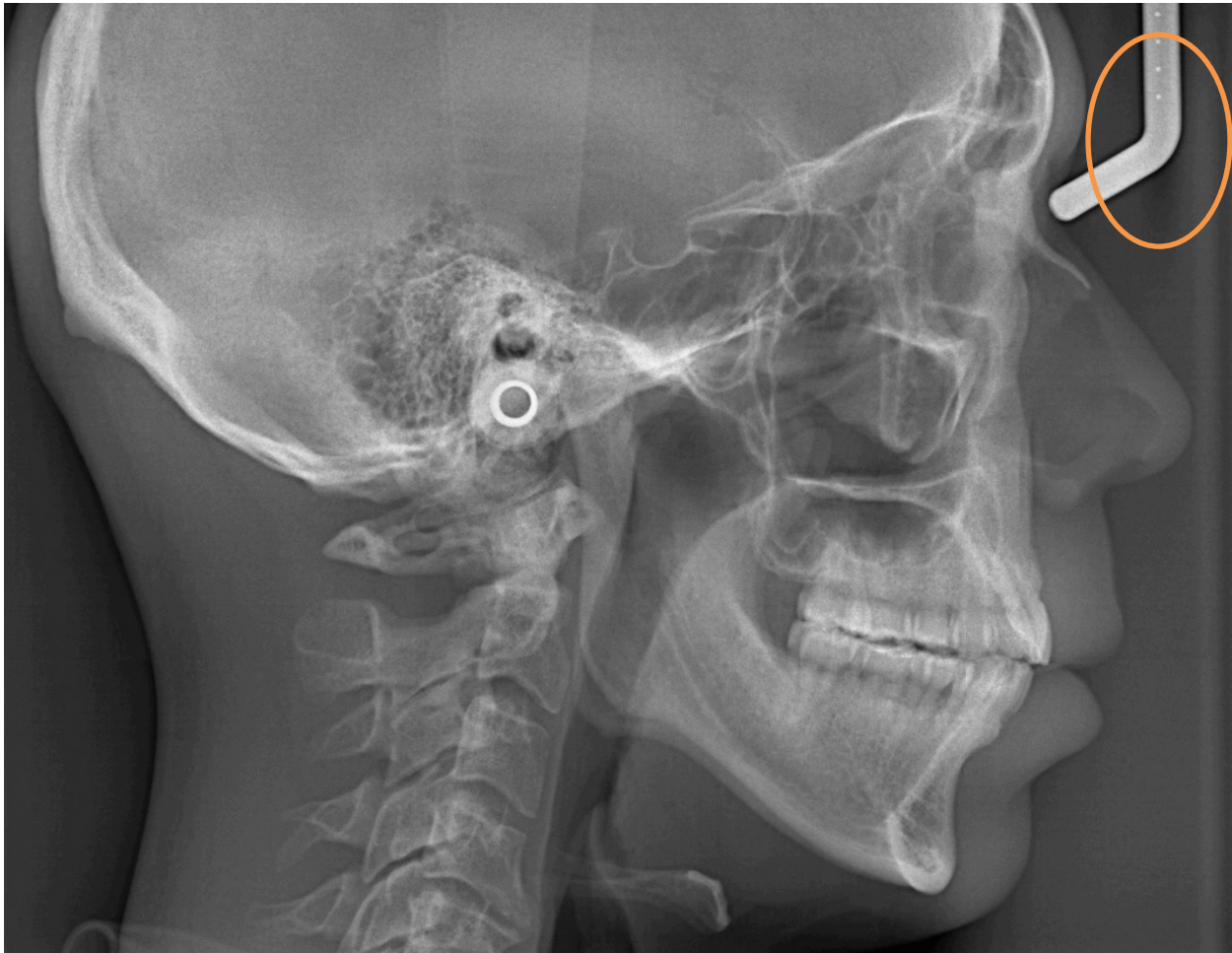This section must include cephalometric radiographs and tracings that are Pre-Treatment, Post-Treatment, and two or more years Post-Treatment (when necessary). Manual tracings are preferred, but digital tracings are accepted. Beware that some digital tracing systems may not result in the highest accuracy and should be carefully checked!



→ ALL of the following must be clearly visible on the exposed radiographs:

- A. Anatomic hard tissue landmarks
- B. Soft tissue landmarks
- C. Tracing
- D. These cephalometric radiographs and tracings should be mounted and identified by date on separate pages for pre-treatment, post-treatment and when needed two or more years post-treatment.

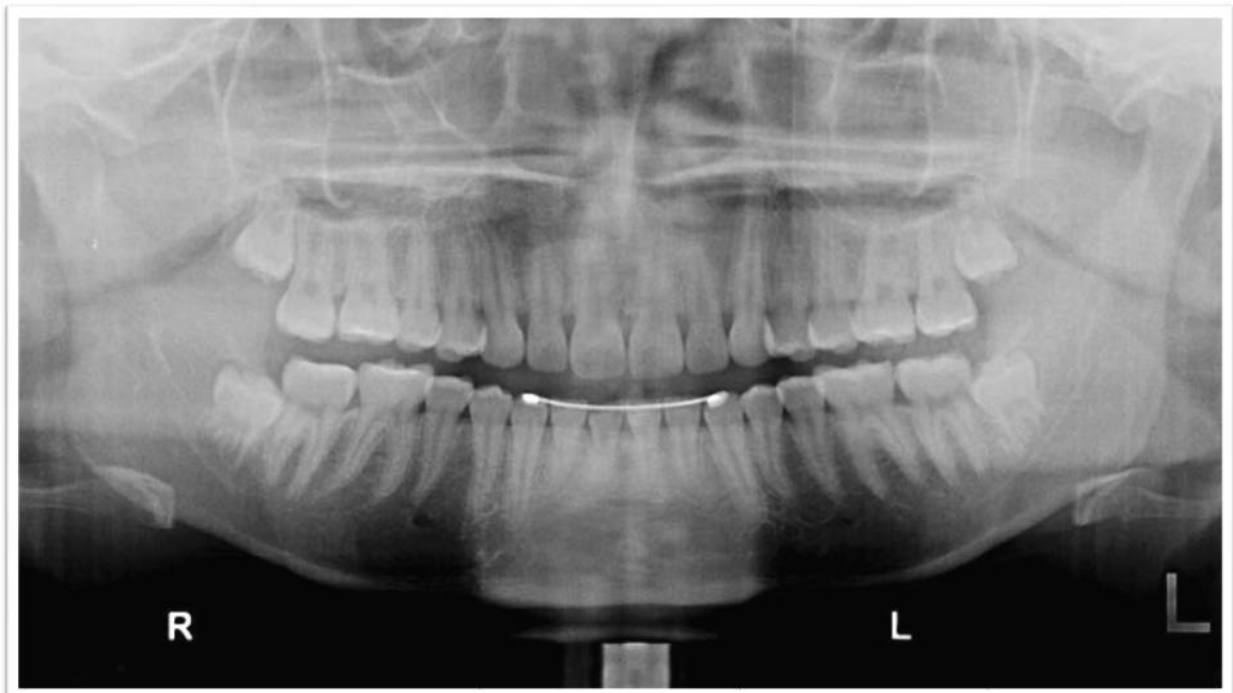
- E. **Scale devices or imprints MUST be included in the radiographic image.** Some digital x-ray systems have an option to include a reference scale when exporting the image. For systems which do not have this option, and for film systems, radiopaque devices can be placed or adhered to the device to add a reference scale “ruler” in the image taken. The following image shows a scale device attached to the guide in the upper-right that is incremented in 10mm gradations:



**SECTION IV: PANORAMIC OR FULL-MOUTH SERIES RADIOGRAPHS**

Cases need to have at least a panoramic or full mouth series; these should be mounted and identified by date on separate pages. Radiographs need to be pre-treatment, post-treatment, and when necessary two or more years post-treatment. Other pertinent radiographs should be included, especially in TMD or apnea cases, as supporting evidence.

Be sure that radiographs are taken with items such as tongue bars or rings are removed!



1. Panoramic radiograph - Anatomic hard and soft tissue landmarks clearly visible
2. Full Mouth series – Anatomic hard tissue landmarks clearly visible including all periapical areas (if used)
3. Occlusal Radiographs
4. Any other pertinent diagnostic images (tomo, SMV, lateral, MRI)




## SECTION V: PATIENT PHOTOGRAPHS

- A. Intra and extra-oral photographs should be arranged in the format seen on the following page. The following is the minimum requirement for each phase of treatment:
- B. **THREE (3) extra-oral Photos:** Should be 3 x 5 in size and arranged on a separate page. The background must be free of distractions and the patient must have their eyes open and looking straight ahead without glasses. Photos should be taken with the patient standing, with a neutral & clean background, and technically correct. The photographs are: 1) Frontal view non-smiling lips at repose, 2) Frontal view smiling, 3) Right profile view of face lips in repose. All facial photos should include the shoulders in the pictures.
- C. **SIX (6) intra-oral photographs:** all photographs should be taken at a 90-degree angle to the plane and all teeth in mouth should be seen in the photos except for the overjet/overbite photo. Photos should be taken with retractors and mirrors as necessary, lit appropriately, and technically correct. The following are required views in **centric occlusion**: frontal, left and right lateral and overjet/overbite and maxillary and mandibular occlusal views. Lateral intra-oral photographs should be full retracted and show all molars!
- D. All cases are required to have a complete set of pre-treatment, post-treatment, and two-year (or greater) post-treatment photos as applicable. **Caseworx users additionally have an optional panel, “Mid-treatment”, as well as the ability to attach an unlimited number of images to “Other Imaging” as support for the case. TMD or apnea cases can use “Other Imaging” section to include supporting information, such as sleep study results or biometrical results (EMG, EGN, and sonography).**
- E. Caseworx users have photo grids in the case generator form that indicate which images should be placed in specific locations. Users also have available built-in editing tools to crop, rotate, and perform minor adjustments to their images.

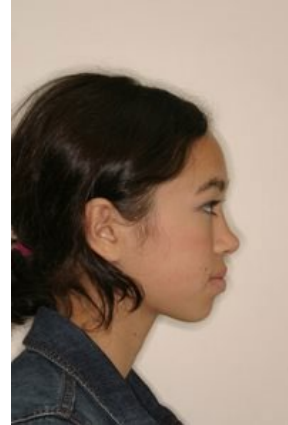**IBO PHOTOGRAPHIC STANDARDS**



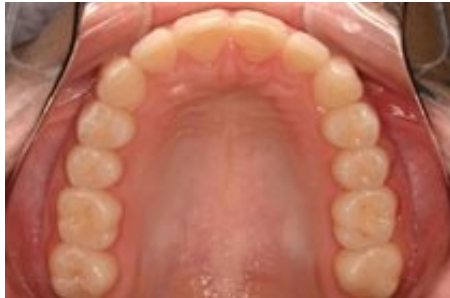**Frontal view lips reposed**



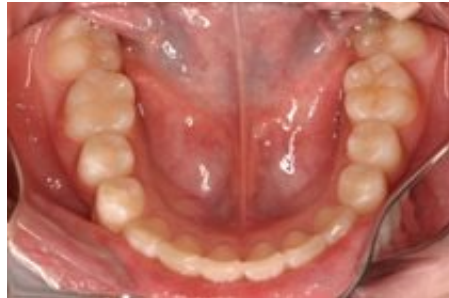**Profile view lips reposed**



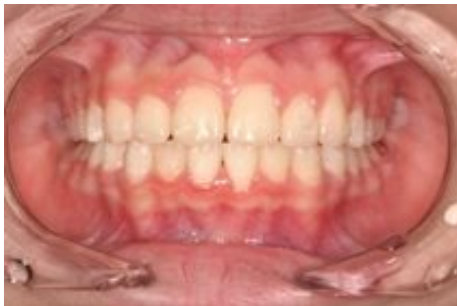**Frontal view posed smile**



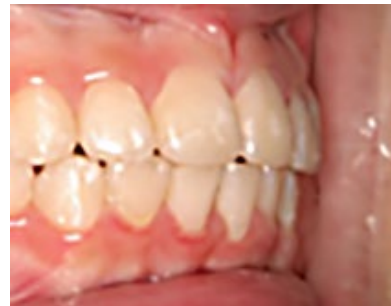**Maxillary arch (Retracted occlusal mirror view)**



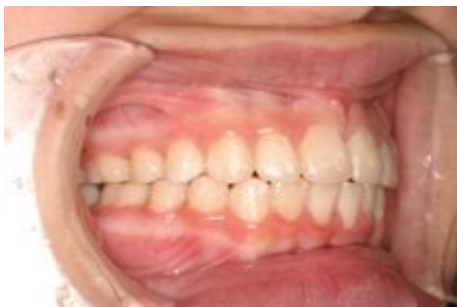**Mandibular arch (Retracted occlusal mirror view)**



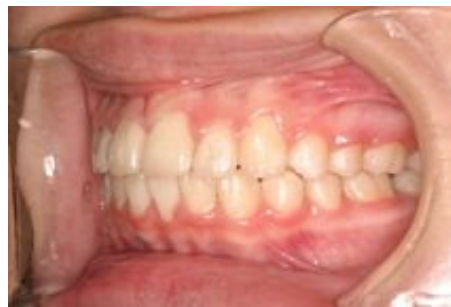**Retracted frontal view (centric occlusion)**



**Retracted lateral view (overbite/overjet)**



**Retracted right lateral view (centric occlusion)**



**Retracted left lateral view (centric occlusion)**

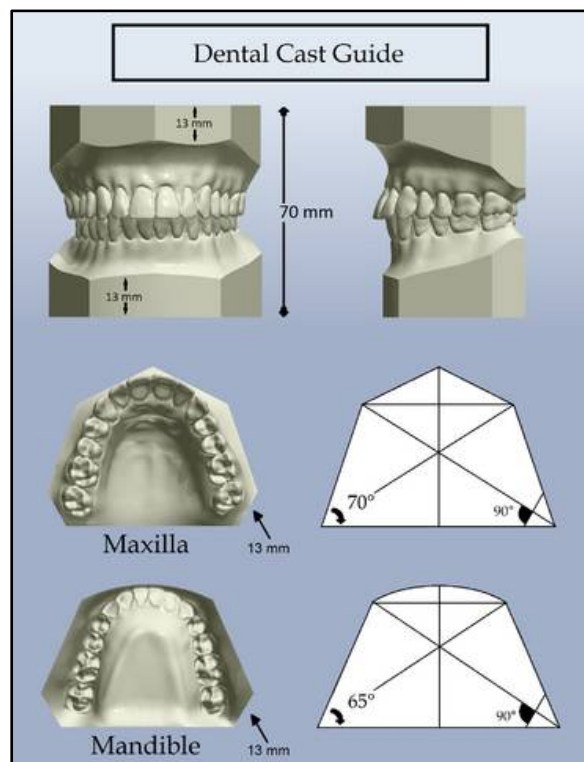
## SECTION VI: STUDY MODELS

All cases are required to have pre-treatment, post-treatment and when necessary, 2 or more years post active treatment, “soaped” study models. They should be clearly marked with date records taken, patient’s IBO ID number and Doctor’s IBO ID number. **Be sure that patient anonymity is retained by obscuring any patient marking on the models themselves.** This can be easily done by covering up any markings before photographing with a cut piece of Post-It Note. Be sure the cover doesn’t obscure any of the important details of the model itself!

The IBO Standards are as follows:

Orthodontically trimmed and finished art models in white stone including the hard and soft tissues. The dental anatomy should be clear well defined as well as the impression of soft tissue to the muco-buccal fold.

### IBO Standards for Study Models



(Courtesy of Dynaflex Labs)

In Caseworkx, each section provides an unlimited box to insert scans or photographs. As each image is imported, the user will provide a title to the image. In the case of study models, be sure to place the images in the appropriate progress section (Pre-tx, post-tx, etc.) and label each item with the facet (frontal, lateral left/right, maxilla, mandible, posterior, 90deg overjet/overbite, and curve of spee left/right).

## SECTION VII: ANALYSIS OF CEPHALOMETRIC RADIOGRAPHS AND DIAGNOSIS

- A. Cephalometric Radiographs should be hand-traced (digital is accepted, though at least one hand-traced preferred).
- B. The **IBO standard tracing** is required. The tracing must contain the **cephalometric measurements listed below**.
- C. Additional tracings may be included to support your case. These additional tracings may be included with the IBO format tracings or in the “Other Imaging” section of Caseworx. If additional tracings are included, be sure to title the tracing accordingly, including the tracing format and position (overlay, superimposition). The IBO format tracing **MUST** always be the first tracings in the list! Be sure to indicate in your narrative any additional supportive tracings (i.e., “See Steiner tracing, in Appendix”).

### D. CEPHALOMETRIC SUPERIMPOSITION

Radiographic results: All cephalometrics tracings need to have a **Superimposition of pre-treatment with post treatment (and with two years+ post treatment, if applicable) in the appropriate layer color**. Discuss the findings as they apply to the finished case.

The tracings should be aligned by Sella-Nasion at Sella as your superimposition point.

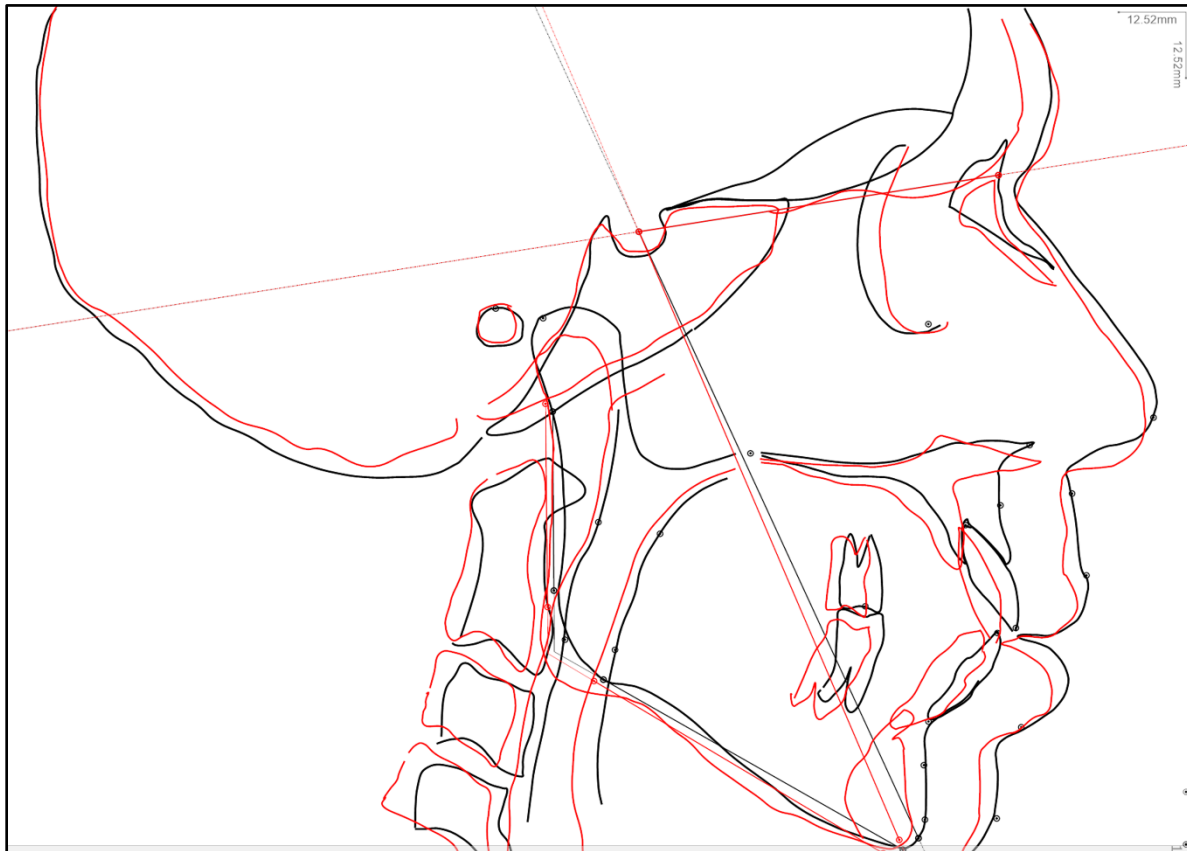
**The examiners will be looking for your comments drawn from the superimpositions, such as orthopedic changes to the position of the maxilla or mandible, positional changes to the molars, changes in upper or lower incisor angulations, and finally soft-tissue profile changes. The changes noted should also be related to your cephalometric analysis results.**

Caseworx users will import a scan or photo of the tracings into the “Imaging – Tracings” section of Ceph Analysis. During import, users will be asked to title the image. Be sure to indicate the appropriate title of the tracing. Be sure to use a “Full” tracing that includes the hard and soft tissue outlines so that growth can be visualized.

**SUPERIMPOSITIONS**

**OVERLAY COLOR KEY:** Black- Pre-treatment, Red- Post-treatment, Green – 2-yrs+ post-treatment.

**Superimposition Example - (Sella-Nasion at Sella)**

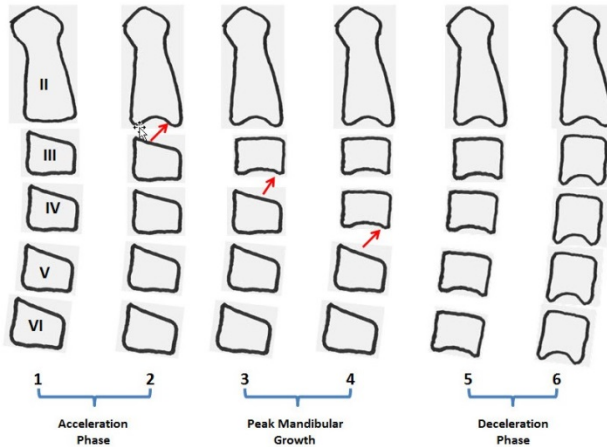


**IBO CEPH SHEET DATA VALUES**

**Section 7.1 - Analysis of Growth:**

**a. Stage of growth - CVMS Method**

**Developmental Stages of Growth**



**SIX STAGES OF MATURATION**  
(From Franchi et al [11]):

**Stage 1.** The inferior borders of the bodies of all cervical vertebrae are flat. The superior borders are tapered from posterior to anterior.

**Stage 2.** A concavity develops in the inferior border of the second vertebra. The anterior vertical height of the bodies increases.

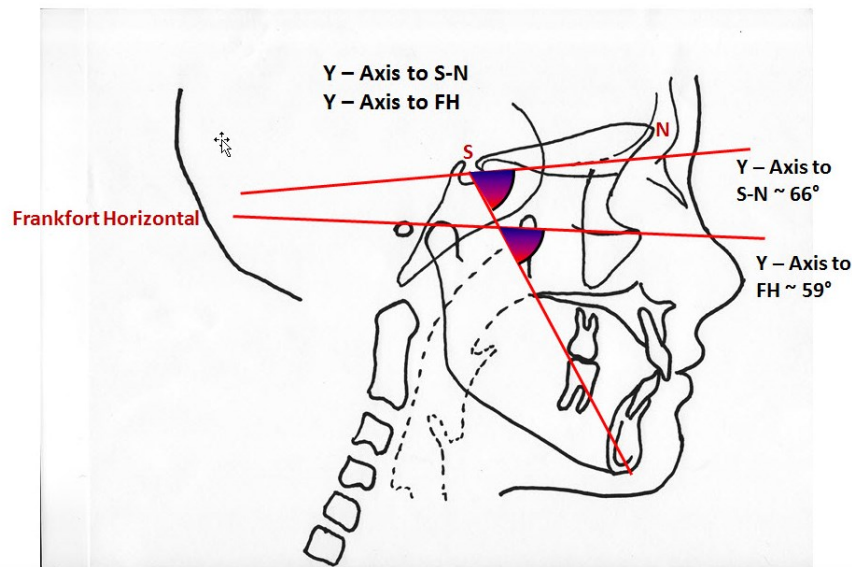
**Stage 3.** A concavity develops in the inferior border of the third vertebra.

**Stage 4.** A concavity develops in the inferior border of the fourth vertebra. Concavities in the lower borders of the fifth and sixth vertebrae are beginning to form. The bodies of all cervical vertebrae are rectangular in shape.

**Stage 5.** Concavities are well defined in the lower borders of the bodies of all 6 cervical vertebrae. The bodies are nearly square in shape and the spaces between the bodies are reduced.

**Stage 6.** All concavities have deepened. The vertebral bodies are now higher than they are wide.

**b. Direction of growth –Y-axis to SN and Y-axis to FH**

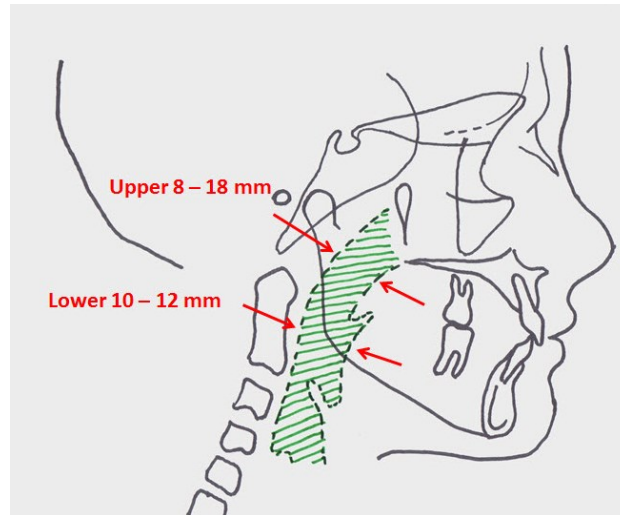


Y-axis to SN and Y-axis to FH

A Y-axis to SN greater than 66 indicates a vertical growth direction, likewise a Y-axis to FH greater than 59. The opposite, less than 66 and less than 59 would indicate a horizontal tendency.

**Section 7.2 - Analysis of the airway:**

- a. Upper Airway: Naso-pharyngeal
- b. Lower Airway: Oro-pharyngeal



**8-18 mm**      **Upper Airway** (Measured just distal and inferior to the Maxillary second molar area)

Norm 8-18mm: If the measurement is between these numbers, with 8mm being a child and 18mm being an adult, then the patient should have adequate airways.

Application: If smaller than 8mm then there may be constriction of the upper airway. If larger than 18mm then the patient should have an open upper airway.

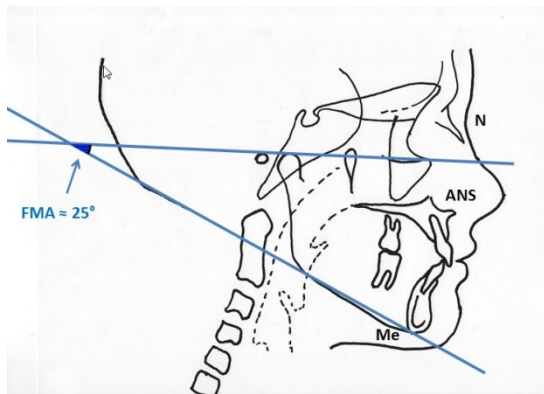
**10-12mm**      **Lower Airway** (Measured at the Gonial Angle area)

Norm 10-12mm: If the measurement is between these numbers, with 10mm being a child and 12mm being an adult, then the patient should have adequate airways.

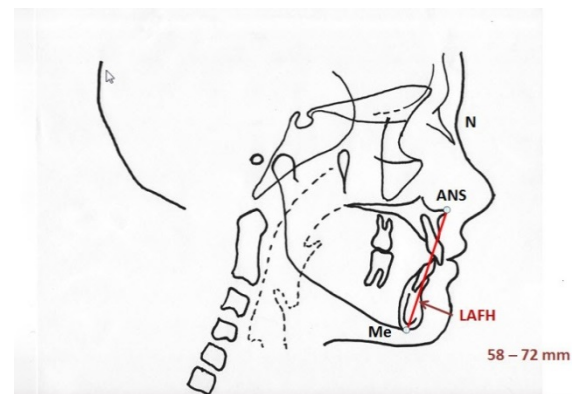
Application: If the measurement is smaller than 10mm then the patient may have a lower airway constriction. If larger than 12mm then the patient should have an open lower airway.

### Section 7.3 - Analysis of the skeletal Vertical Dimension:

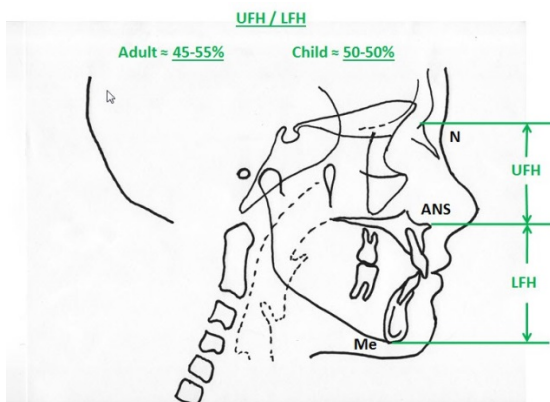
- FMA (Mandibular Plane to Frankfort Horizontal)
- LAFH (Lower Anterior Facial Height) (mm)
- UAFH- LAFH/TAFH (% ratio)
- SN- GoGn (Steiner)



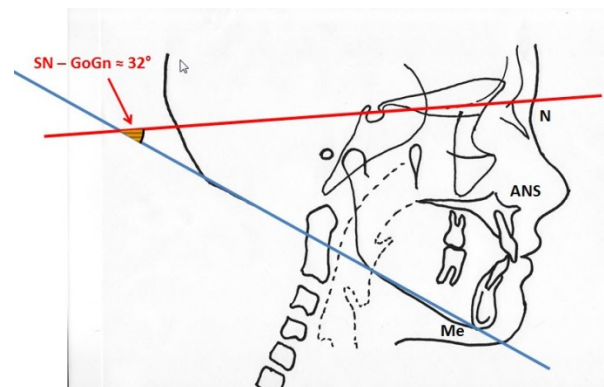
FMA



LAFH



UAFH/TAFH x 100, LAFH/TAFH x 100



Mandibular Plane to SN

**FMA - Norm =  $25^{\circ} \pm 4^{\circ}$** , Frankfort Mandibular Angle, or angle of the mandibular plane to Frankfort Horizontal Plane). FMA indicates both the steepness of the mandibular angle and the assessment of vertical skeletal development.

**Application:** Used to determine the degree of vertical growth occurring in the



mandible. In a case with an FMA beyond 25 the growth is seen as more vertical, and the "skeletal bite" is said to be more "open" than the norm. If FMA is less than 25, then the patient is more horizontal and the case is categorized as more "closed" than the norm.

**LAFH - Norm = 58-72mm**, measure the length of the line from ANS (Anterior Nasal Spine to Me (Menton). This tells if the lower anterior face height is normal for that patient. Problem with this norm: it has not been correlated with the age of the patient.

Application: A patient with less than 58mm of lower anterior face height may be associated with a closed vertical dimension. A patient with more than 72mm of lower face height may be associated with an open vertical dimension. Note that this measurement does not take age into consideration, something we do need to consider.

**UAFH/LAFH % - Norm = 50/50% for children. 45/55% for adults. The comparison of Upper Face to Lower Face height in percentage.** (The measurements are taken as follows: UF = Nasion (N) to Anterior Nasal Spine (ANS) in mm. LF = Anterior Nasal Spine (ANS) to Menton (Me) in mm.)

**SN-GoMe - Norm =  $32^{\circ} \pm 3^{\circ}$ .** Angle of the Sella-Nasion plane to the Gonion-Menton plane. Measures a normal growth angle of the Mandible.

Application: When the angle is greater than  $35^{\circ}$  the Mandible is growing more vertical than the norm. If less than  $29^{\circ}$  then the mandible is growing more horizontal than the norm.

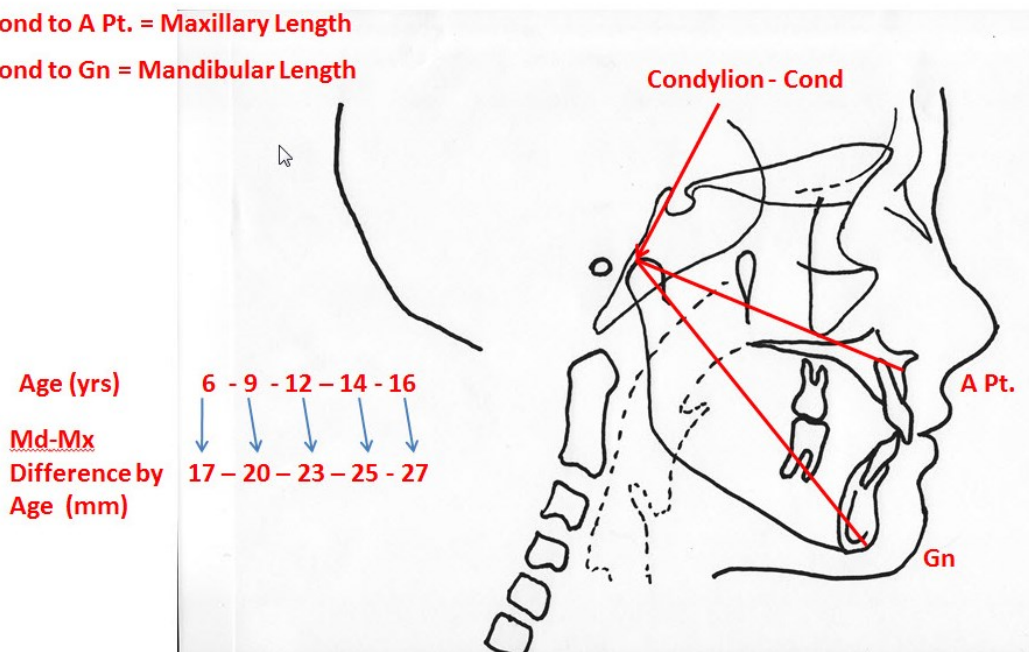
### Section 7.4 - Analysis of the Skeletal Horizontal/Sagittal Dimension:

**A/B/C. Modified Harvold Analysis:** (Length of Mandible **minus** length of Maxilla: analyze the **difference** of these measurements (**this measurement is age dependent**).

- A. Condylion to A (Maxillary length)
- B. Condylion to Gn (Mandibular length)
- C. MnL – MxL difference

Cond to A Pt. = Maxillary Length

Cond to Gn = Mandibular Length



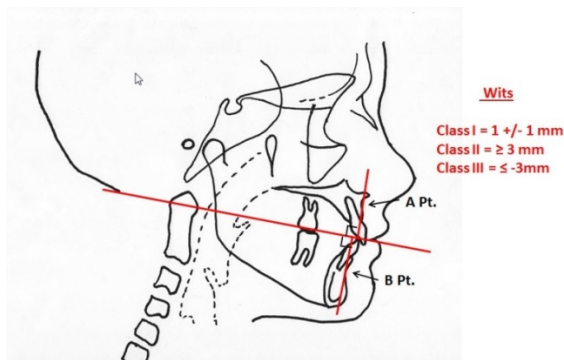
Differences by Age 6=17mm; Age 9= 20mm; Age 12= 23mm; Age14=25mm; Age16= 27mm

**Modified Harvold Analysis: Length of the Mandible Compared to the Maxilla by Age, i.e. 17mm @ age 6. Length of the Mandible compared to the length of the Maxilla by age of patient (measure the length of the Mandible from Condylion-B-Point and the length of the Maxilla from Condylion to A-Point.)**

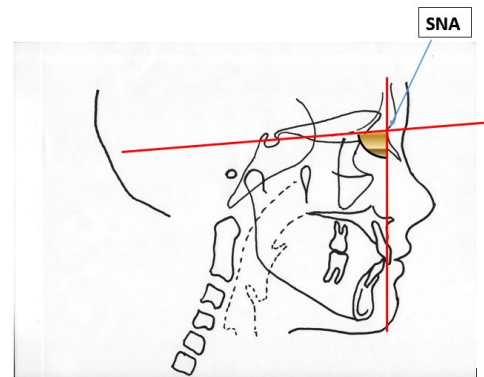
Norm based on age from 6-16: At age 6 the difference of the length of the Mandible minus the length of the Maxilla should be 17mm. At age 9\20mm at age 12\23mm at age 14\25mm and at age 16\27mm.

**Application:** For a patient age 6; if greater than 17mm the Mandible is either too long or Class III tendency or the Maxilla is too small and a retrusive upper arch. If less than 17mm then the Mandible is too short for the Maxilla or Class II tendency or the Maxilla is too big and you have a prognathic upper arch. *The spreadsheet calculates the norms for each age and tells you if the Mandible is too long or too short for each age.*

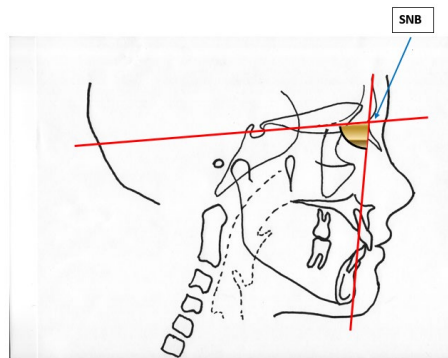
#### D. Wits (mm):



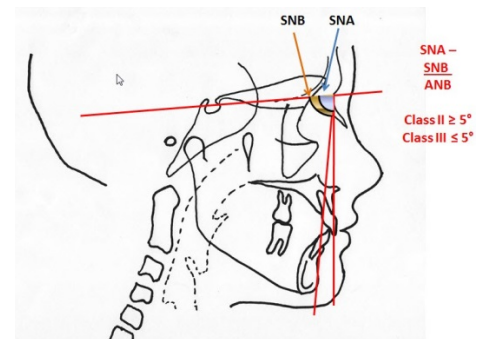
#### E. SNA (degrees)



#### F. SNB (degrees):



#### G. ANB (degrees)



#### Wits

Jacobson, in 1976, proposed his "Wits" appraisal (named after his Witwatersrand University in South Africa). In taking this single measurement, Point A and Point B would each be projected onto occlusal plane at  $90^\circ$ , and a dot would be made. The distance between the dots would represent the anterior-posterior disharmony of the

jaws.

**Wits: Class I Skeletal Norm = -1 to +3 mm.** When comparing the position of A Point on Occlusal Plane to B Point on Occlusal Plane.

**Application:** If the Wits value increases so that the maxillary dot moves forward of the mandibular dot, this indicates the Class II skeletal relation is increasing. As soon as the Wits reads minus 2 or more mm, the probability of Class III skeletal relation increases. In this analysis the Wits reading will override the ANB evaluation in most cases. Therefore, if ANB reads +4 mm (moderate Class II skeletal relation), while the Wits reads 0 mm (norm Class I skeletal relation), the Wits appraisal will be used to describe the patient's skeletal relation

### **SNA**

Sella to Nasion (S-N) defines the anterior cranial base and is a plane of reference for cephalometrics.

**SNA - Class I Skeletal Norm = 79-85°.** A measurement greater than 85° indicates a protrusive relation of the maxilla to the cranial base. Measurements less than 79° indicate retrusive relation of the maxilla to the cranial base

### **SNB**

Sella to Nasion (S-N) defines the anterior cranial base and is a plane of reference for cephalometrics.

**SNB - Class I Skeletal Norm = 77-83°.** A measurement greater than 83° indicates a protrusive relation of the mandible to the cranial base. Measurements less than 77° indicate retrusive relation of the mandible to the cranial base

### **ANB**

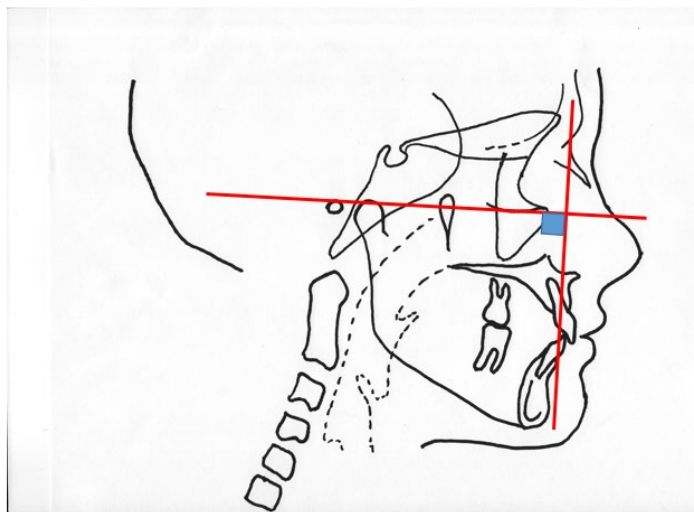
The ANB angle is the most commonly used measurement in diagnosing the disharmony of the maxillary and mandibular jaws in the A-P plane. Steiner made it one of the basic evaluations of his analysis. However, there are problems with the use of ANB. Two common ones are: 1) if the length of anterior cranial base S-N is increased

so that nasion is positioned more anteriorly, this has the effect of moving the ANB reading from a plus to a minus value in some instances! And 2) forward positioning (bi-maxillary prognathism) of both jaws has the effect of **increasing** the value of ANB.

**ANB - Class I Skeletal Norm = 0-5°.** Indicates the relationship of the maxillary denture base to the mandibular denture base. A positive reading means the maxillary jaw is forward of the mandibular jaw. The easiest method of obtaining the value of ANB is to subtract SNB from SNA.

**Application:** As the value of ANB increases above 5°, the potential for a Class II skeletal relation increases. As the value falls below 0°, the potential for a Class III skeletal relation increases.

#### H. McNamara Nasion Perpendicular (Na Perp – A pt)



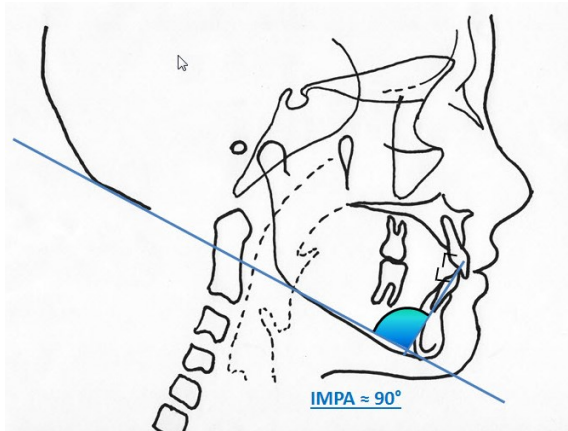
#### McNamara Nasion Perpendicular (Na Perp – A pt)

From Frankfort Horizontal, draw a perpendicular line through Nasion and then measure A pt relative to that line.

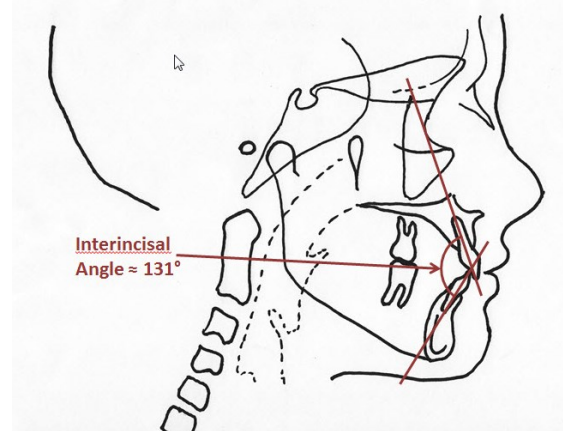
**Na Perp – A - Class I Skeletal Norm = -1 to 3mm**

### Section 7.5 - Analysis of the Dento-Alveolar Relations:

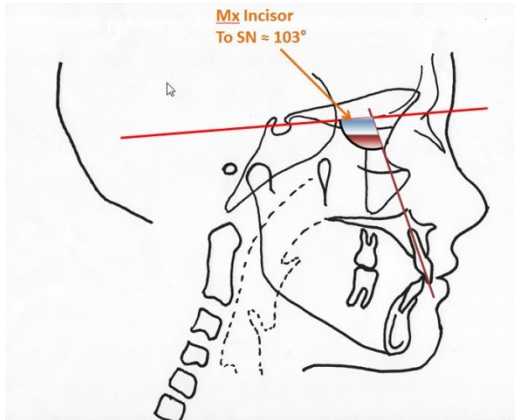
- A. IMPA
- B. Interincisal Angle
- C. Mx incisor to SN
- D. Mn incisor to A-Pg



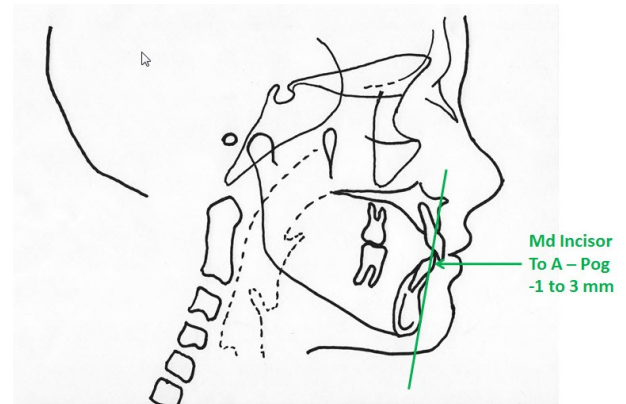
IMPA



Interincisal Angle



Upper incisor to SN



Lower incisor to A-Pg

**IMPA - Norm =  $90 \pm 5^\circ$ .** Incisor Mandibular Plane Angle, or axis of Mn1 in relation to Mandibular Plane). This is the first angle of the Tweed Diagnostic Facial Triangle.

**Application:** As Mandibular incisor is inclined labially beyond the norm, arch length is increased, but the incisors tend to incline forward beyond their alveolar support base, and beyond the stability point, as defined by the AP line. As the mandibular

incisor is inclined lingually below the norm, the incisors are seen to crowd themselves and the canines.

**Interincisial Angle (Mxl/Mnl) – Norm =  $131^{\circ} \pm 4^{\circ}$ .** The Interincisal Angle measures the long axis of the most labially inclined upper central incisor to the most labially inclined lower central incisor. Measure the angle of the long axis of the Maxillary Central to the Mandibular Central Incisor.

**Application:** The larger the angle, the less protrusive and the more vertical the teeth are in relation to each other.

**Mx incisor-SN - Norm =  $103^{\circ} \pm 2^{\circ}$ .** (Measures the angle of the long axis of the Maxillary Central Incisor to the SN plane). Establishes the inclination of the axis of Mx1 compared to SN plane. In effect it measures how the upper central incisor is inclined labially.

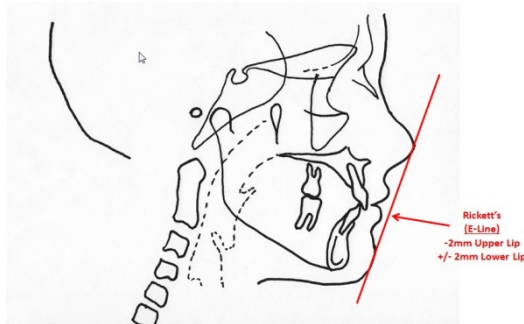
**Application:** As the angle increases Mx 1 is flared to the labial, giving the maxilla a prognathic look to it. As the angle decreases a Division 2 central incisor relationship develops.

**Mn Incisor (Lower 1) to A-Pg Line Norm: -1 to 3mm.** The position of the facial tip of MnL in relation to the Point A-Pogonion line. Indicates that the best soft tissue matrix support (lower lip) against MnL occurs when the facial surface of MnL is positioned exactly on the A-P line, called the Raleigh Williams Diagnostic Line.

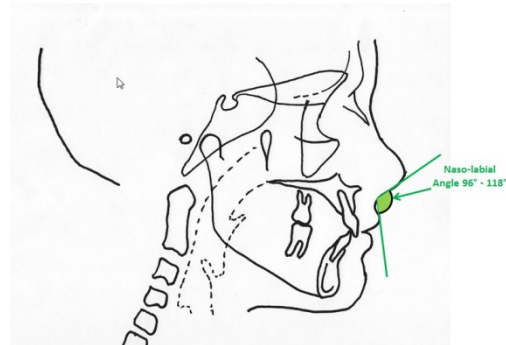
**Application:** If MnL is **buccal** of AP line, relapse of the incisors is likely to occur to the lingual. If MnL is located **lingual** to the AP line, the incisors tend not to be stable and will lapse forward. This is an important measurement when stability of lower incisors following bicuspid extractions is being considered.

## Section 7.6 - Analysis of the Soft Tissues

- A. Li-Esthetic Line (Rickett's): Line to lower lip (mm) from E-Plane
- B. Naso-labial angle: 96-118 degrees
- C. Lip competence: yes or no



Lower Lip to Esthetic Line



Nasolabial Angle

**Lower Lip to Rickett's Esthetic Line ("Li to E-line"):** Norm  $-2\text{mm} \pm 2\text{mm}$ : (Mandibular lip in relation to E-Plane) On the head film find the most anterior surface of the **mandibular** lip (labial inferior or Li) and measure it to the esthetic plane. Hopefully, the lips on the head film are at rest. Normally this is with the lips together. If patient is a mouth breather lips may be apart and that is the position you measure. Value is a negative number if behind the Pn-Pg' line (E-line).

**Application:** The outline of each lip position is measured to a line drawn from the tip of the nose (pronasale or Pn) to the soft tissue pogonion (Pg') on the chin, which is the E-plane. Norm lips should "kiss" this plane at rest. The same relation may be diagnosed at the chair by using a length of unwaxed dental floss held against the tip of the nose and against the soft tissue forward point of the chin (pogonion). In extraction cases it is common for the lips to lose one to three millimeters of bony and incisor support during treatment. This causes the "dished in" look seen in some extraction cases at the termination of treatment.

**Nasolabial Angle:** Norm  $96^{\circ}$  to  $118^{\circ}$ . (Measure the inside angle made by lines from Soft Tissue Point A to tip of nose and tip of Maxillary lip.) Angle is measured from the buccal part of the intersection of the two lines.

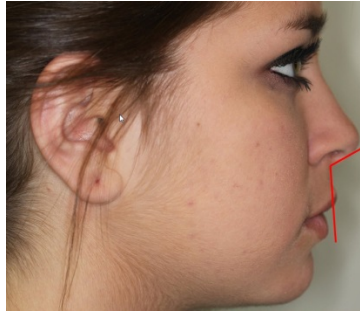**Application:** As the angle gets larger the Maxillary lip flattens out and might be retrusive. As the angle gets smaller the Maxillary lip is more protruded and the Maxillary teeth might



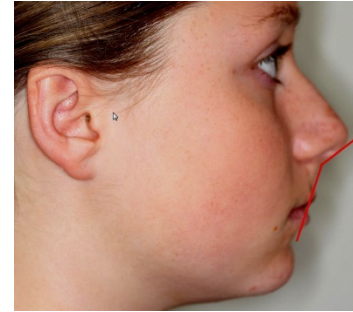be flared out to the buccal.



Acute Nasolabial angle




Normal Nasolabial angle




Obtuse Nasolabial angle

**Lip Seal: Yes or No - Norm = Yes for Competent lips or No for incompetent lips. (Does the patient have competent or incompetent lips?)**

**Application:** Two factors are evaluated when diagnosing the relation of the patient's lips. Whether the lips are competent or incompetent; in other words, are they touching and sealed at rest following a swallowing act (competent)? Or are they apart habitually (incompetent)? The more the competency of the lips increases, the better they will act as an effective soft tissue matrix to maintain the anterior tooth relations attained by orthodontic treatment. It is best to think of lip competency ranging from severe compression of the lips to open, flaccid, parted lips as seen at rest. Additionally, you may see in those patients without lip seal, a tight mentalis or strain in this area, which may "hide" photographically a case of lip incompetence; this is just one reason to try to capture this pre-treatment condition in your profile photo by asking the patient to "relax" their lips.



No lip seal



Lip seal



### IBO Cephalometric Data Sheet

	Norm	Pre-Tx	Post-Tx	Post +2 Yr												
<b>1. Analysis of Growth</b>																
A. Stage of Growth (CVMS)	I – VI	_____	_____	_____												
B. Direction of Growth																
Y-Axis to SN	66° ± 3°	_____	_____	_____												
Y-Axis to FH	59° ± 2°	_____	_____	_____												
<b>2. Analysis of Airway</b>																
A. Upper Airway (Nasopharynx)	8-18mm	_____	_____	_____												
B. Lower Airway (Oropharynx)	10-12mm	_____	_____	_____												
<b>3. Analysis of Skeletal Vertical</b>																
A. FMA	25° ± 4°	_____	_____	_____												
B. LAFH (ANS to Mn), mm	58-72mm	_____	_____	_____												
C. UAFH-LAFH / TAFH Ratio, percent	45-55% Adult 50-50% Child	_____	_____	_____												
D. SN to GoMe (Steiner)	32° ± 3°	_____	_____	_____												
<b>4. Analysis of Skeletal Sagittal</b>																
A. Co-A (Mx Len), mm	<table border="1"><thead><tr><th>Age</th><th>Mm</th></tr></thead><tbody><tr><td>6</td><td>17</td></tr><tr><td>9</td><td>20</td></tr><tr><td>12</td><td>23</td></tr><tr><td>14</td><td>25</td></tr><tr><td>16</td><td>27</td></tr></tbody></table>	Age	Mm	6	17	9	20	12	23	14	25	16	27	_____	_____	_____
Age	Mm															
6	17															
9	20															
12	23															
14	25															
16	27															
B. Co-Gn (Mn Len), mm		_____	_____	_____												
C. Difference (Mn – Mx Len), mm		_____	_____	_____												
D. Wits (Jacobson), mm	<table border="1"><thead><tr><th>Class</th><th>Mm</th></tr></thead><tbody><tr><td>I</td><td>-2 to 2</td></tr><tr><td>II</td><td>&gt;= 3</td></tr><tr><td>III</td><td>&lt;= -3</td></tr></tbody></table>	Class	Mm	I	-2 to 2	II	>= 3	III	<= -3	_____	_____	_____				
Class	Mm															
I	-2 to 2															
II	>= 3															
III	<= -3															
E. SNA, deg	82° ± 3°	_____	_____	_____												
F. SNB, deg	80° ± 3°	_____	_____	_____												
G. ANB, deg	<table border="1"><thead><tr><th>Class</th><th>Deg</th></tr></thead><tbody><tr><td>I</td><td>0-4°</td></tr><tr><td>II</td><td>&gt;= 5°</td></tr><tr><td>III</td><td>&lt;= 0°</td></tr></tbody></table>	Class	Deg	I	0-4°	II	>= 5°	III	<= 0°	_____	_____	_____				
Class	Deg															
I	0-4°															
II	>= 5°															
III	<= 0°															
H. Na I - A pt	1mm ± 2mm	_____	_____	_____												
<b>5. Analysis of Dento-Alveolar Relations</b>																
A. IMPA (Incisor Mn Plane Angle), deg	90° ± 5°	_____	_____	_____												
B. Interincisal Angle ( $\overline{1} - \overline{1}$ ), deg	131° ± 4°	_____	_____	_____												
C. Mx Incisor ( $\overline{1}$ ) – SN, deg	103° ± 2°	_____	_____	_____												
D. Mn Incisor ( $\overline{1}$ ) to A-Pg, mm	-1 to 3mm	_____	_____	_____												
<b>6. Analysis of Soft Tissue</b>																
A. Lower Lip (Li) - Esthetic Line (Rickett's), mm	-2mm ± 2mm	_____	_____	_____												
B. Naso-labial Angle, deg	107° ± 11°	_____	_____	_____												
C. Lip Seal	Yes	Yes/ No	Yes/ No	Yes/ No												

## SECTION VIII: CASE DIAGNOSIS / TREATMENT OBJECTIVES, PLANNING , MODALITIES

Items in this section require a narrative to be written by the candidate. Be as clear and detailed as possible with answers. Include transverse, vertical, and horizontal considerations in your answers.

**A. Case Diagnosis:** This section should include a **complete** diagnosis (skeletal and dental): Include clinical findings, functional evaluation, entire IBO cephalometric summary, full mouth series or panoramic radiographs, model analysis and anything pertinent in the medical and dental histories. When referring to a specific tooth that tooth must be identified using the #1 to #32 numbering system.

Be sure to provide actual measurements, details, and analysis of details in your narratives. Remember that the examiner was not present for the examination, diagnosis, and treatment of the patient! Be sure to provide the examiner with a complete picture of the case.

Scoring of the case diagnosis results in 10 points, with each of the following representing one point. The examiner will award points based on the effectiveness that the candidate addresses the following:

1. Growth stage and direction
2. Functional
3. Airways
4. Facial Analysis
5. Vertical
6. Sagittal
7. Transverse
8. Dental
9. Soft tissue
10. TMJ

Casework users have individual sections to address diagnosis of the case. Be sure to address the items above within the sections available.

**B. Treatment planning:** Provide a detailed account of the objectives, plan, and modalities utilized in treating the patient. Include detailed measurements, values, and items such as retainer types, wire sizing, and times.

Be sure that the mechano-therapy narrative provides a detailed month-by-month treatment process with analysis and results of each step.

The case will be scored on the following items, each worth 2 points:

**A. Outline treatment objectives:**

**B. Treatment Plan:**

**C. Limitations, complications and prognosis:**

**D. Explain mechano-therapy:**

**E. Evaluate treatment progress:**

Casework users have individual sections to address treatment planning/progress of the case. Be sure to address the items above within the sections available.

## SECTION IX: CASE FINISHING AND TREATMENT RESULTS

Evaluate the final results of the case and answer the following:

Write a brief narrative on each lettered section below for the case you are presenting.

- A. Plane of Occlusion
- B. Marginal Ridges
- C. Soft Tissue (Intraoral)
- D. Retention
- E. Overjet / Overbite
- F. Cuspid / Molar relation
- G. 7's in Occlusion / Facial-Dental Midlines
- H. Rotations
- I. Spaces
- J. Root Parallelism
- K. Cosmetic Finishing and Detailing
- L. Long-term Stability

Casework users have individual sections to address finishing and results of the case. Be sure to address the items above within the sections available.

## SECTION X: DISCUSSION OF THE CASE

The discussion of the progress of the case from initial treatment to the end of active treatment. This discussion should include: Facial Esthetics, lips, skeletal relationship, length of treatment, difficulty of case, problems incurred, evaluation of objectives achieved, planning for post-active treatment retention, and patient's reaction to final results.

### Further Study

Appendix B of this Candidate Handbook contains an actual graded IBO Diplomate Examination Case Presentation to illustrate the information presented above. **When reviewing the sample case, it is important to remember that is not "perfect" and is not intended to be.**

*Page intentionally left blank / Spacer*



# IBO Policies

## IBO POLICIES

### IBO CONFIDENTIALITY POLICY

#### CANDIDATE IDENTITY

IAO publishes the list of IAO Diplomate members in the annual Membership Directory and on the IAO “Member's Only” website.

#### TEST SCORES

The IAO maintains candidate and Diplomate confidentiality with regards to test scores and other data. Scoring of the written examination results in a pass/fail decision and individual numerical scores are not recorded. Individual pass/fail results will only be released if prior written consent is obtained from the candidate or Diplomate.

#### TEST DATA ANALYSIS AND SHARING

In keeping with best practices of certification, the IAO may publish aggregate statistics on testing data without sharing the identity of individual test takers. These statistics may include, but may not be limited to, pass/fail data.

### IBO DISCIPLINARY POLICY

The International Board of Orthodontics (IBO) adheres to the *ADA Principles of Ethics and Code of Professional Conduct (ADA Code)*. All IBO Officers, IBO Members, Diplomates and Diplomate Candidates are expected to comply with the *ADA Code*.

#### PUBLICATION OF THE IBO DISCIPLINARY POLICY

The most current version of the *ADA Code* will be distributed to IBO Officers and IBO Members on an annual basis to maintain familiarity with the requirements of the *ADA Code*. This policy will be published with Diplomate candidate preparatory materials to promote compliance by candidates and Diplomates.

Should any Officer, Member, Diplomate or Diplomate Candidate be suspected of violating the *ADA Code*, the following procedures will be put into place.

#### Disciplinary Procedures

##### DISCIPLINARY PROCEDURE FOR DIPLOMATE CANDIDATES

1. Should an IBO Diplomate candidate be suspected of violating the *ADA Code* by an IBO Officer, IBO Member, Diplomate, or Diplomate Candidate or another party, the first course of action is to inform the IBO President directly of these suspicions. Any supporting evidence or documentation should be presented at the time the suspected violation is disclosed. IBO President shall serve the roll of primary investigator into any suspected violations of the *ADA Code*.
2. The IBO President will confidentially evaluate the merits of any evidence or documentation of suspected violation, and perform any necessary additional investigation into the suspected violation to determine if



the allegations are compelling enough to be brought to the IBO to vote on the need for disciplinary action. The IBO President will inform the IAO President at the beginning of the investigation and will continue to keep the IAO President informed of as the investigation progresses. The purpose of involving the IAO President is to help ensure an unbiased assessment of the claims of any suspected violation.

3. In the course of the investigation, should the IBO President determine the suspected violation to be unsubstantiated, no further action will be taken. Should the IBO President find the evidence of a violation to be compelling, he or she shall inform the suspected candidate of the allegations and the candidate shall have the opportunity to explain the circumstances regarding the violation.
4. Following discussion with the candidate, the IBO President shall convene a meeting or teleconference of the Board to discuss the violation. The IAO Executive Director shall participate in the meeting or teleconference in an advisory role. The IBO President shall present to the Board the nature of the violation, the sequence of events that lead to the investigation of the violation, and the response by the candidate. The Board shall vote to determine if the violation should require disciplinary action by the Board.
5. Until the IBO has voted, the name of the candidate shall be kept confidential, known only to the IBO President. Should IBO determine that disciplinary action is required, the President shall disclose the identity of the candidate. The name of the person that initially brought forward his or her suspicions of violation shall remain confidential throughout the proceedings, known only to the IBO President, and shall not be disclosed at any time.
6. Should the IBO determine that no disciplinary action is required, the candidate will be informed of the decision and no further action will be taken.
7. Should the IBO determine disciplinary action is required, the candidate's application for Diplomate shall be terminated and the candidate shall be prevented from reapplying for a period of three (3) years. After the probationary period ends, the candidate may reapply for Diplomate, but must present all new cases to satisfy the Clinical Examination requirements. The candidate shall be notified in writing.
8. The candidate may appeal a decision of disciplinary action as per the IBO Appeals Policy.

---

#### *DISCIPLINARY PROCEDURE FOR DIPLOMATES*

1. Should an IBO Diplomate be suspected of violating the *ADA Code*, the same procedure for investigation and evaluation shall be employed as with the *Disciplinary Procedure for Diplomate Candidates*. As with the procedure for Diplomate Candidates, the IBO President shall serve as primary investigator and the suspected Diplomate shall be given the opportunity to explain the circumstances of the suspected violation.
2. Should the IBO determine disciplinary action is required, and this is the Diplomate's first offense, IBO Diplomate status shall be rescinded for a probationary period of one (1) to three (3) years as determined by the IBO, based on the severity of the offense. During the probationary period, the Diplomate will not

be listed as an IBO Diplomat in IBO or IAO publications, the Diplomat will not be permitted to refer to his- or herself either verbally or in writing as an IBO Diplomat. After a period of three years, the Diplomat may apply to reinstate their status by submitting a written report of steps taken to rectify the violation. Reinstated Diplomats shall also be asked to sign a formal acknowledgement that should a second violation be discovered; Diplomat status shall be rescinded permanently.

3. Should the IBO Diplomat also be a currently serving IBO Officer or Member, and the IBO President determines that review by the IBO is necessary, the IBO will be informed of the identity of the Diplomat prior to evaluation of the suspected violation. The Diplomat shall recuse themselves from his or her participation on the IBO until a decision has been made. Should the IBO determine that disciplinary action is required, the Diplomat's term of office shall be terminated and the Diplomat will no longer be eligible for re-election.
4. Should the IBO Diplomat be the currently serving IBO President, the IBO Vice President shall assume the role of primary investigator.
5. The Diplomat may appeal a decision of disciplinary action as per the IBO Appeals Policy.
6. Disciplinary policies related to failure to perform IBO duties, are described in *IBO Standing Rules, Appendix A: Mechanism of Nomination, Election, & Replacement of an IBO Examiner*.

## IBO APPEALS POLICY

An IBO Officer, Member, Diplomat or Diplomat Candidate may seek to appeal an IBO determination for disciplinary action.

### *Procedure for Appeals*

1. An IBO Officer, Member, Diplomat or Diplomat Candidate may seek to appeal an IBO determination for disciplinary action by submitting a written letter of appeal to the IAO Executive Director. The letter should include a summary of the circumstances surrounding a violation of the *ADA Code* and an explanation of why the applicant feels the IBO determination for disciplinary action is not justified. The written notification of disciplinary action issued by the IBO should also be included with the applicant's letter of appeal.
2. Upon receipt of the letter of appeal, the IAO Executive Director shall notify the IAO President and the IBO President. The IAO President shall then convene an Appellate Committee comprised of five members including the IAO President, as chair, the IAO Education Committee Chair, one (1) IBO Member or IBO Officer, and two (2) IAO Education Committee members to be selected by the IAO President. The IAO Executive Director shall participate in the Appellate Committee in an advisory role.
3. The IBO President shall prepare a written report for the Appellate Committee on the IBO determination for disciplinary action for their consideration.
4. The Appellate Committee shall review the IBO President's report and the appellate applicant's letter to make a final determination on the need for disciplinary action. Should the Appellate Committee uphold

the decision of the IBO, disciplinary action shall be enforced as outlined in the original decision of the IBO. There is no mechanism for further appeals.

5. Should a currently serving IBO Officer or Member be the appeals applicant, he or she shall not be permitted to serve on the Appeals Committee.
6. Should the currently serving IBO President be the appeals applicant, the IBO Vice President will assume the IBO President's role in the *Procedure for Appeals*.

## IBO POLICY ON ETHICAL AND PROFESSIONAL CONDUCT

The International Board of Orthodontics (IBO) adheres to the *ADA Principles of Ethics and Code of Professional Conduct (ADA Code)*. The five fundamental principles of the ADA Code are\*:

1. Patient Autonomy: *the dentist has a duty to respect the patient's rights to self-determination and confidentiality*
2. Non-maleficence: *the dentist has a duty to refrain from harming the patient*
3. Beneficence: *the dentist has a duty to promote the patient's welfare*
4. Justice: *the dentist has a duty to treat people fairly*
5. Veracity: *the dentist has a duty to communicate truthfully*

\*These principles are excerpted from the ADA Code, pages 4-10.

IBO Officers, Members, Diplomates, and Diplomate Candidates are expected to accept these five principles as the foundation of their professional lives and their work within the IBO. They are also expected to comply with the requirements of the *ADA Code* in their IBO-related activities. Should an IBO Officer, Member, Diplomate, or Diplomate Candidate be suspected of violating the *ADA Code*, the *IBO Disciplinary Policy and Procedures* shall be employed.

## IBO DIPLOMATE RECERTIFICATION POLICY

### MAINTENANCE OF DIPLOMATE REQUIREMENTS

To enhance continued competence of Diplomates. Beginning January 1, 2015, all IBO Diplomates will be required submit to IAO Headquarters documentation of attendance of at least 40 hours of continuing education (CE) in orthodontics over a period of three years, in order to maintain their status as an IBO Diplomate. All CE hours submitted should be AGD PACE or ADA CERP approved.

### CE HOURS SUBMISSION PROCESS

IBO Diplomates should use the standard IAO Professional Advancement CE Hours submission process to submit their CE Hours to Headquarters. This may be done online in the Member's Only Section of the IAO website or documentation of hours may be faxed or emailed to headquarters, Attn: IAO Professional Advancement.

### CE Hours Review Cycle

1. Each review cycle shall span three (3) years.

2. The first cycle shall begin January 1, 2015 and end December 31, 2017.
3. All Diplomates shall be required to submit documentation of the minimum number of CE hours by December 31, 2018. Subsequent review cycles will follow the calendar year, with the required documentation due by December 31 of the third year of the cycle.
4. IAO Headquarters will review all Diplomate records for completion of this requirement and Diplomates will be notified of their status by February 15, following the end of the review cycle. Diplomates that have successfully complied with the recertification requirements shall be issued a new Diplomate Certificate.

---

#### **FAILURE TO COMPLY WITH THE IBO RECERTIFICATION POLICY**

Failure to submit documentation of the minimum requirement of CE hours within the stated three years shall result in Diplomate status being put on probation. Diplomates on probation shall have one (1) year to complete the missing CE hours. To be relieved of probation, Diplomates must submit missing CE hours with a formal application. Missing hours will not count toward the required hours of the new review cycle.

##### *Reapplication of an Invalidated Diplomate Status:*

A Diplomate on probation who has failed to fulfill the missing CE requirement in the one-year time limit shall have their Diplomate Status rescinded. The doctor will no longer be listed as an IBO Diplomate in IBO or IAO publications, and will not be permitted to refer to his- or herself either verbally or in writing as an IBO Diplomate. The doctor may apply to have Diplomate status reinstated by submitting an application for reinstatement including documentation of missing CE hours that would meet the delinquency requirement that would be necessary to comply with the 40 hours/3-year commitment, an explanation of delinquency, and a small reapplication fee. All documentation should be submitted to the IAO Central Office for review and approval by the IBO.

##### *Appeal of an Invalidated Diplomate Status:*

There are many extenuating circumstances that may prevent a Diplomate from complying with the 40-hour requirement. An active IAO Member may appeal an Invalid Diplomate Status by submitting formal application to the IAO Central Office for consideration. All Appeals shall be reviewed and ruled upon by the IBO.

## APPENDIX A: APPLICATION FORMS

The following pages contains form for the professional advancement candidate which may be printed, filled out, and returned to the IAO for processing.

- Standard application for professional advancement
- Specialist application for professional advancement
- Verification of Authenticity (Cases)



**International Association for Orthodontics**  
**Application for Professional Advancement**

**Diplomate**

*Photo Required*

**Please check the examination for which you are applying:**

\_\_\_\_\_ IBO Written Examination and IBO Clinical Case Examination (US \$700.00)

\_\_\_\_\_ IBO Written Examination ONLY (US \$100.00)

\_\_\_\_\_ IBO Clinical Case Examination ONLY (US \$600.00)\*

*\*Candidates must have passed the IBO Written Examination prior to taking the IBO Clinical Case Examination.*

IAO ID \_\_\_\_\_ Date Joined (MM/YYYY) \_\_\_\_\_

**Candidate Demographic Information**

Name \_\_\_\_\_

Address \_\_\_\_\_

City \_\_\_\_\_ State \_\_\_\_\_ Zip/Postal Code \_\_\_\_\_

Country \_\_\_\_\_ Phone \_\_\_\_\_ Fax \_\_\_\_\_

Email \_\_\_\_\_

Date of Birth (optional) \_\_\_\_\_ Citizenship (optional) \_\_\_\_\_

**Candidate Practice Information**

Please Check \_\_\_\_\_ General Dentist \_\_\_\_\_ Pediatric Dentist \_\_\_\_\_ Ortho Limited

Please Check \_\_\_\_\_ Private Practice \_\_\_\_\_ # of Years in Private Practice

\_\_\_\_\_ Solo \_\_\_\_\_ # of Years, Solo

**Educational History**

Undergraduate University: \_\_\_\_\_ Degree \_\_\_\_\_ Date Awarded (MM/YYYY) \_\_\_\_\_

Dental School: \_\_\_\_\_ Degree \_\_\_\_\_ Date Awarded (MM/YYYY) \_\_\_\_\_

Postgraduate School: \_\_\_\_\_ Degree \_\_\_\_\_ Date Awarded (MM/YYYY) \_\_\_\_\_

**Professional Affiliation**

University (Faculty) Affiliations: \_\_\_\_\_

Professional Memberships: \_\_\_\_\_

Honors, Awards: \_\_\_\_\_

Published Articles: \_\_\_\_\_

Community Activities: \_\_\_\_\_

**Payment Information**

Please check payment type:

MASTERCARD    VISA    AMEX    DISCOVER    US MONEY ORDER / US CHECK

Card Number \_\_\_\_\_ Expiration Date (mm/yyyy) \_\_\_\_\_

Security/CVV Code \_\_\_\_\_

Signature \_\_\_\_\_ Today's Date \_\_\_\_\_

**Please return this form, with your payment to:**  
International Association for Orthodontics  
3610 N Oakland Ave., Ste #1n | Shorewood, WI 53211 USA  
E-mail: [worldheadquarters@iaortho.org](mailto:worldheadquarters@iaortho.org)  
+1 414/272-2757 | Fax: +1 414/272-2754



**International Association for Orthodontics  
Specialist Application for Professional Advancement – Diplomate**

*\*Photo & Official written documentation of Board Certification is required*

*\*(This information may be attached.)*

First Name: \_\_\_\_\_ Last Name: \_\_\_\_\_ Title: \_\_\_\_\_

Address: \_\_\_\_\_

City: \_\_\_\_\_ State: \_\_\_\_\_ Zip/Postal Code: \_\_\_\_\_

Country: \_\_\_\_\_ Phone: \_\_\_\_\_ Fax: \_\_\_\_\_

E-Mail: \_\_\_\_\_ IAO ID #: \_\_\_\_\_ Year you joined IAO: \_\_\_\_\_

Please check: Ortho Limited Practice \_\_\_ Private Practice \_\_\_ (# years \_\_\_) Solo \_\_\_ (# years \_\_\_)

Today's Date: \_\_\_\_\_ Date of Birth: \_\_\_\_\_ Citizenship: \_\_\_\_\_

\*I am Board Certified in good standing with my national Orthodontist Association\*: Yes \_\_\_ No \_\_\_

*(Official written documentation of Board Certification is required.)*

Undergraduate University / Degree / Date Awarded: \_\_\_\_\_

Dental School / Degree / Date Awarded: \_\_\_\_\_

Postgraduate School / Degree / Date Awarded: \_\_\_\_\_

University (Faculty) Affiliations: \_\_\_\_\_

Professional Memberships: \_\_\_\_\_

Honors, Awards: \_\_\_\_\_

Published Articles: \_\_\_\_\_

Community Activities: \_\_\_\_\_

Total Amount Due: **USD \$500.00** (please check payment type)

MASTERCARD     VISA     AMEX     DISCOVER     US MONEY ORDER / US CHECK

Card Number \_\_\_\_\_ Expiration Date (mo/yr) \_\_\_\_\_

Security/CVV Code \_\_\_\_\_

Signature \_\_\_\_\_ Today's Date \_\_\_\_\_

**Please return this form, with your payment to:**

International Association for Orthodontics  
3610 N Oakland Ave., Ste #1n | Shorewood, WI 53211 USA

E-mail: [worldheadquarters@iaortho.org](mailto:worldheadquarters@iaortho.org)

+1 414/272-2757 | Fax: +1 414/272-2754





### Verification of Authenticity

To be completed and returned with the Diplomate Application.

Applicant Number Code Assignment: \_\_\_\_\_

There are: \_\_\_\_\_ of Class I treatments  
\_\_\_\_\_ of Class II treatments  
\_\_\_\_\_ of Class III treatments  
\_\_\_\_\_ Other---- Specify \_\_\_\_\_  
\_\_\_\_\_

There are: \_\_\_\_\_ 2-year post-treatments

I attest that the clinical cases hereby presented are the result of my own treatment. While I may have sought advice during the course of these treatments, the majority (90%), if not all the work was of my own.

Signature: \_\_\_\_\_

Signed this date: \_\_\_\_\_

**APPENDIX B: SAMPLE CASE**

**IBO CASE I.D. YJC-201503 (Sample Case)**  
**BIRTH DATE: April 25, 1996**  
**START DATE: December 13, 2007, AGE 11**

**THE FUNCTIONAL AND FIXED ORTHODONTIC TREATMENT OF THIS CLASS II DIVISION 2 SKELETAL CLASS II; SHORT VERTICAL; SEVERE MANDIBULAR RETROGNATHISM AND SHORT LOWER FACIAL HEIGHT SKELETAL DISCREPANCY CASE PATIENT IS PRESENTED IN PARTIAL FULLFILLMENT OF THE DIPLOMATE CLINICAL REQUIREMENTS OF THE INTERNATIONAL BOARD OF ORTHODONTICS**

**CASE TYPE: DIPLOMATE WITH POST-TX+2 YEAR DATA**  
**PATIENT ETHNICITY: ASIAN/CHINESE**  
**DOCTOR ID CODE: 1004M**

**TABLE OF CONTENTS**

Section I: Comprehensive Description of the Dentition, Chief Complaint and Patient Expectations.....	xxx
Section II: Pertinent Medical and Dental History .....	xxx
Section III: Cephalometric Radiographs and Hand Tracings.....	xxx
Section IV: Panoramic, Full Mouth Series, Transcranial or Tomographic Radiographs .....	xxx
Section V: Patient Photographs .....	xxx
Section VI: Study Models .....	xxx
Section VII: Analysis of Cephalometric Radiographs .....	xxx
Section VIII: Case Diagnosis, Treatment Planning, and Treatment Modalities .....	xxx
Section IX: Case Finishing and Treatment Results .....	xxx
Section X: Discussion of the Case .....	xxx
<b>Appendix A:</b> Additional Supporting Imaging .....	xxx

## Section I: Comprehensive Description of the Dentition, Chief Complaint, and Patient Expectations

### CLINICAL EVALUATION

#### Skeletal Evaluation

- Maxilla - Retrognathic, constricted Mx arch form
- Mandible - Retrognathic, constricted Md arch form
- Facial height - FMA is 20° and Sn-GoGn is 23°; Skeletally low angle; UFH/LFH is 43/57 indicate slightly long lower facial height; however, Jefferson ceph analysis and pretreatment facial profile photo shows her to have a short lower facial height. Treatment will be to correct short lower facial height. Facial asymmetry (skeletal midlines off 3 to 4mm to the right).
- Palate - Moderately deep palatal vault due to poor tongue swallow
- Genetic conditions - none noted
- Radiographic findings - Pre Treatment panorex shows no extraordinary findings. No caries and no restorations
- Chin - Significantly recessed chin. Needs forward movement and development
- Skeletal midlines - Mesocephalic asymmetric facial form. Lower mandible has a slight shift to the right
- Skeletal bite - Skeletally low angle case, FMA is 20° and Y-Axis to SN is 64°, describe as horizontal, low angle case type. Jefferson Ceph tracing shows lower facial height short by -7mm. Patient's lower facial height is very short (short face syndrome)

#### Dental Evaluation

- Dental classification - Class II molars, Class II cuspids, Class II anteriors both left and right side. No missing teeth, no decays, normal tooth size, 3mm curve of Spee left and right side. No spaces, upper incisors are flared according to upper incisor to SN is 115°; lower incisors are also slightly flared according to IMPA is 105° and Mn inc to A-Pog is 3mm
- Dental Midlines - Dental shift to the right by 4mm of the maxillary central midline
- Overbite/Overjet - Overbite 7mm, Overjet 10mm
- Open bite - Deep bite by 80 to 90%
- Closed bite - Bite closes properly
- Cross bite - No cross bite
- Model analysis - 3 mm Curve of Spee, left and right side. No tooth size discrepancy, no spacings, Mx minor to moderate crowded, Md moderate to severe crowded
- Arch shapes - Mx moderately narrow and constricted; Md moderate to severely narrow and constricted
- Arch length - Normal arch length
- Caries index - Low caries index, no restorations and no evidence of caries
- Radiographic findings - Pre-treatment Panorex shows no extraordinary finding.

#### Soft Tissue Evaluation

- Facial type - Mesocephalic
- Facial asymmetry - Facial asymmetry; Lower mandibular shift to the right
- Facial profile - Slightly convex profile
- Nose - Normal size
- Nasolabial angle - Acute (97°; norm is 103°)
- Lips - Normal upper and lower lips; lip competency and lip seal acceptable
- Smile line - Normal smile line
- Gingival display - Very slight but acceptable gingival display
- Tonsillar & adenoidal tissue - Clinically appeared normal
- Meniolabial sulcus - Within the norm
- Soft tissue chin - Moderately recessed/retrognathic
- Other - Lower facial height short; short face syndrome

#### Functional Evaluation

The patient's TMD evaluation and TM joint condition is as follows. Full range of motion, max opening 52mm, both lateral movements is 10mm. No deviation or deflection, no pain, clicking, or popping. Airway and tongue reveal Patient does not exhibit any airway obstructions or issues Low tongue position and poor myofunction as well as inadequate swallow attributed to maxillary and mandibular arch constriction. Muscle palpation revealed No palpable trigger points Pain scales and treatment progress reports indicate Patient does not report any pain at initial treatment

#### Special Considerations

Correction of severe 10mm overjet and severe short lower facial height will be challenging

#### Chief Complaint

Want jaw misalignment to be corrected

#### Secondary and Other Related Complaint(s)

n/a

#### Physical Examination

The patient exhibited nothing extraordinary during physical examination.

#### Clinical Observations and Vital Signs

within normal limits

#### Patient's Expectations

Want severe overjet and recessed chin corrected

#### Patient's Consent

The patient has provided consent and an Informed Consent form is on file to utilize the data in this presentation.

**Section II: Pertinent Medical and Dental History**

Medical History

No known medical problems

Accident/Causative History

Not related to a work or vehicular accident.

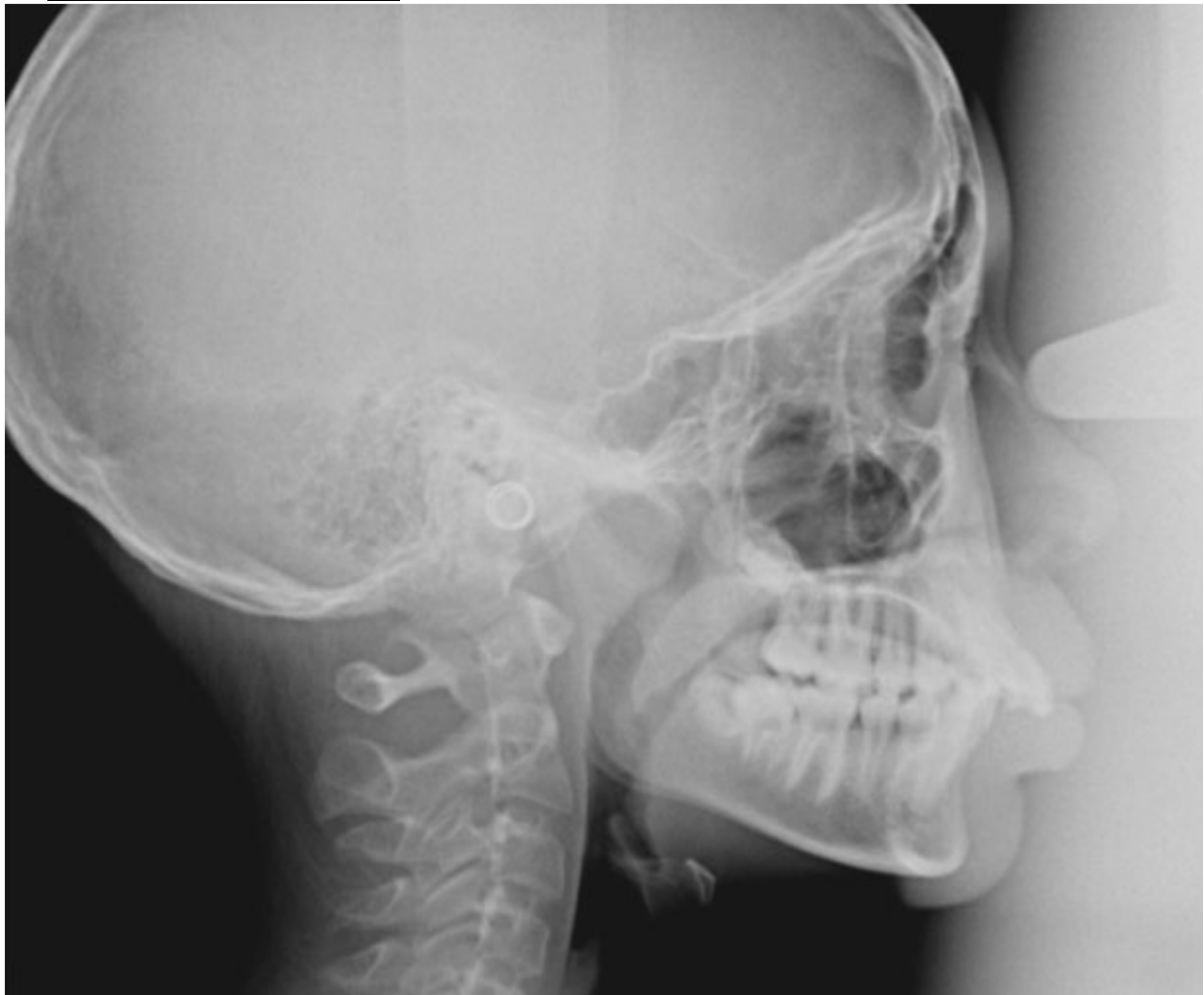Dental History

Regular visits to the dentist. No restorations, no caries, no periodontal concerns. Oral hygiene is excellent.

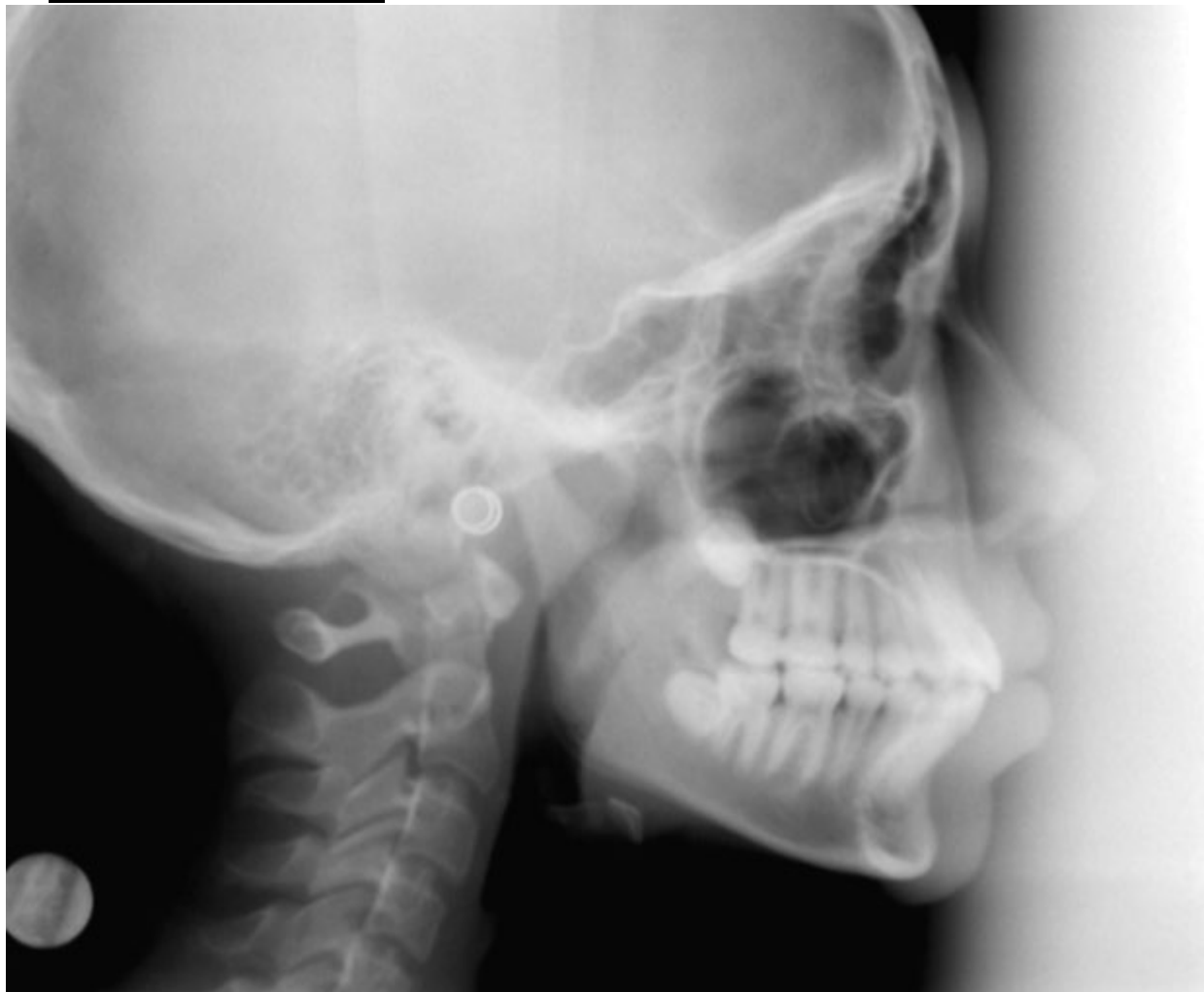**Section III: Cephalometric Radiographs, Tracings, and Superimpositions**

**Cephalometric Radiographs**

**Pre-Tx, 11y-6m, 10-25-2007**

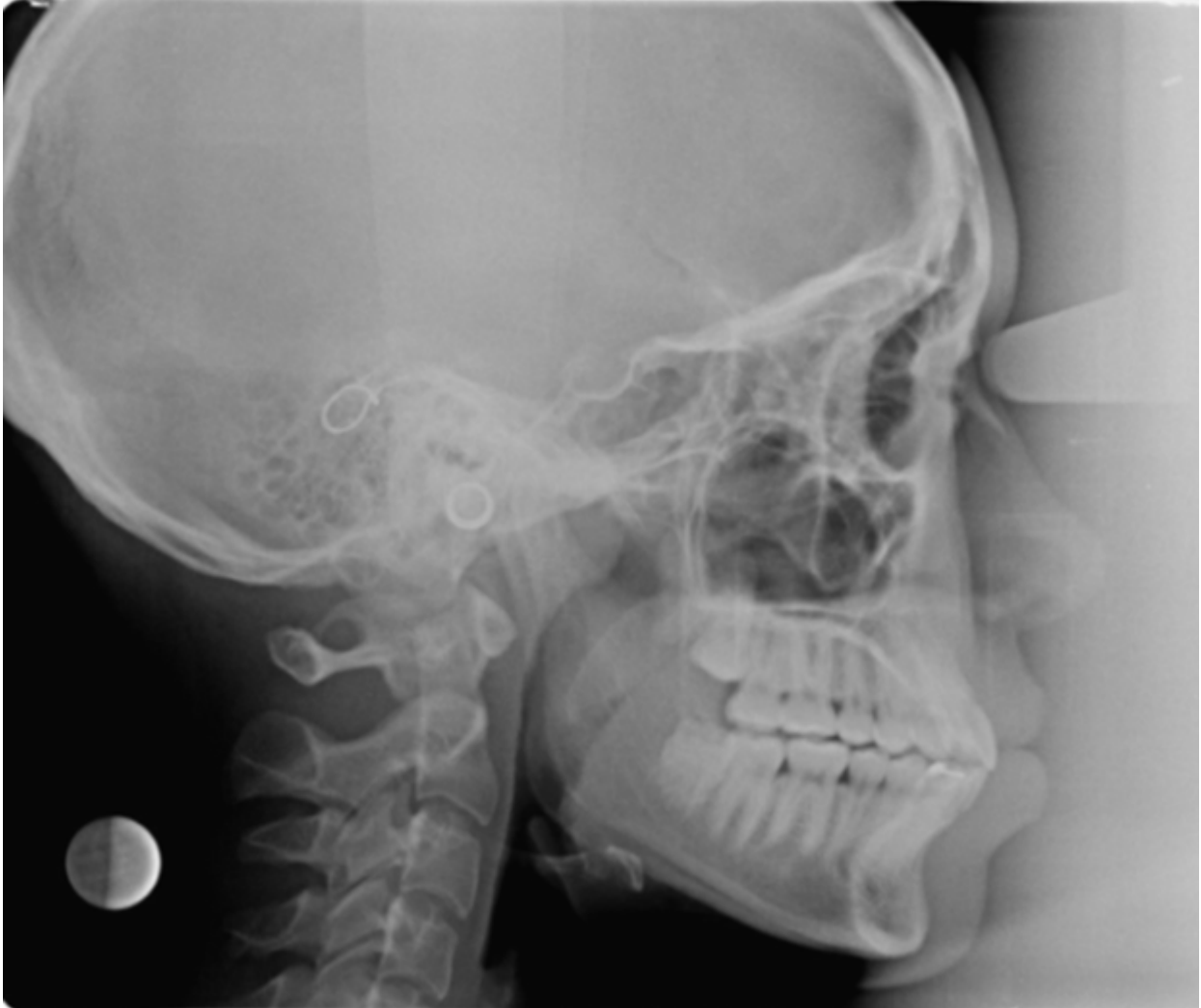

**Post-Tx, 13y-2m, 6-2-2009**



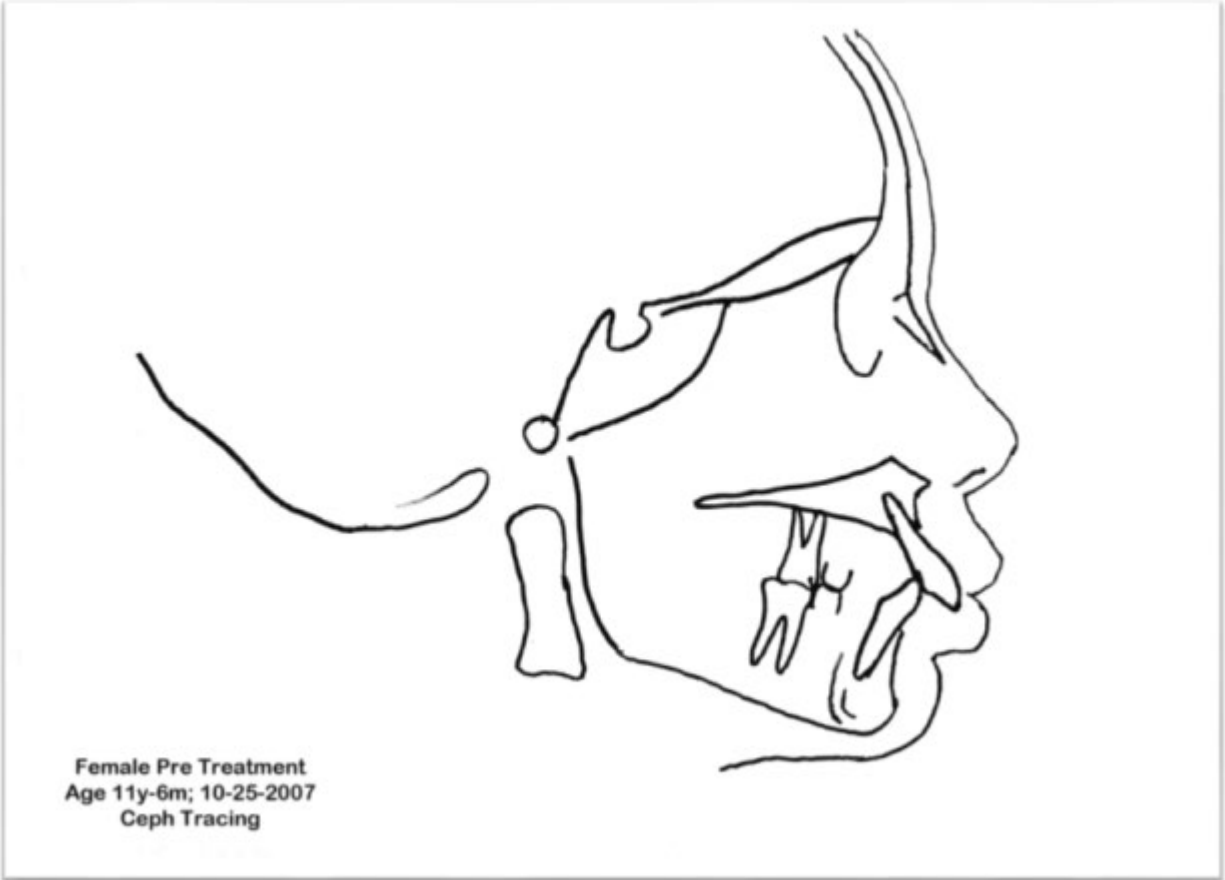


**4-yr-6-month Post-Tx, 17y-9m, 1-6-2014**

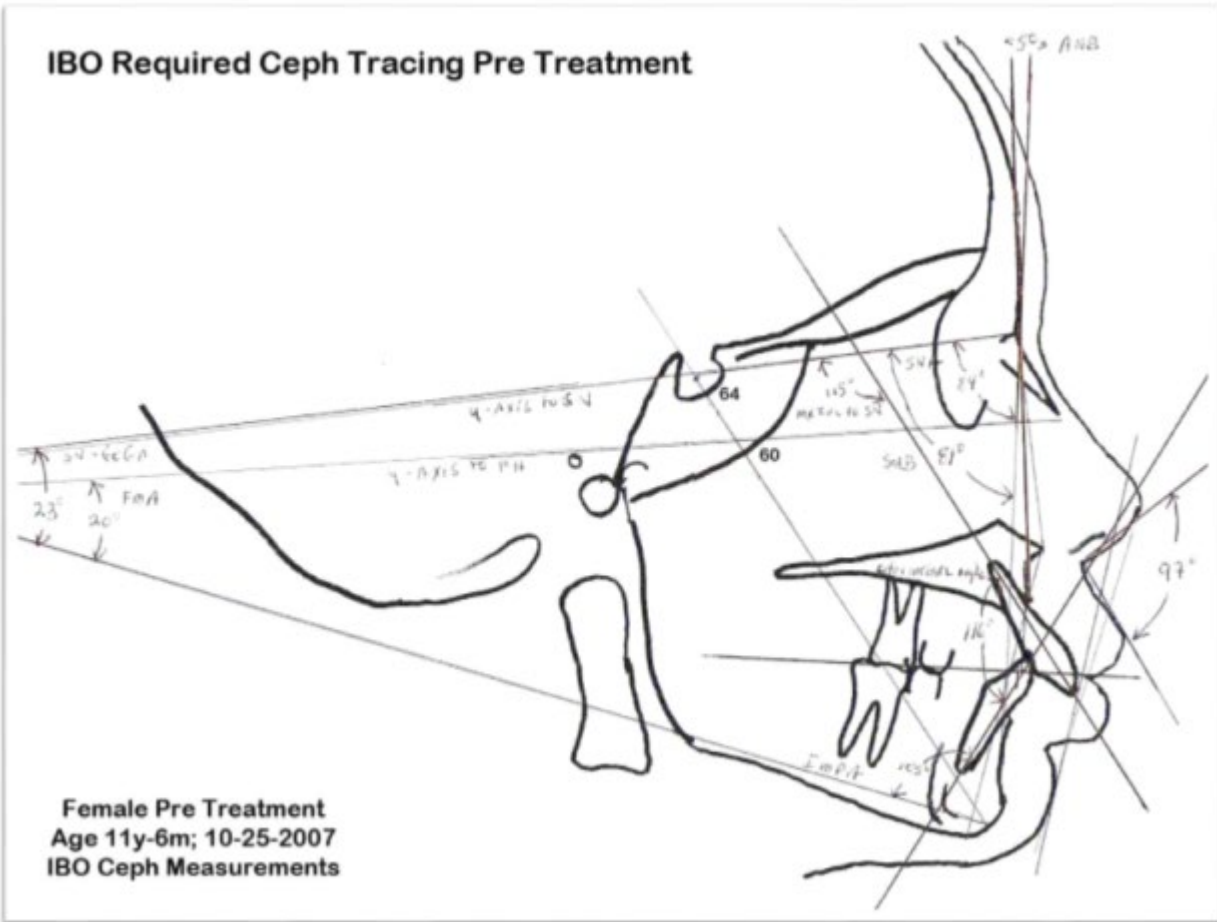


**Cephalometric Tracings**

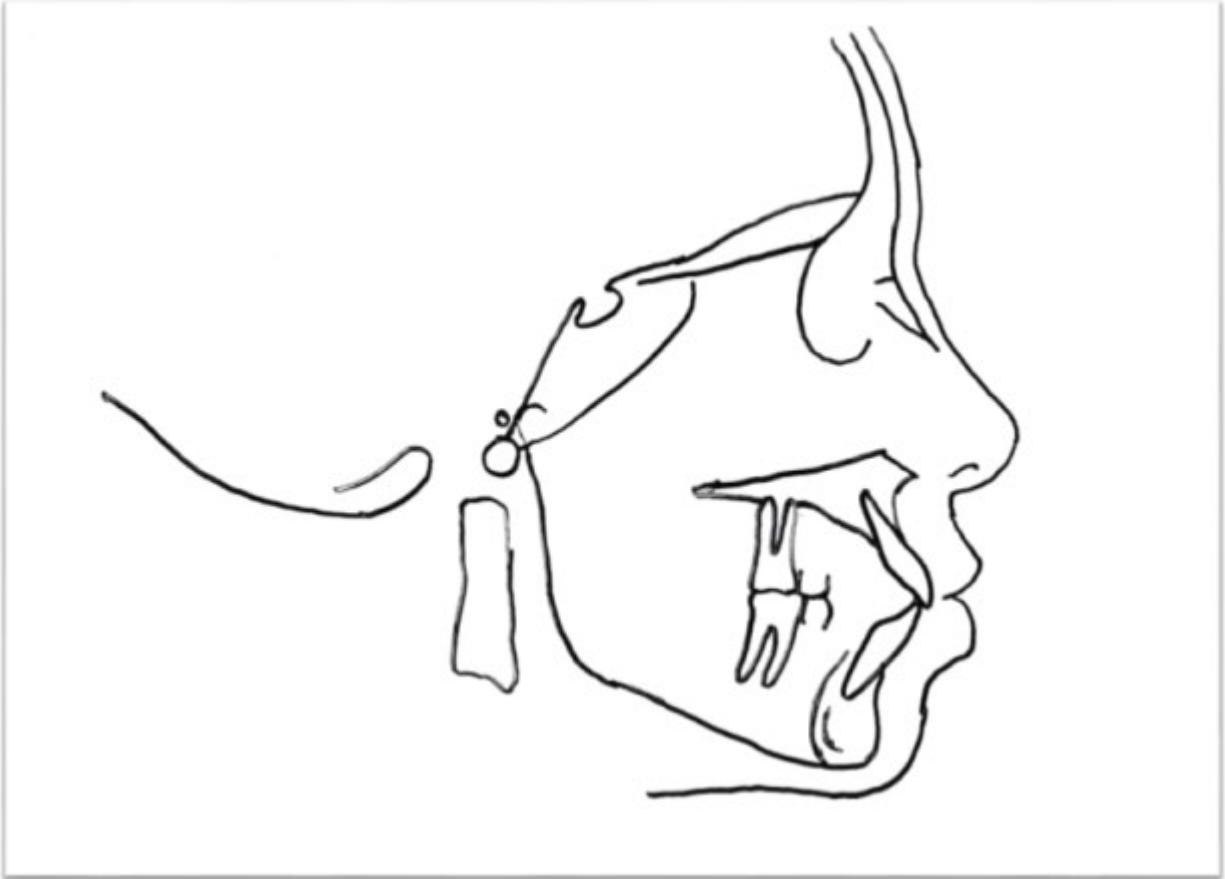
**Pre-Tx, IBO, No Measurements, 11y-6m, 10-25-2007**



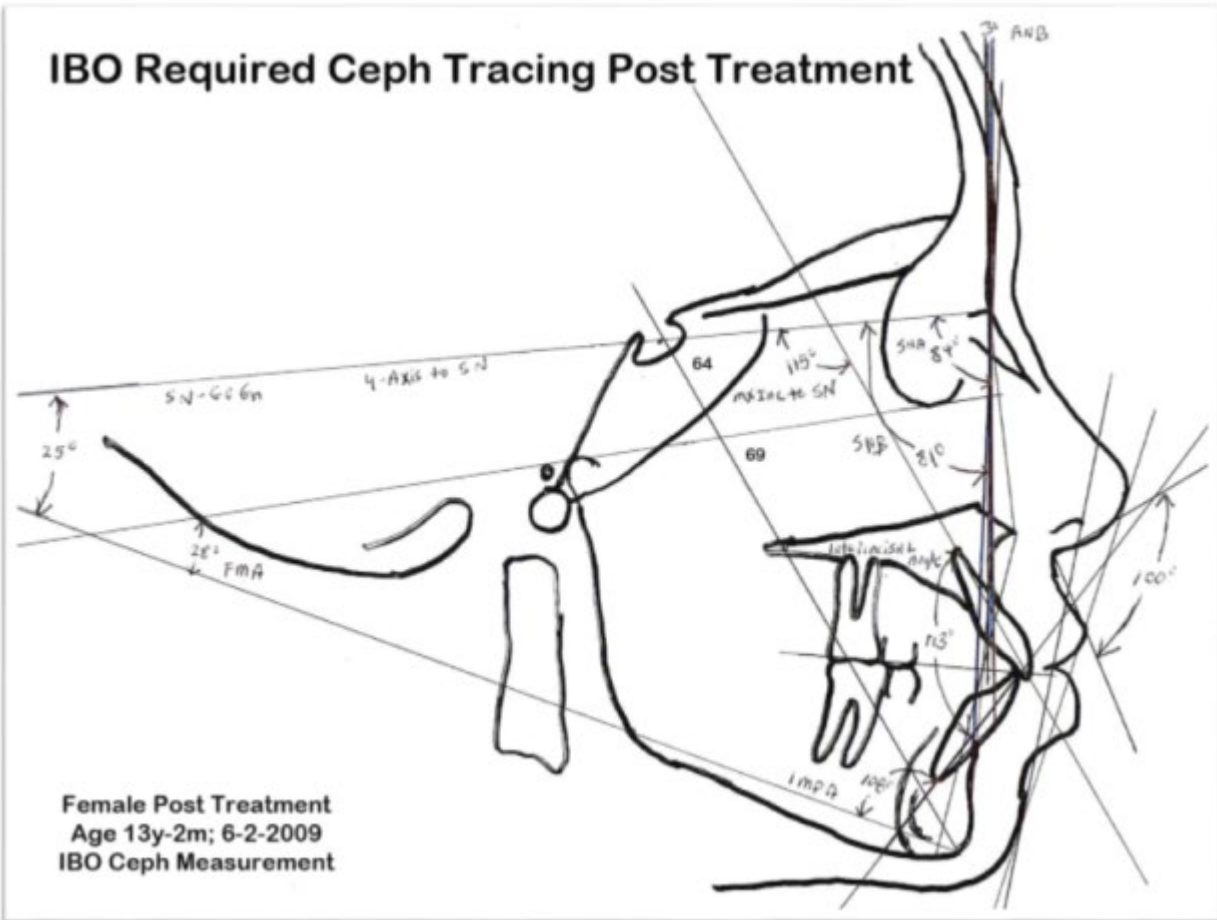
**Pre-Tx, IBO, 11y-6m, 10-25-2007**



**Post-Tx, IBO, No Measurements, 13y-2m, 6-2-2009**



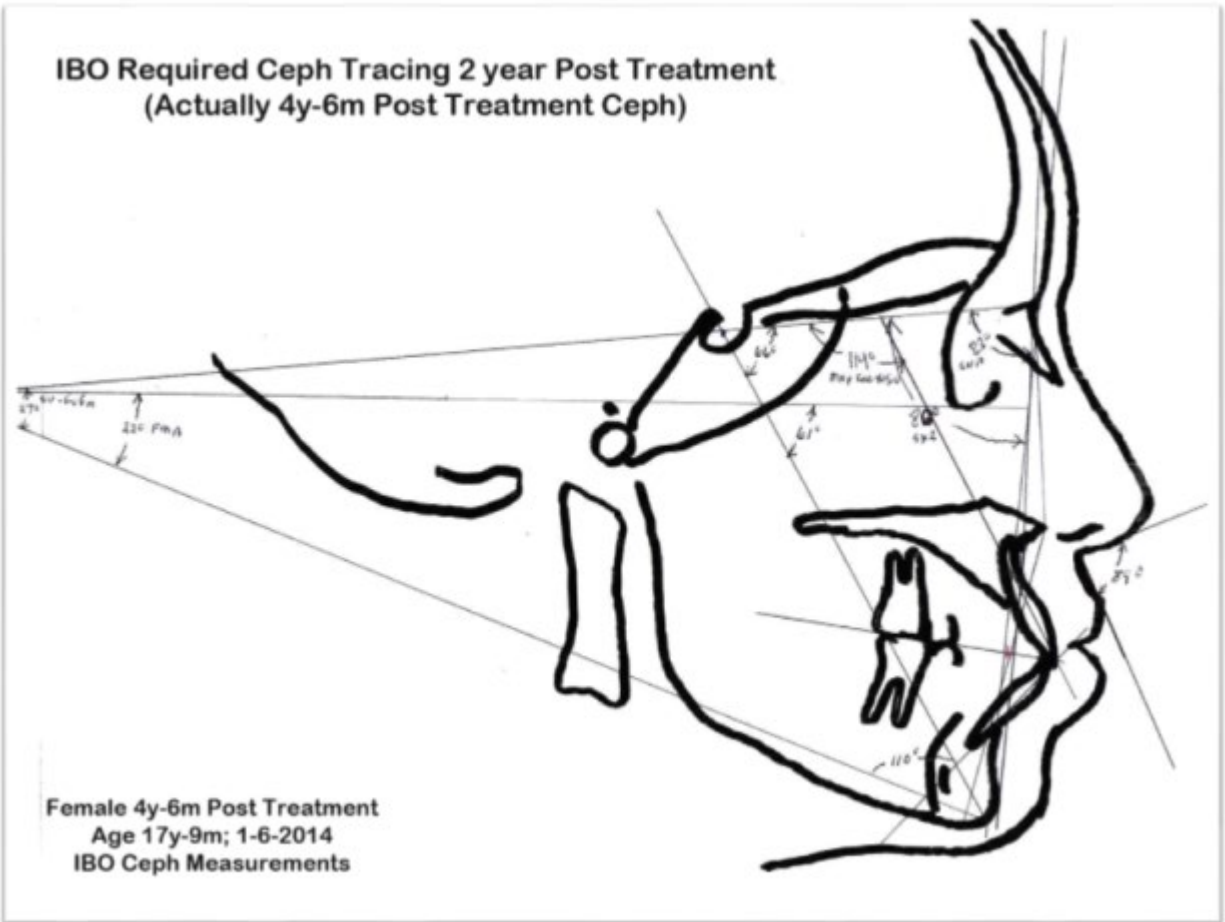
Post-Tx, IBO, 13y-2m, 6-2-2009



**4yr-6m Post-Tx, IBO, No Measurements, 17y-9m, 1-6-2014**



**4yr-6m Post-Tx, IBO, 17-9m, 1-6-2014**

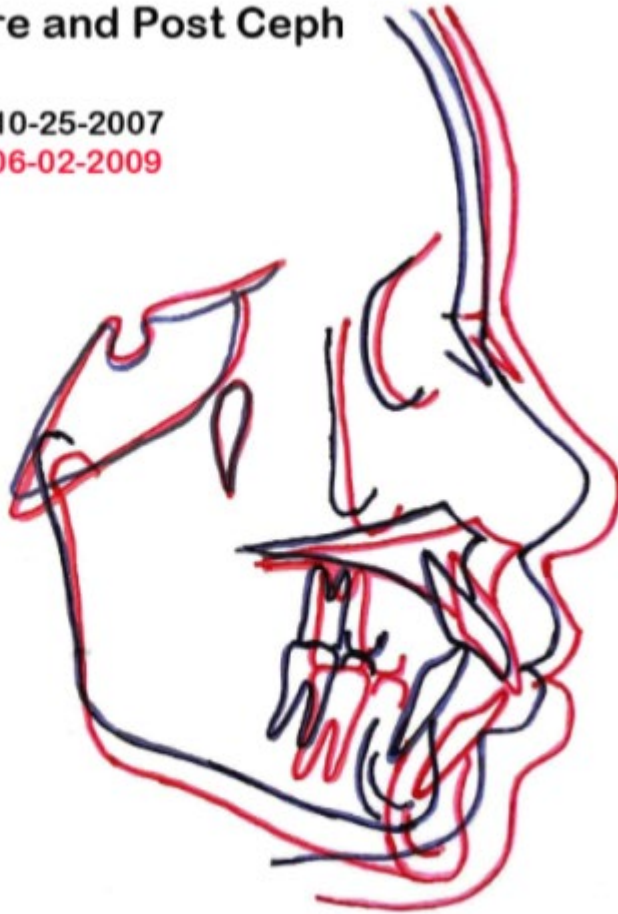

Superimposition, Pre vs Post

**Superimposition Pre and Post Ceph**

**Black = Pre Treatment 10-25-2007**

**Red = Post Treatment 06-02-2009**



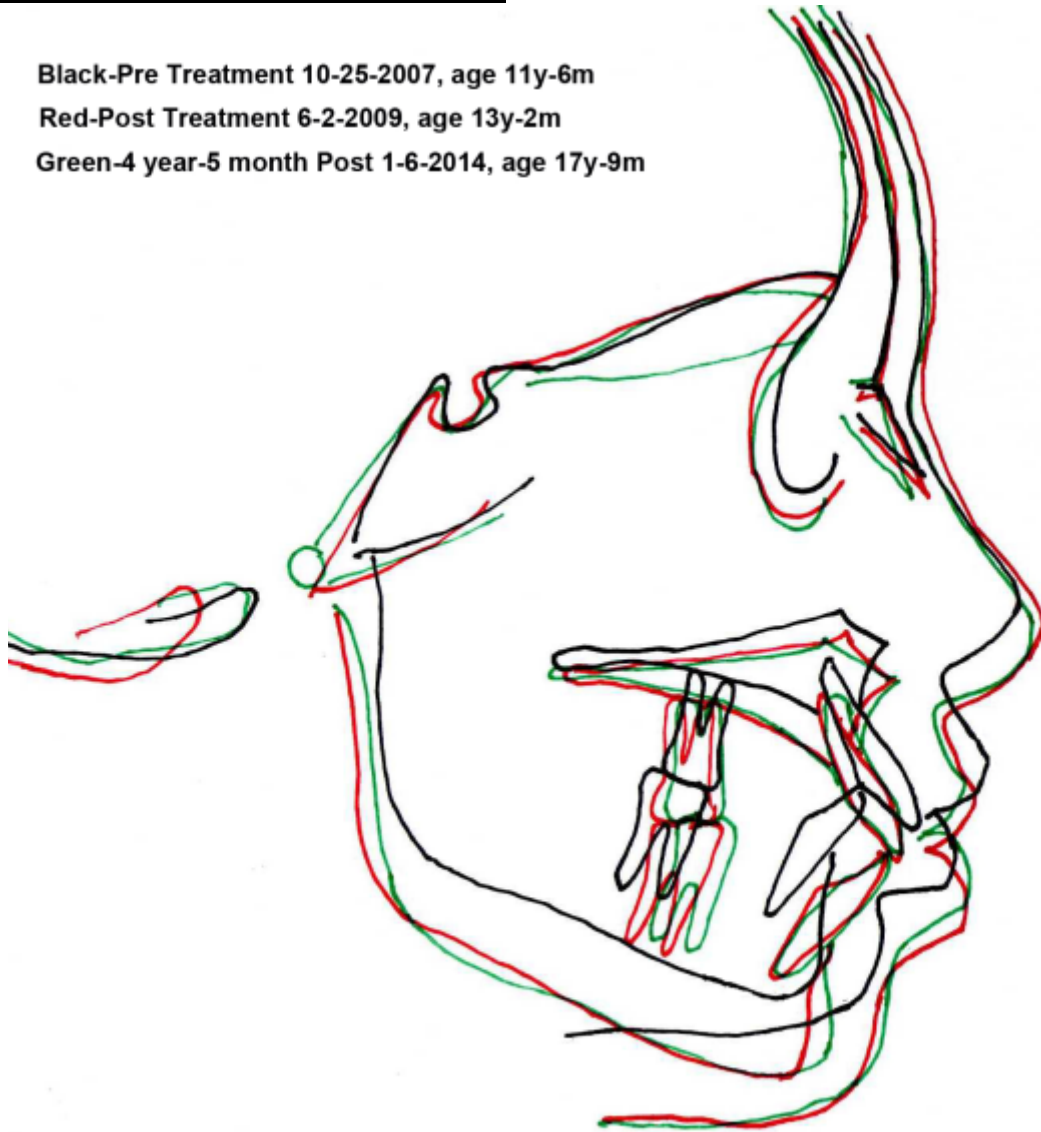


**Superimposition, Pre-Post-4yr6m Post**

**Black-Pre Treatment 10-25-2007, age 11y-6m**

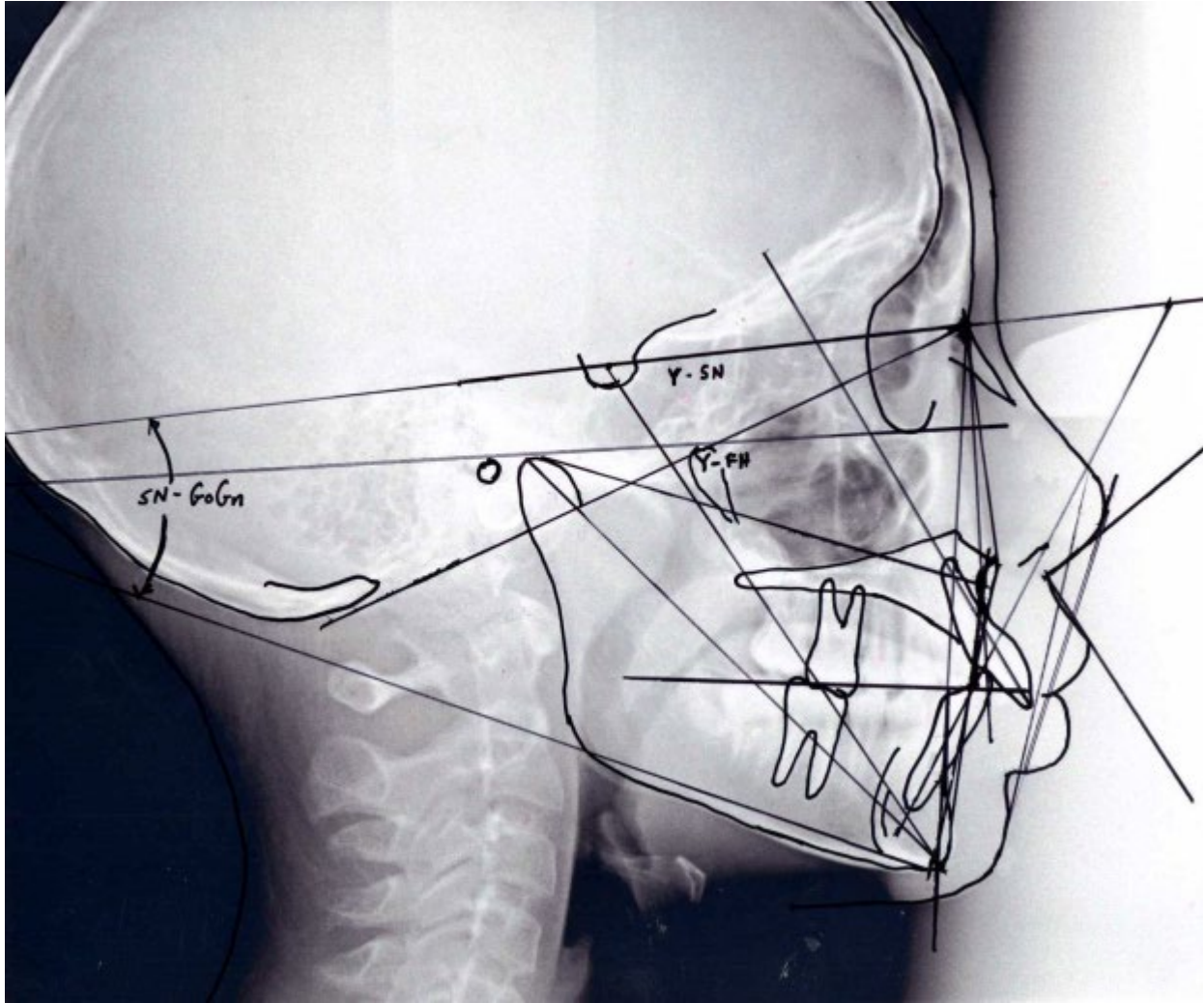
**Red-Post Treatment 6-2-2009, age 13y-2m**

**Green-4 year-5 month Post 1-6-2014, age 17y-9m**

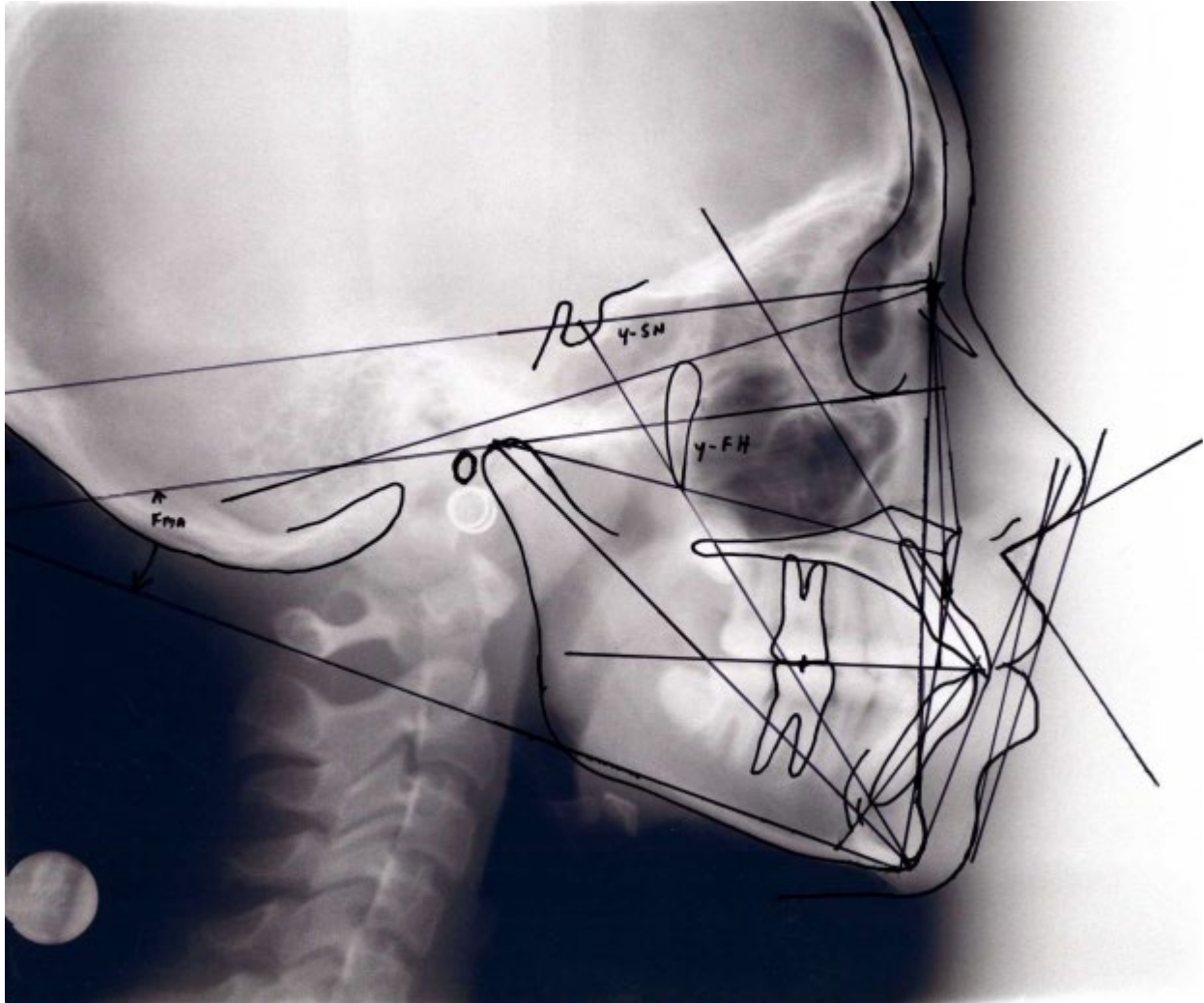


Cephalometric Radiograph/Tracing Overlays

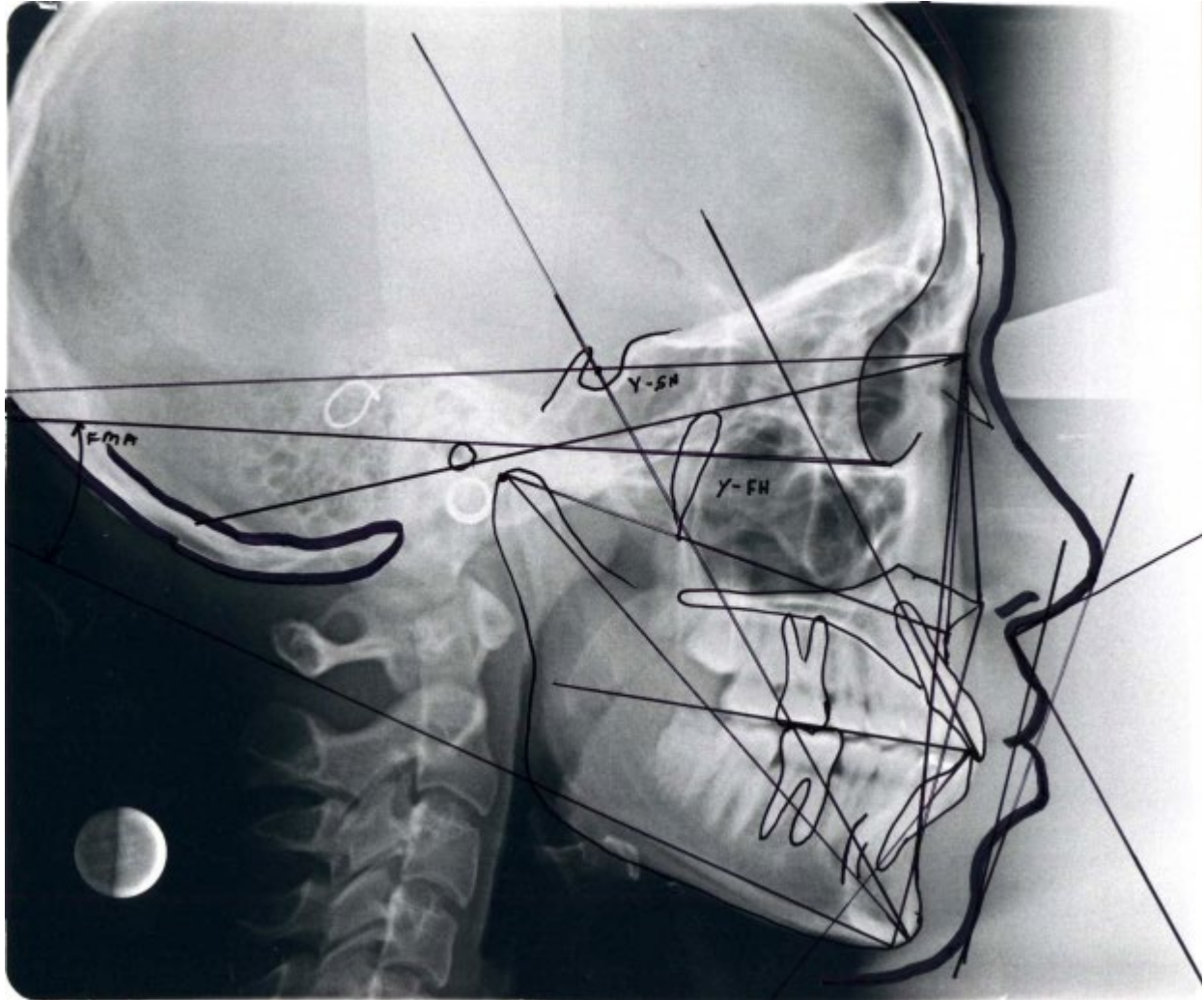
Pre-Tx, IBO



**Post-Tx, IBO**

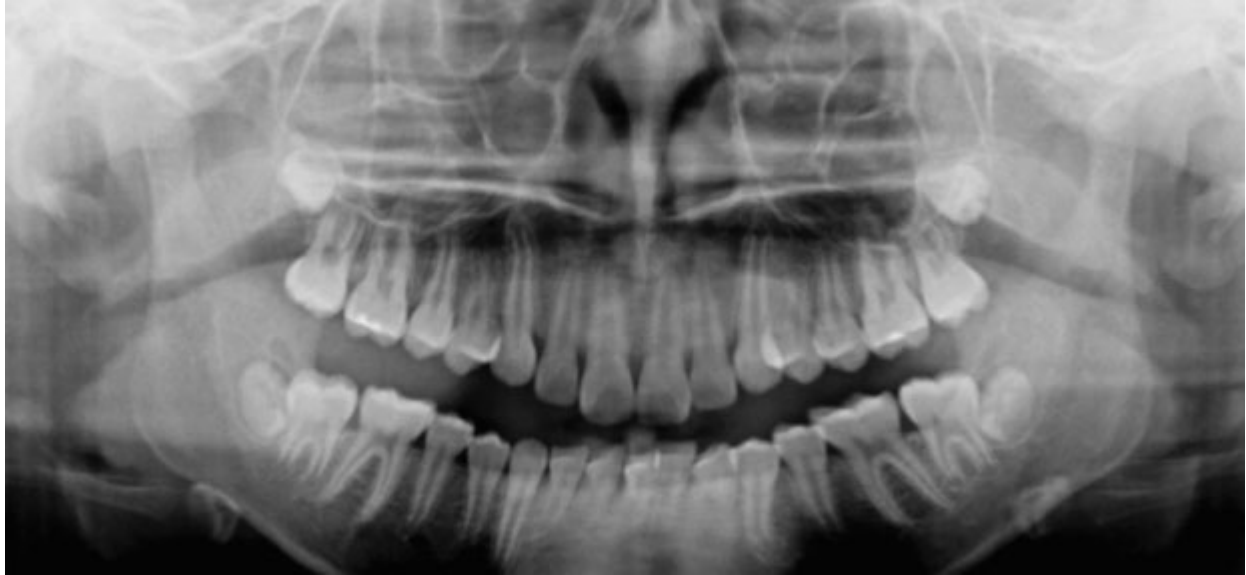

Post-Tx + 4y6m, IBO

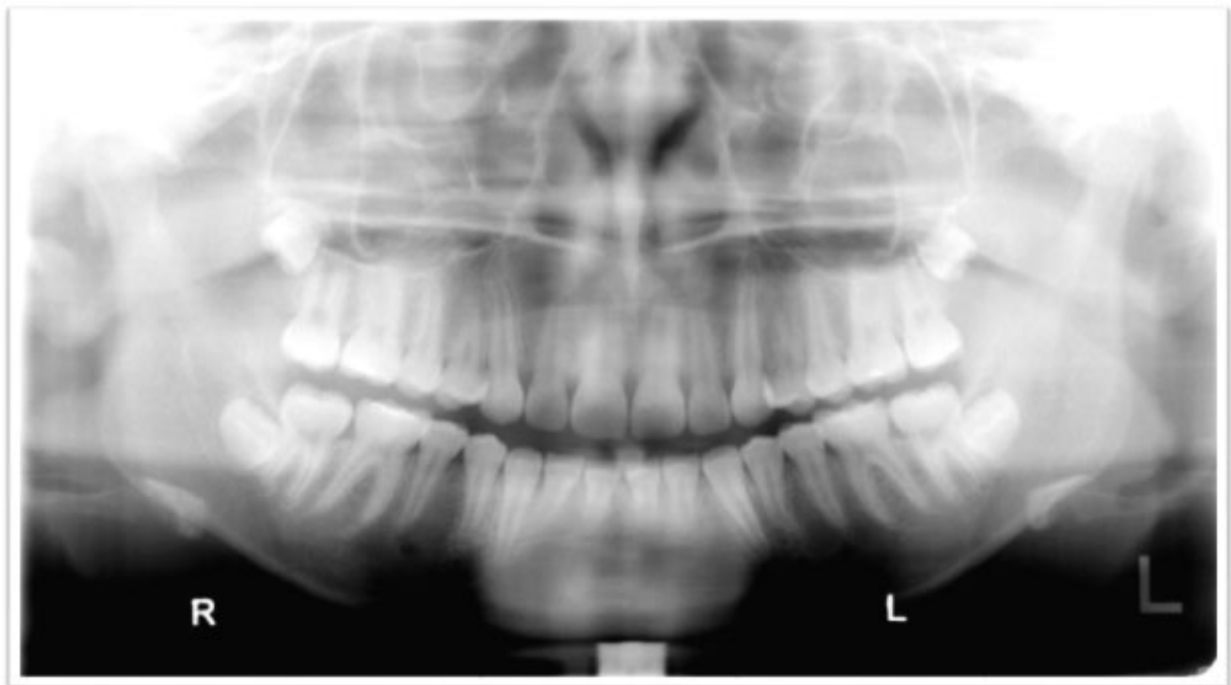


**Section IV: Panoramic/Full Mouth Series Radiographs**

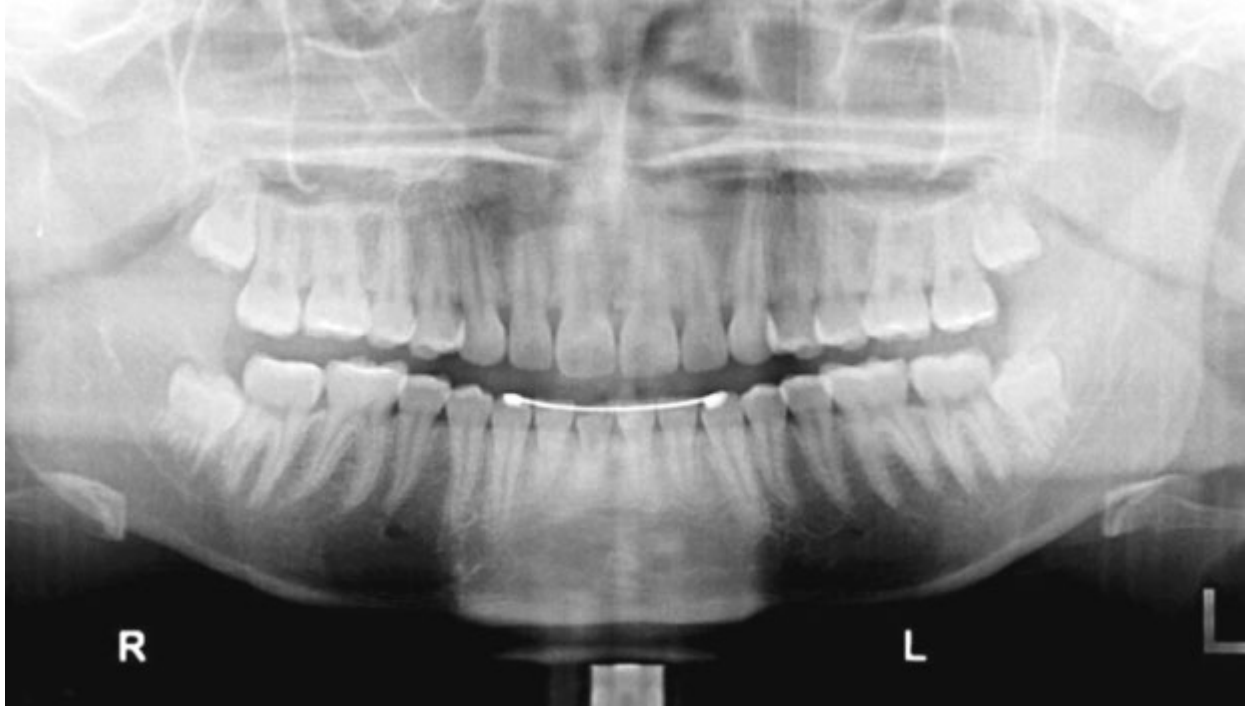
Pano/FMX Radiograph: pre-tx pano, 11y-6m, 10-25-2007



Pano/FMX Radiograph: post-tx pano, 13y-2m, 6-2-2009

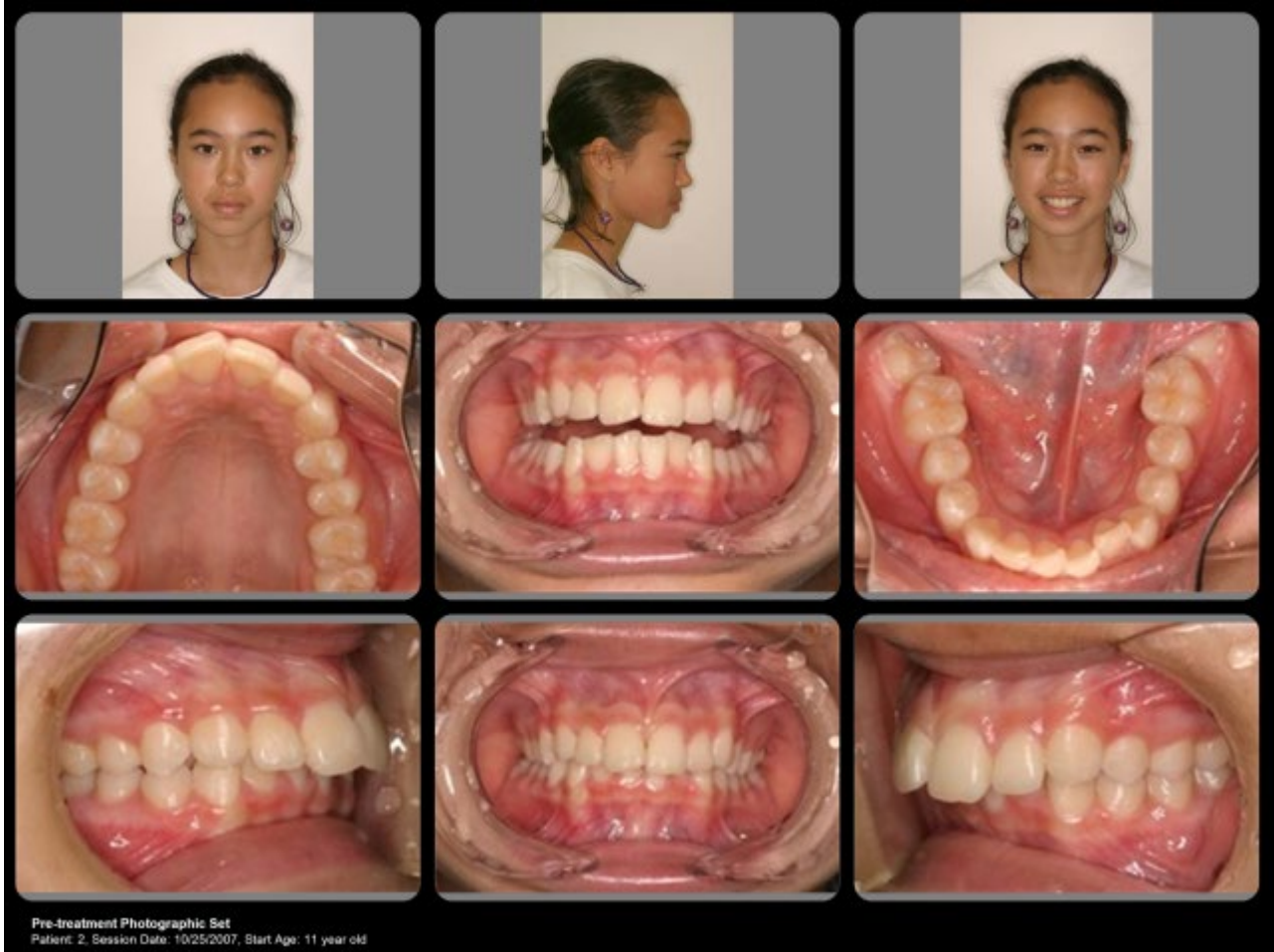


Pano/FMX Radiograph: 4Yr-6m Post-tx Pano, 17y-9m, 1-6-2013

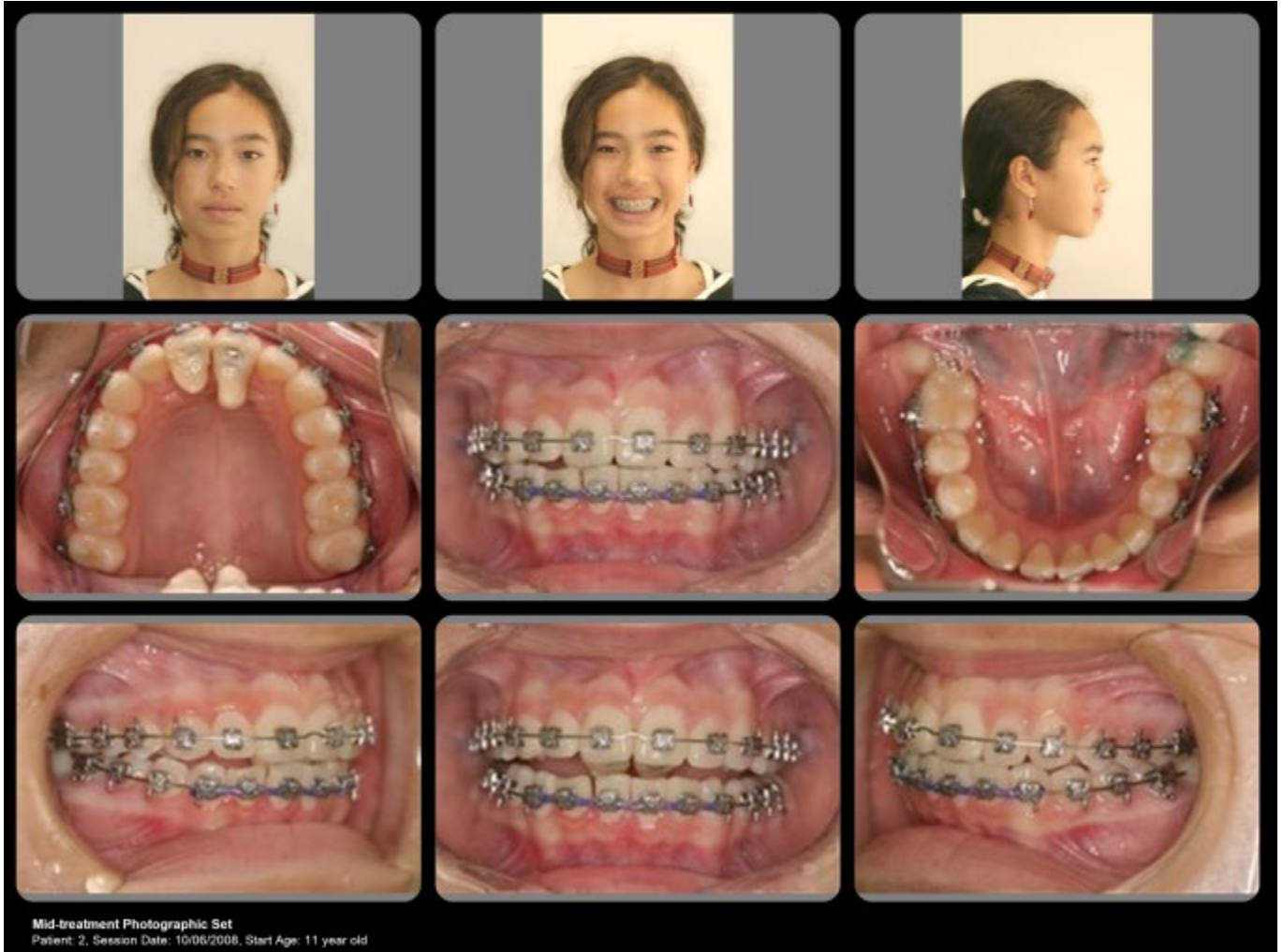

**Section V: Patient Photographs**

Patient Photographs: Pre-Treatment, Session Date: 10/25/2007



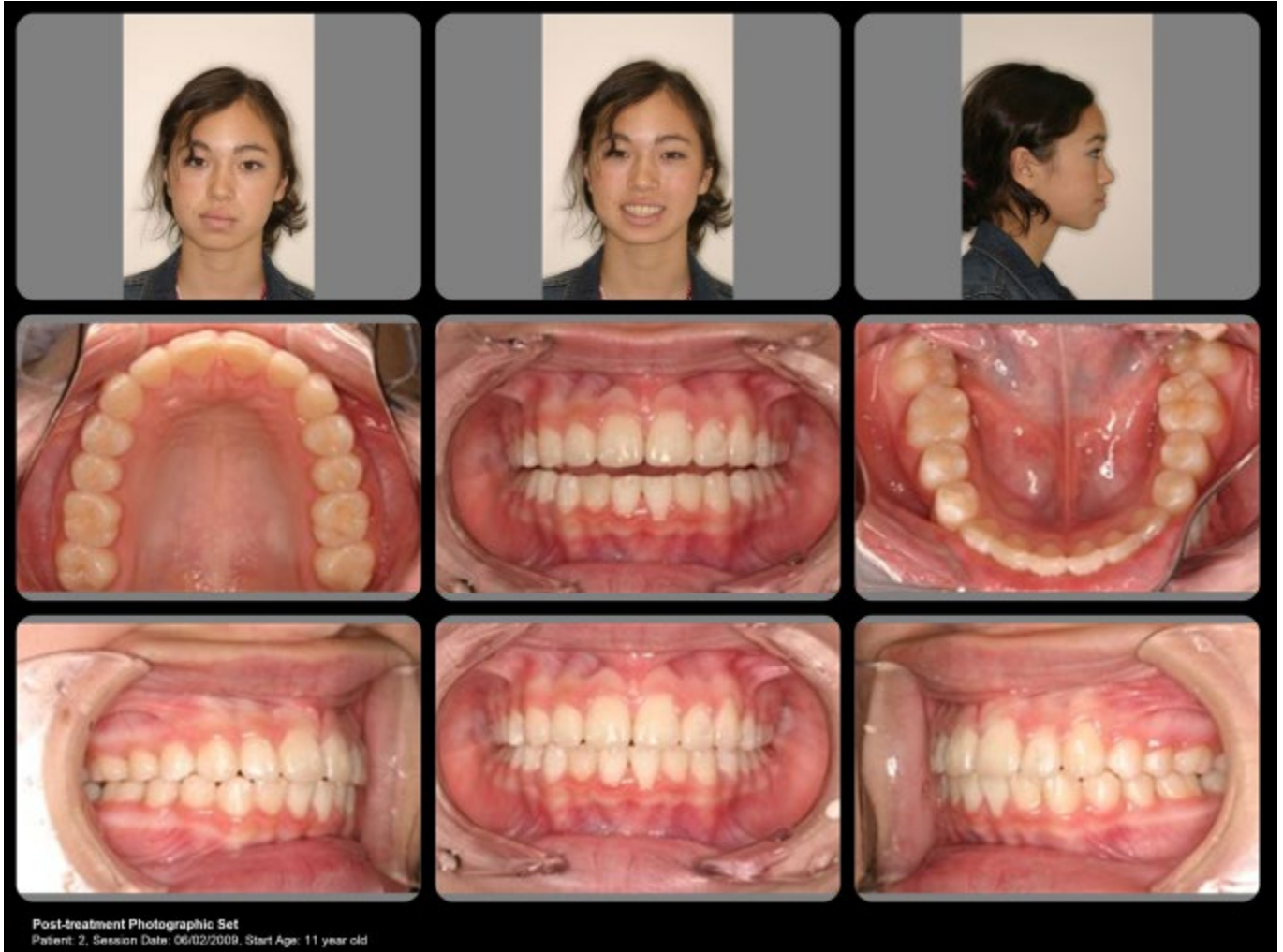Patient Photographs: Mid-Treatment, Session Date: 10/06/2008



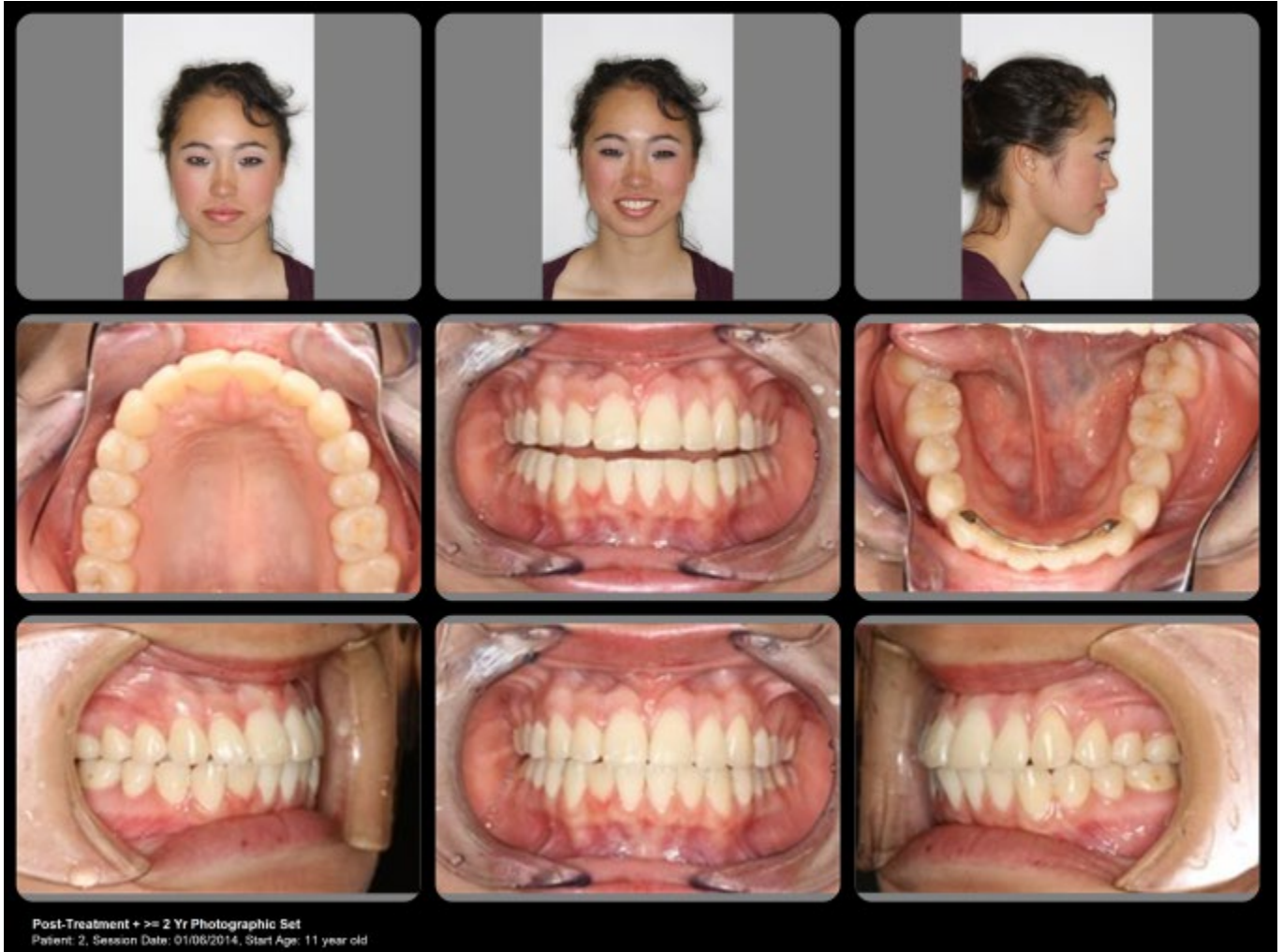
Mid-treatment Photographic Set  
Patient: 2, Session Date: 10/06/2008, Start Age: 11 year old



Patient Photographs: Post-Treatment, Session Date: 06/02/2009




Patient Photographs: Post-Treatment + 2 years, Session Date: 01/06/2014

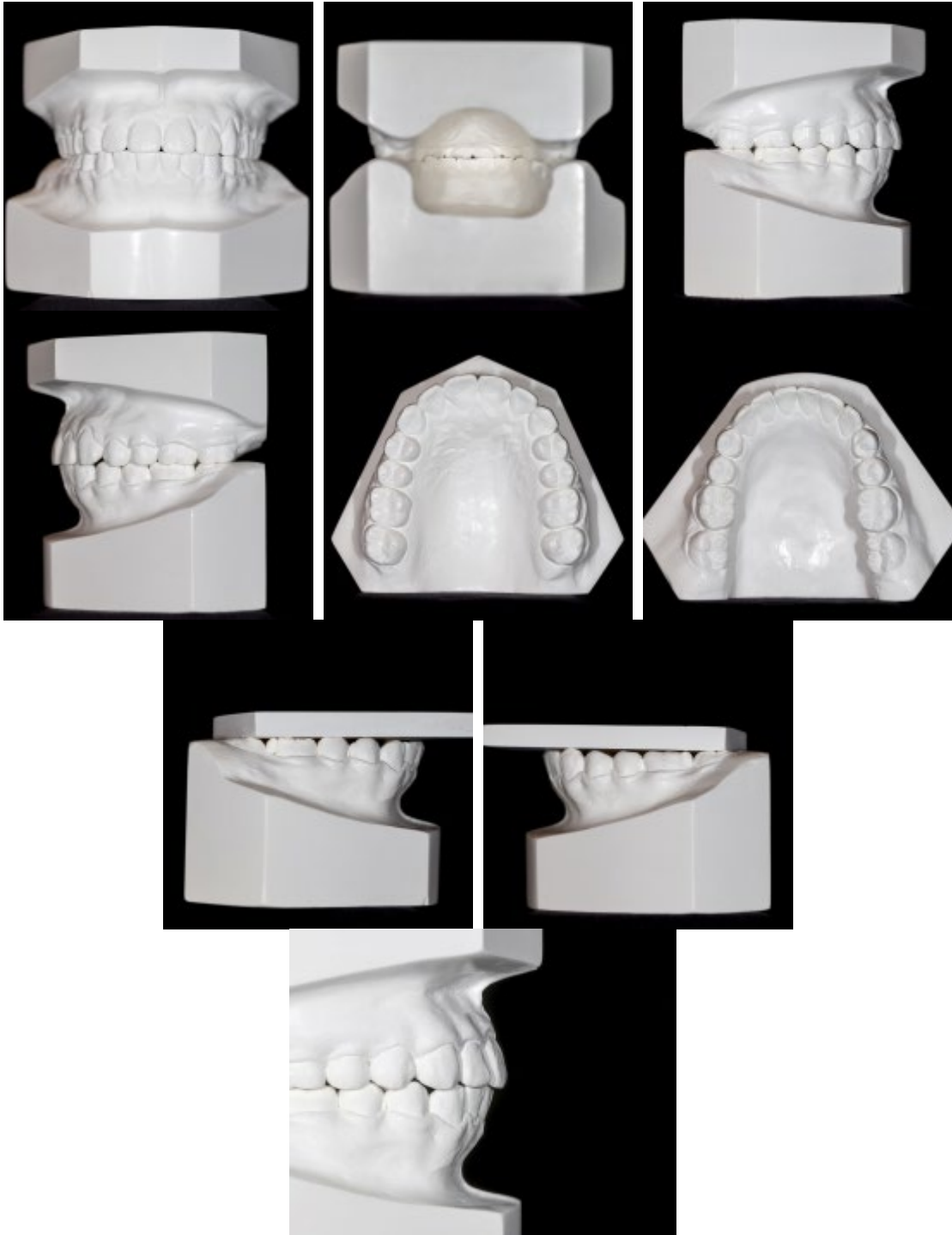


**Section VI: Study Models**

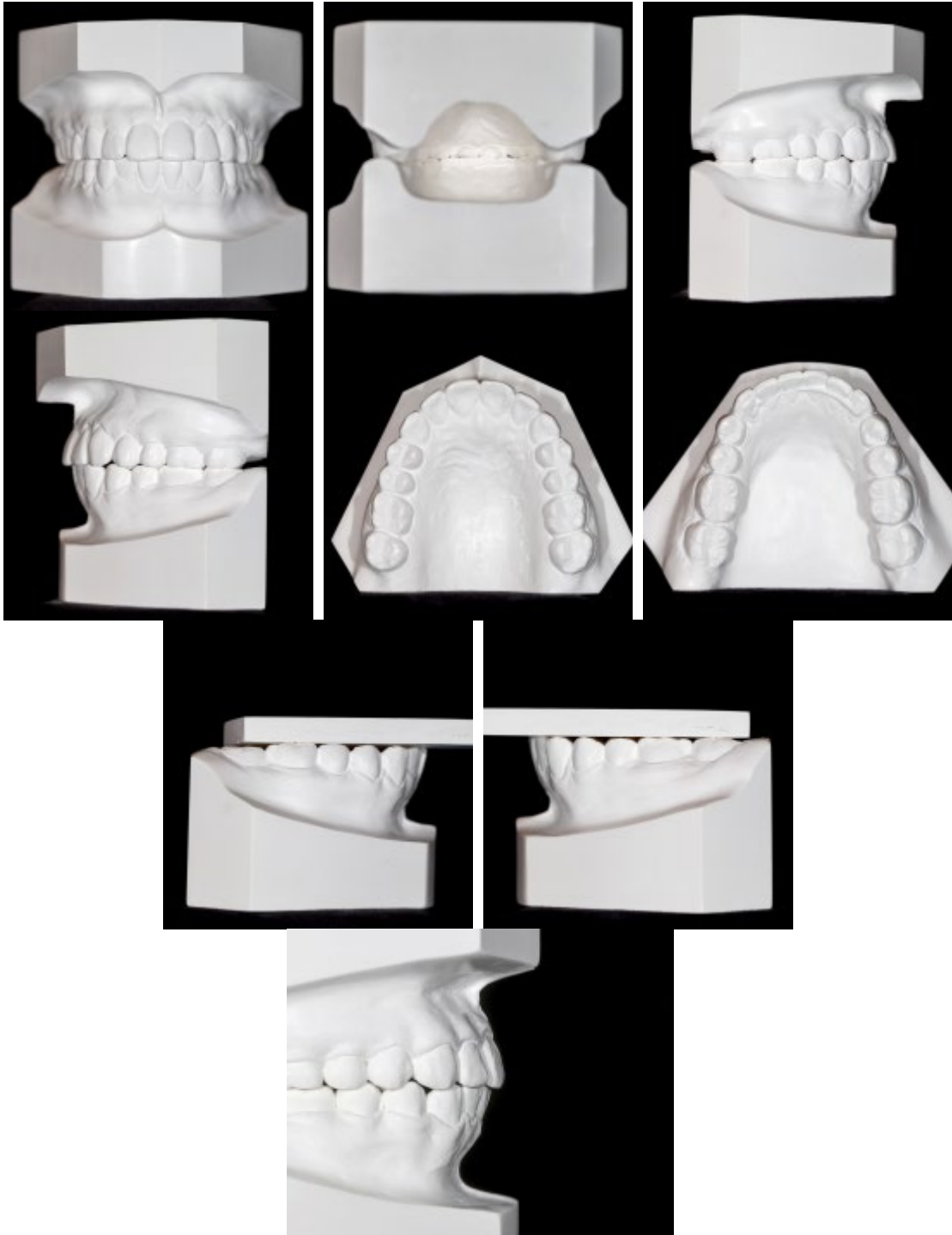
**Pre-Treatment**



Post-Treatment



Post-Treatment + >=2 Years



**Section VII: Cephalometric Analysis and IBO Summary****IBO Cephalometric Data Sheet**

Area	Norm	Pre	Post	+2Yr
<b>1. Analysis of Growth</b>				
a. Stage of Growth				
Growth Stage	---	Stage IV	Stage V	Stage VI
b. Direction of Growth				
Y-Axis to SN	66° +/-2	64	64	66
Y-Axis to FH	59° +/-2	60	69	61
<b>2. Analysis of Airways</b>				
a. Upper (nasopharynx)	8-18mm	4	6	8
b. Lower (oropharynx)	10-12mm	8	12	10
<b>3. Analysis of Skeletal Vertical</b>				
a. FMA	25° +/-5°	20	28	22
b. LAFH (ANS-Mn)	58-72mm	46-60	45-69	--
c. UAFH-LAFH/TAFH Ratio	50/50 C			
	45/55 A	43/57%	40/60%	42/58%
d. SN-GoMe	32° +/-3°	23	25	27
<b>4. Analysis of Skeletal Sagittal</b>				
a. Mx Len (Co-A)	(age=mm)	--	--	--
b. Mn Len (Co-Gn)	6=17mm	--	--	--
c. Mn-Mx Len Difference	9=20mm	18	23	25
	12=23mm			
	14=25mm			
	16=27mm			
d. Wits (Jacobson)	Class I: -2 to 2 Class II: >= 3 Class III: <= -3	3	1	-1
e. SNA	82° +/-3°	85	83	83
f. SNB	80° +/-3°	79	80	80
g. ANB	2° +/-2°	5	3	2
h. Na Perp - A pt	1mm +/-2mm	3	2	2
<b>5. Analysis of Dento-alveolar Relations</b>				
a. IMPA	95° +/-5	105	108	110
b. Interincisal Angle	131° +/-4	126	113	110
c. Mx incisor to SN	103° +/-4	115	115	114
d. Mn incisor to A-Pg	-1 to 3mm	3	8	6
<b>6. Analysis of Soft Tissue</b>				
a. Lower Lip - Rickett's Esthetic Line	-2mm +/-2	+4/+5	+1/+4	-2/+3
b. Naso-labial Angle	102° +/-8	97	100	89
c. Lip Seal (present or not)	Yes/No	Yes	Yes	Yes

## Section VIII: Case Diagnosis and Treatment Planning

### A. Case Diagnosis

1. GROWTH STAGE AND DIRECTION: This is an 11y-6m old female with some growth potential, CVM Stage III. This patient is neither a vertical or horizontal grower. Her Facial-Axis is  $90^\circ$ , Y-Axis are:  $SN=64^\circ$  and  $FH=60^\circ$
2. AIRWAY: Upper airway is constricted=4mm; Lower airway is constricted=8mm.
3. SKELETAL: Mesocephalic. Slightly asymmetric facial form, lower mandibular shift to the right.
4. VERTICAL: FMA of  $20^\circ$  and SN-GoGn of  $23^\circ$  suggest a low angle case. UFH/LFH of 43/57% suggests a normal or slightly long lower facial height. However, Jefferson Ceph analysis shows the lower facial height to be approximately -7mm short which coincides with the cephalometric measurement of a low angle case. Ultimately, facial evaluation (her facial photographs) should dictate this assessment. They show her lower facial height to be short.
5. SAGITTAL: This is an area of confusion. First, there is the sagittal assessment of maxilla against the mandible, and then there is the sagittal assessment of the maxilla and the mandible against the cranial base. Second, using various cephalometric analysis, there seem to be conflicting assessments with respect to evaluating the maxilla and the mandible against the cranial base.

--Assessment of maxilla against the mandible: Class I as assessed with  $ANB= 5^\circ$  and  $Wits= +3mm$ .

--Assessment of maxilla and mandible against the cranial base: Steiner  $SNA= 84^\circ$ ,  $SNB= 81^\circ$ .

This shows the maxilla and the mandible to be slightly prognathic. However, Jefferson cephalometric analysis shows that the maxilla is -4mm retrognathic and the mandible to be -6mm retrognathic against the cranial base. Ultimately, facial evaluation (her facial photographs) should dictate this assessment which shows both her maxilla and mandible are retrognathic. Skeletal Classification is Biskeletal Retrognathic; Sub Classification is Skeletal Class II.

6. DENTAL: Class II molars, Class II cuspids, Class II anteriors on left and right side. No cross bite, no missing teeth, normal tooth size, no spaces, no decay, no gingivitis. Curve of Spee= 3mm left and right side. Upper moderate crowding, lower moderate to severe crowding. Maxillary incisors significantly flared with Mx incisor to  $SN= 115^\circ$ , lower incisors significantly flared with  $IMPA= 105^\circ$  and Mn incisors to  $A-Pog= 3mm$ . The interincisal angle= $126^\circ$  supports the flared pre-treatment condition. Lower mandibular incisor midline shift to the right approximately 4mm from the upper incisor midline
7. SOFT TISSUE: Facial and photographic evaluation show maxilla slightly retrognathic, mandible significantly retrognathic, and significantly short lower facial height. Normal lip shape and lip seal. Nasolabial angle=  $97^\circ$  is acute. Rickett's Esthetic Line= +4mm/+5mm and Steiner's S-Line=

+6mm/+6mm show her lips to be protrusive. She has a minor gummy smile (excessive gingival display).

8. TMJ/TMD: Full range of motion, max opening, max opening 52mm, both lateral movements= 10mm. Protrusive is 7mm, no deviation or deflection, no pain, no clicking, no crepitus, no popping.

## **B. Treatment Planning**

### **1. Treatment Objectives**

1. Upper arch: Expand upper arch, correct significant upper incisal flare and moderate crowding.
2. Lower arch: Expand lower arch, correct lower incisal flare and moderate to severe crowding.
3. Sagittal: Both maxilla and mandible are retrognathic. Attempt to move both forward to a more normal A-P position. Significant overjet= 10mm. Attempt to correct overjet to normal if possible. Significant recessed chin. Attempt to move mandible forward to a more normal and esthetically pleasing position.
4. Vertical: According to Jefferson cephalometric analysis, lower facial height is short by -7mm. This is confirmed by her facial photographs. Attempt to increase lower facial height to a more normal and esthetically pleasing position.
5. Horizontal: Lower mandible has a slight mandibular shift to the right due to occlusion. Lower dental midline shift to the right= 4mm. Attempt to shift mandible to a more normal and centered position.

### **2. Treatment Plan**

1. Mechanics: Fixed Functional therapy. Straightwire mechanics, in conjunction with a Fix-A-Nator technique. (Reference for the Fix-A-Nator technique can be found in the International Journal of Orthodontics, 2006 Fall; 17(3): 23-31.) Used self-ligating, frictionless brackets (Carriere brackets) to level, align, and expand the arches. Used Anterior Biteguides and 2nd molar composite buildups to reposition the mandible forward and to increase lower facial height. The wire sequence for upper and lower: .014 preformed round nitinol, 16x16 preformed square nitinol, 16x25 preformed rectangular nitinol, and 18x25 preformed rectangular nitinol.
2. Retention: Upper Hawley retainer with a small anterior bite plane to prevent loss of expansion and intrusion of posterior teeth which can cause relapse to short lower facial height. Lower bonded retainer from canine to canine.
3. Estimated treatment time: 18 months. Actual treatment time: 18 months.

### **3. Limitations, Complications, and Prognosis**

Prognosis is good but guarded. Patient's skeletal discrepancy is severe with mandibular retrognathism of -6mm to the norm, and a lower facial vertical height of -7mm to the norm. Patient and mother were informed that skeletal discrepancy will be improved, but perfect result is not guaranteed.

### **4. Mechano-therapy**



1. Mechanics: Fixed Functional therapy. Straightwire mechanics, in conjunction with a Fix-A-Nator technique. (Reference for the Fix-A-Nator technique can be found in the International Journal of Orthodontics, 2006 Fall; 17(3): 23-31.) Used self-ligating, frictionless brackets (Carriere brackets) to level, align, and expand the arches. Used Anterior Biteguides and 2nd molar composite buildups to reposition the mandible forward and to increase lower facial height. The wire sequence for upper and lower: .014 preformed round nitinol, 16x16 preformed square nitinol, 16x25 preformed rectangular nitinol, and 18x25 preformed rectangular nitinol.
2. Retention: Upper Hawley retainer with a small anterior bite plane to prevent loss of expansion and intrusion of posterior teeth which can cause relapse to short lower facial height. Lower bonded retainer from canine to canine.

#### 5. Evaluation of Treatment Progress

Considering the severity of patient's skeletal discrepancy; i.e., 10mm overjet, -6mm mandibular retrognathism, and lower facial height short by -7mm based on Jefferson Cephalometric Analysis, her treatment progressed very well. Patient was cooperative and had excellent oral hygiene. Patient treatment result was not perfect but excellent. Both the mother and child were happy with the treatment result. Patient was referred to me by a general dentist. They lived quite a distance from my office in another state, and therefore, did not want to come back for a 2 year post treatment records.

**Section IX: Case Finishing and Treatment Results**

- A. Overjet/Overbite:** 1mm/2mm
- B. Cuspid/Molar Relation:** Acceptable cuspid protected occlusion
- C. Plane of Occlusion:** In proper alignment both left and right side
- D. 7's in Occlusion:** In occlusion and acceptable intercuspation
- E. Marginal Ridges:** Both upper and lower acceptable. Slight discrepancy between 1st and 2nd molars.
- F. Rotations:** Both upper and lower acceptable. Minor problems teeth nos. 11, 12, 21, and 28.
- G. Spaces:** All spaces closed, both upper and lower arch
- H. Soft Tissue (Intraoral):** Significantly improved facial and dental esthetics and function after treatment. Maxilla which was -4mm retrognathic was brought forward 2mm. Mandibular which was -6mm retrognathic was brought forward 4mm. Lower facial height which was short by -7mm was increased by 5 mm to near normal vertical height.
- I. Root Parallelism:** Before treatment, roots were not parallel between teeth nos. 10-11, 20-21-22. After treatment root parallelism was not perfect but improved.
- J. Facial & Dental Midlines:** Facial asymmetry (mandibular shift to the right) improved but not entirely corrected. Mandibular incisor midline had a 4mm shift to the right from the maxillary incisor midline. After treatment, the mandibular shift was reduced from 4mm to 1mm. This treatment resulted in enhanced facial esthetic improvement.
- K. Results - Skeletal:** Patient was bi-skeletal retrognathic, and vertically short. After treatment, significant skeletal improvement according to superimposition of pre-treatment and post-treatment cephalometric radiographs Steiner, Wits, and Jefferson Ceph Analysis.
- Superimposition of Pre and Post ceph shows significant skeletal improvements: maxilla developed forward, mandible repositioned and developed forward, lower facial height which was -7mm short was increased by +5mm to near normal vertical. These skeletal improvements correlated with a more esthetic facial profile (Rickett's Esthetic Line from +4mm/+5mm to +1mm/+4mm; Naso-Labial angle from 97° to 100°; Steiner's S-line from +6mm/+6mm to +5mm/+6mm).
  - Steiner: FMA from 20° to 28°; SN-GoGn from 23° to 25°; ANB from 5° to 3°.
  - Wits: From 3mm to 1mm.
  - Jefferson: ANS to Ant Arc from -4mm to -2mm; P to Ant Arc from -6mm to -2mm; M to age appropriate Vert Arc from -7mm to -2mm.
  - Four years and 6 months post treatment assessment showed continuous skeletal improvements based on IBO ceph measurements in lower vertical height, SNA and SNB; however, IMPA and

Interincisal Angle got slightly worse. ANS advanced 1mm to near normal A-P position; Pogonion moved from -2mm to 0 which means mandible is at perfect A-P position; and Menton is -1mm from ideal lower vertical height which can be determined as near perfect lower facial height.

**L. Results - Dental:** Before treatment patient was Class II molars, Class II cuspids, and Class II anteriors both left and right side; severe overjet by 10mm; severe deep bite 80 to 90% deep. After treatment patient was Class I molars, Class I cuspids, and Class I anteriors both left and right side; overjet reduced to 2mm, severe deep bite to 10% near normal. Occlusion was near normal except minor marginal discrepancy of lower 2nd molars.

- Patient was referred to me by a general dentist and lived quite a distance from my office. She never returned for a 2-year post treatment record. Four years and 6 months later, I was able to take records.
- Four years and 6 months post treatment assessment showed that although there was minimal dental relapse, IMPA increased by 2°, Interincisal angle became more acute by 3°. These two measurements diverged from the norm. There was no explanation for this.

**M. Results - TMJ:** No signs or symptoms, full range of motion at the end of treatment.

**N. Results - Retention:** Maxillary Hawley retainer with a small anterior bite plane to prevent intrusion of posterior teeth. Lower bonded retainer from canine to canine.

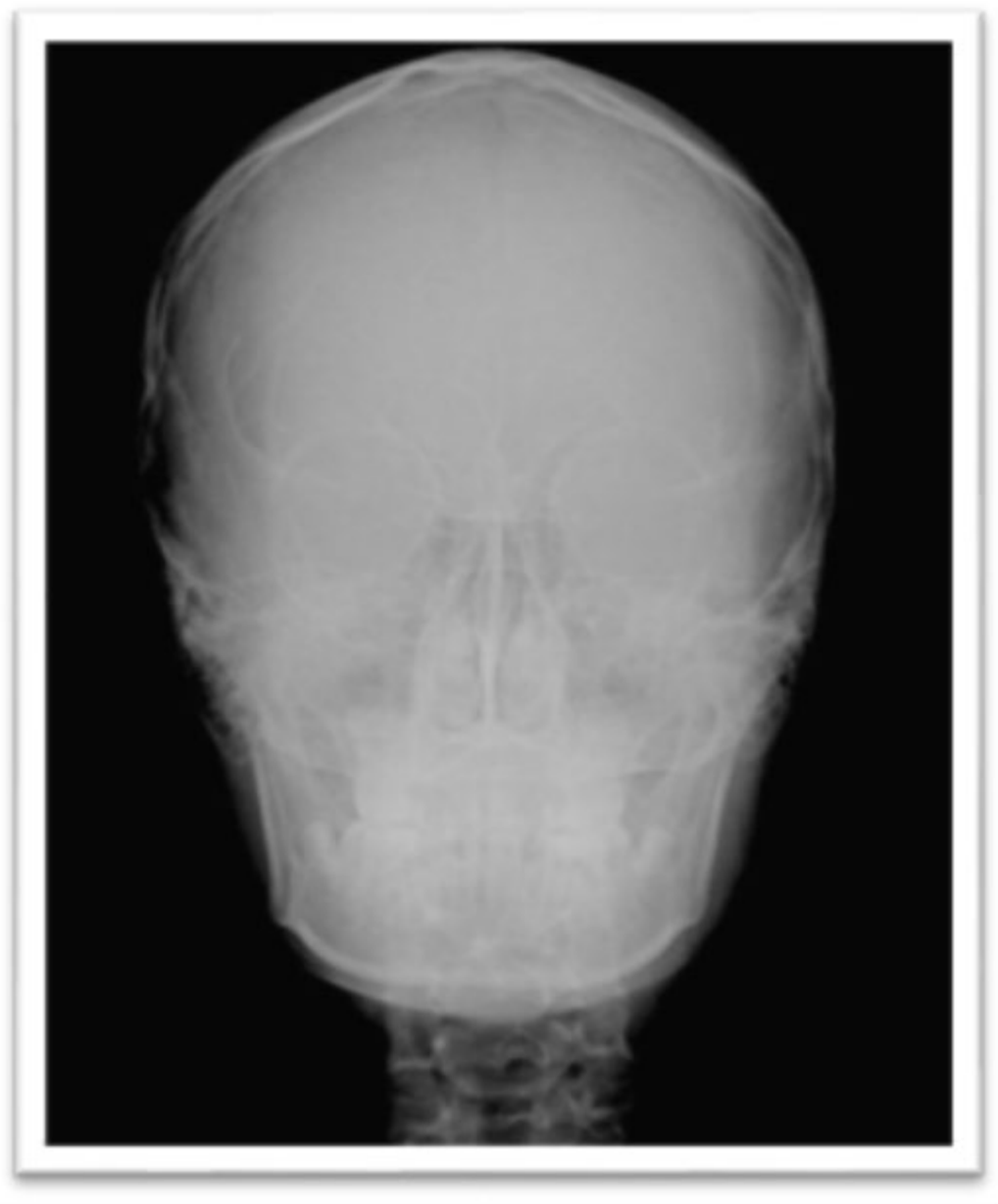**O. Results - Treatment Time:** Started 12-13-2007, finished 6-2-2009. Estimated treatment time 18 months, actual treatment time 18 months.

**Section X: Case Analysis and Discussion**

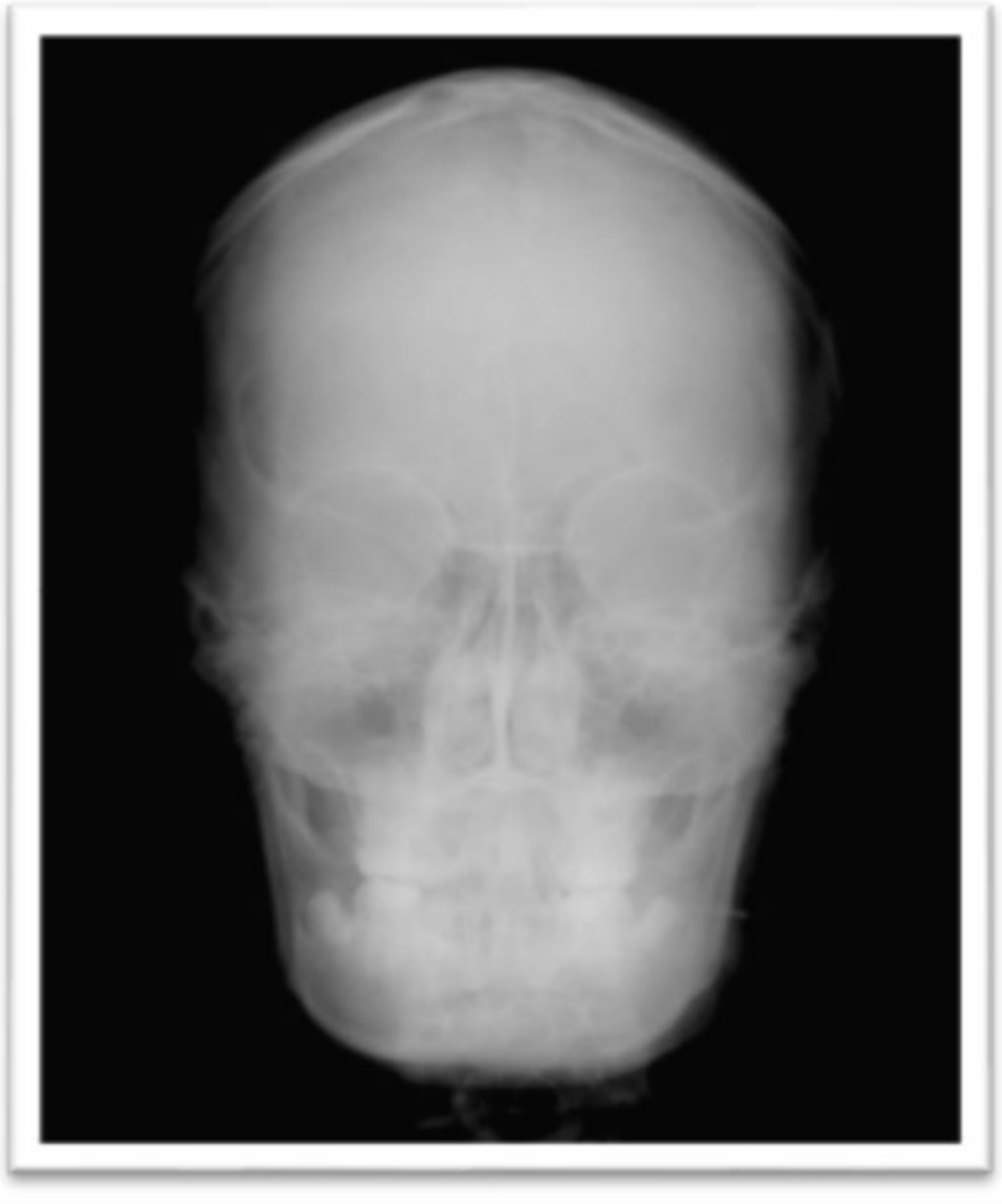- A. Facial Esthetics:** Soft tissue consideration: Significantly improved facial and dental esthetics and function after treatment.
- B. Skeletal / Dental:** Patient was bi-skeletal retrognathic, and vertically short. After treatment, significant skeletal improvement. Before treatment, patient was Class II molars, Class II cuspids, and Class II anteriors both left and right side; severe overjet by 10 mm; severe deep bite 80 to 90% deep. After treatment, patient was Class I molars, Class I cuspids, and Class I anteriors both left and right side; overjet reduced to 2mm; severe deep bit to 10% near normal.
- C. Superimpositions:** Superimposition of the Pre and Post ceph shows significant skeletal improvements: maxilla developed forward, mandible repositioned and developed forward, lower facial height which was -7mm short was increased by +5mm to near normal vertical. These skeletal improvements correlated with an more esthetic profile.
- D. Difficulty of Case:** This case was complicated by the severity of the various skeletal discrepancies, the treatment, surprisingly, was simple, and the results were excellent. Both the mother and the patient were happy with the final treatment result.
- E. Achievement of Treatment Objectives:** Yes. The case was a severe skeletal discrepancy case both sagittal and vertical. The patient was treated totally with fixed functional therapy. No removal appliances were used. Fix-A-Nator technique was used to reposition the mandible forward and to increase lower facial height to allow the posterior teeth to erupt. Self-ligating, frictionless brackets (Carriere Brackets) were used to level, align, and to expand the arches.
- F. Other Discussion:** The patient was cooperative which enhanced the success of this treatment.
- G. Two-Year Evaluation:** The patient was referred to me by a general dentist. They also lived quite a distance from my office. They did not want to travel for the two year post treatment records. However, four years later, I was able to convince the mother that I wanted to make sure her daughter's case did not relapse, and it was important for me to evaluate her. The daughter was studying abroad in Sweden, and I had to wait until she came home during school break. Post records were then taken 4 years and 6 months later. Four years and 6 months later, both mother and patient were still happy with the treatment.

**Appendix A: Additional Supporting Imaging**

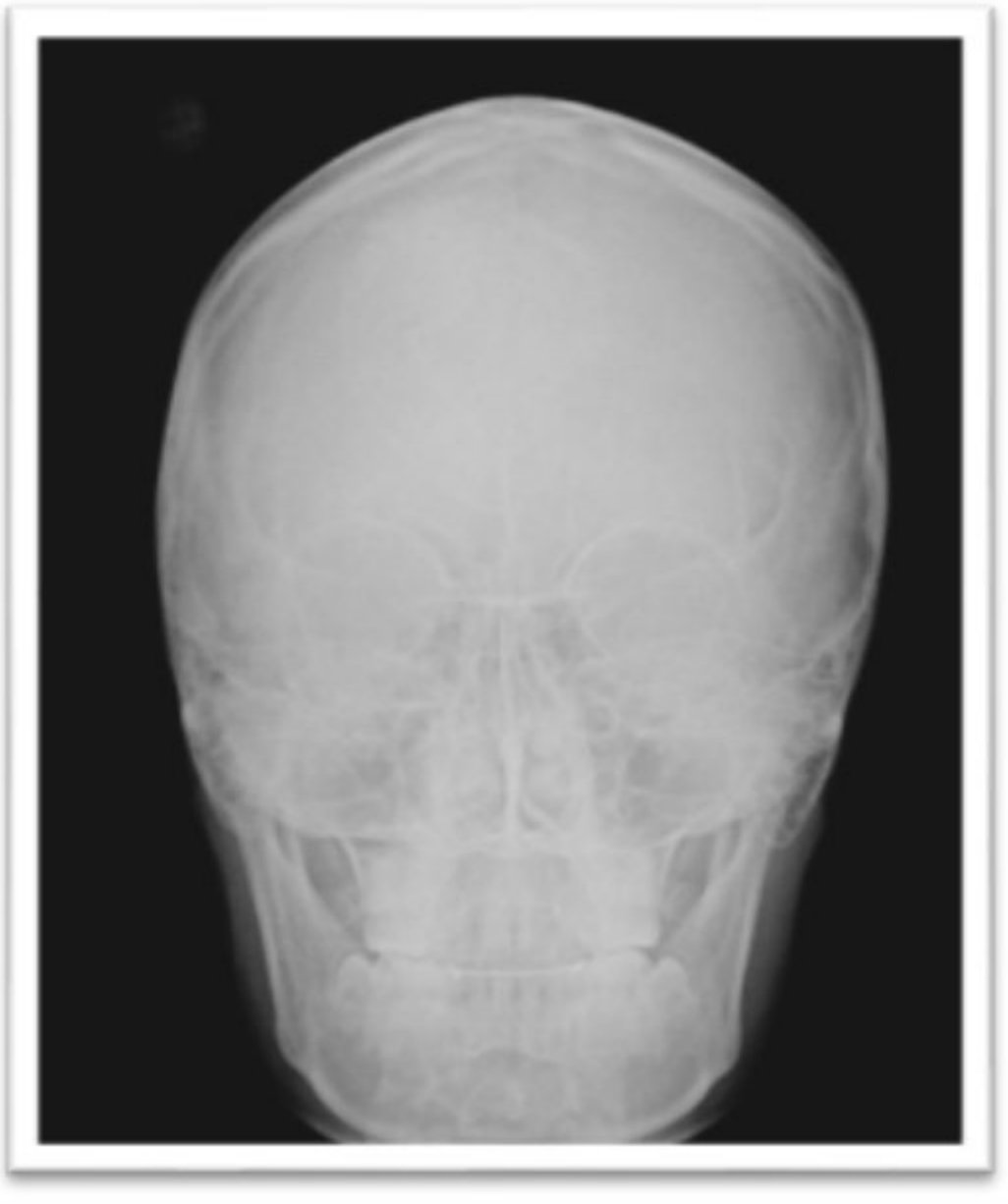Additional Image: pre-tx frontal ceph, 11y-6m, 10-25-2007



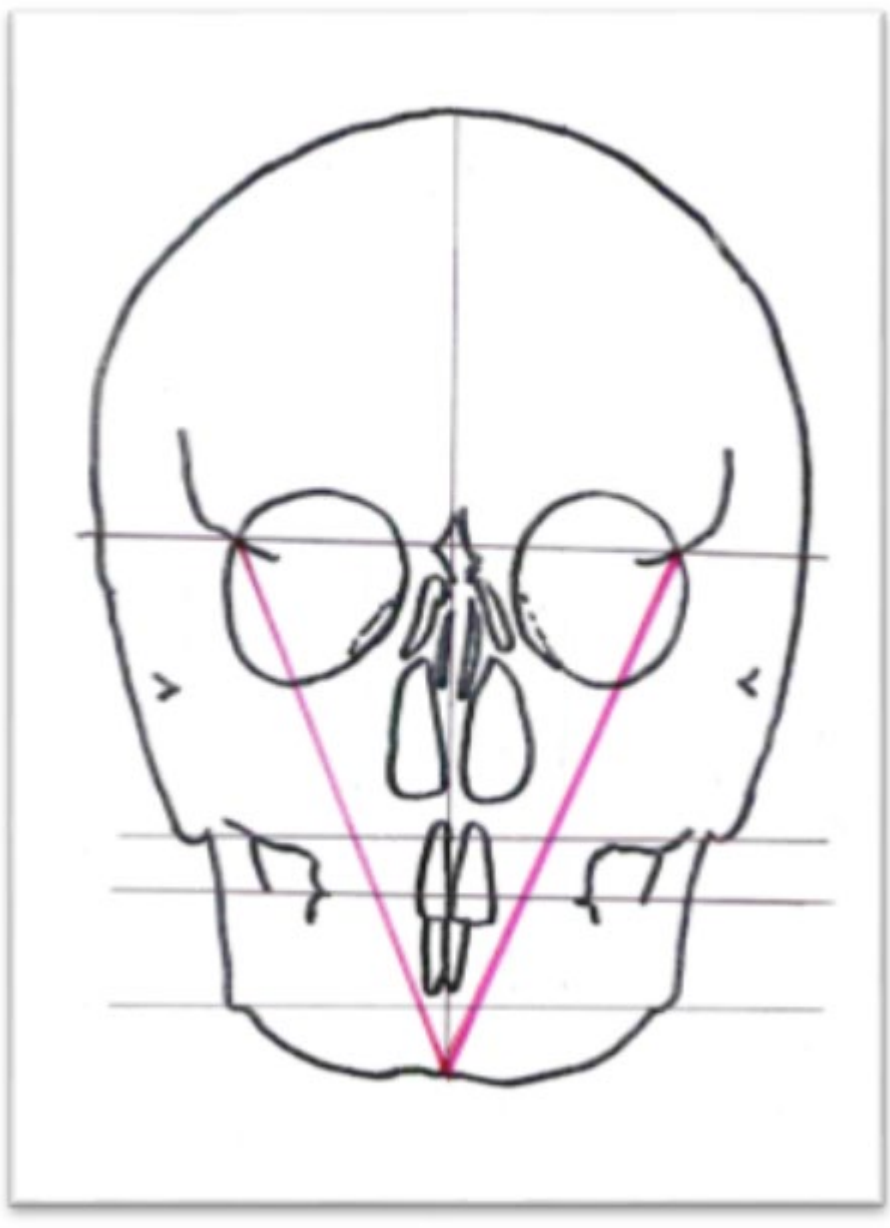
Additional Image: post-tx frontal ceph, 13y-2m, 6-2-2009



Additional Image: 4y-6m post-tx frontal ceph, 17-9m, 1-6-2014

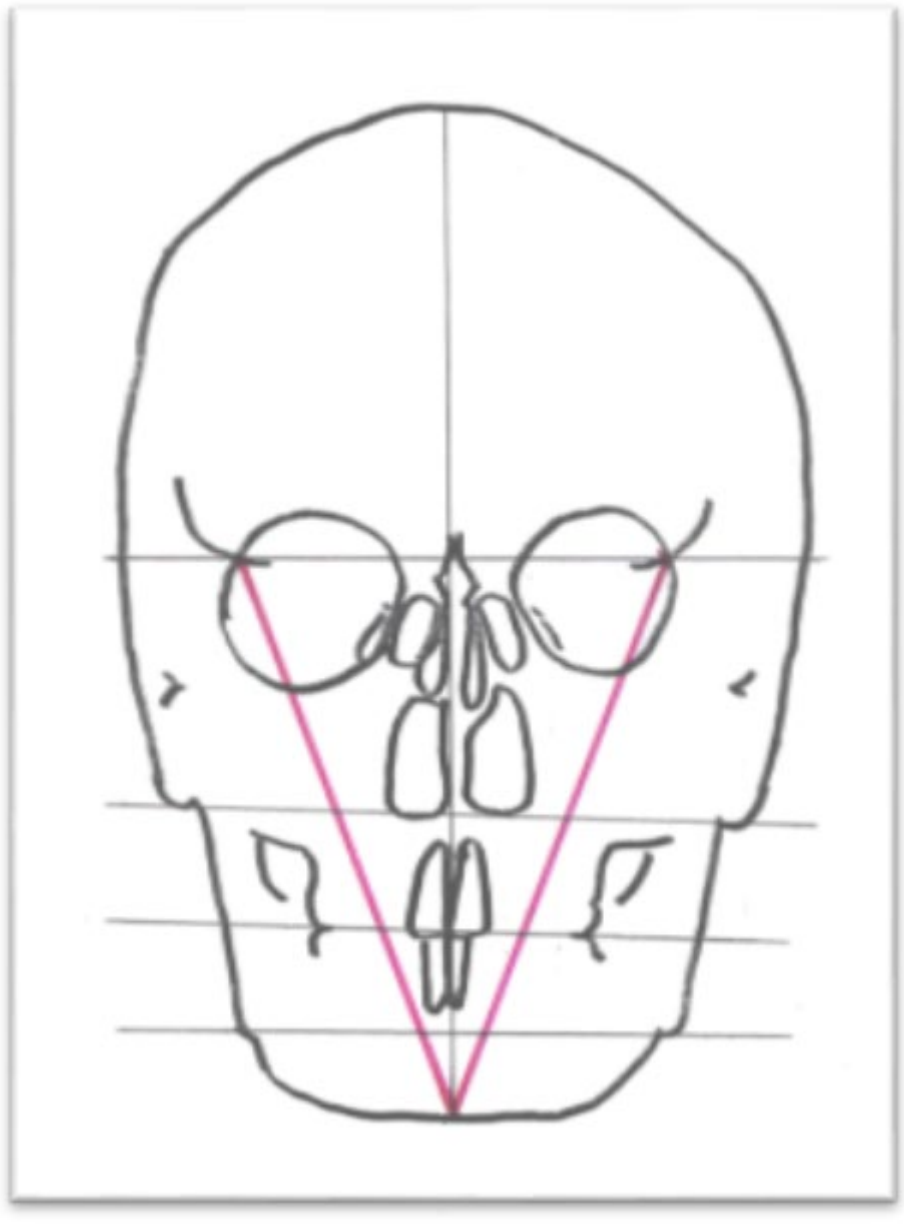


Additional Image: frontal, pre-tx

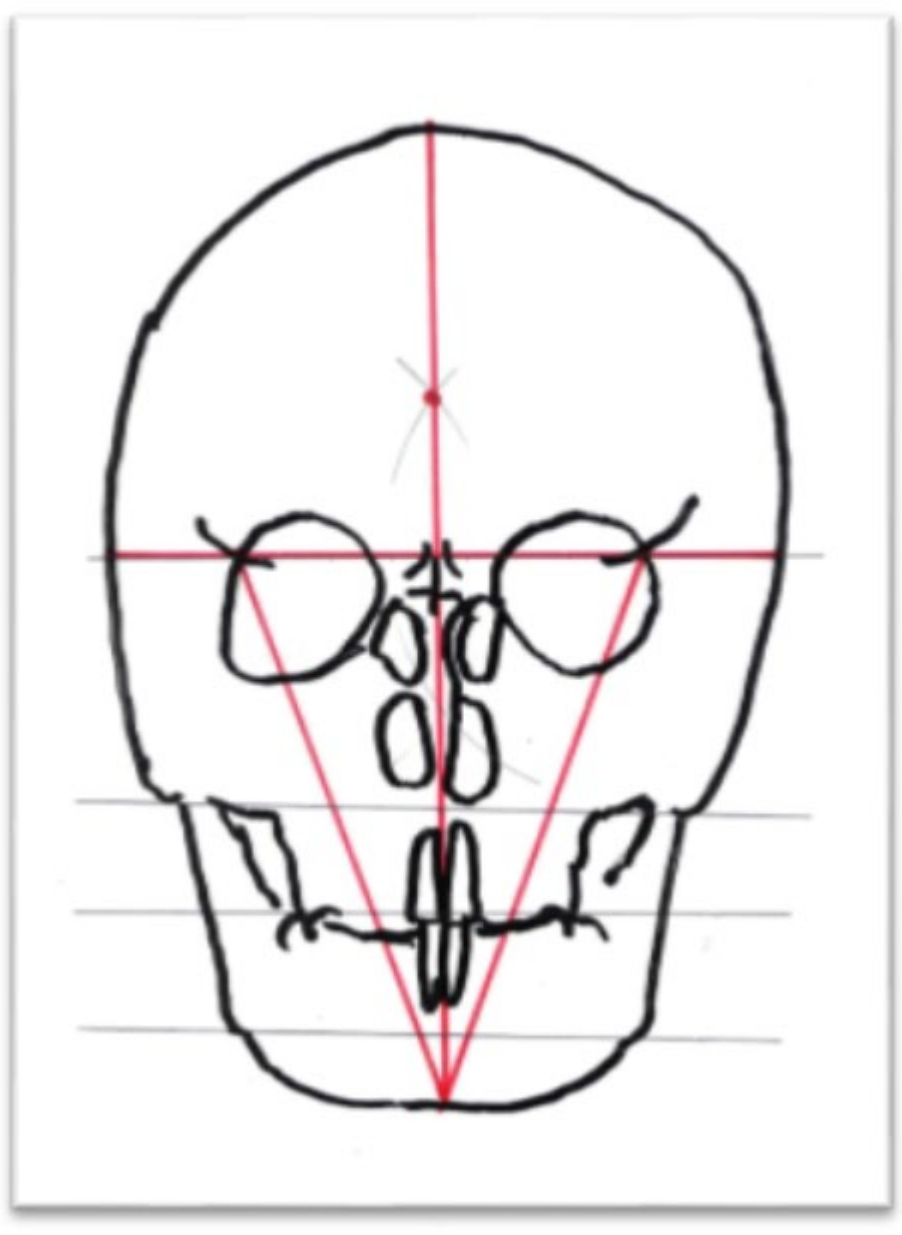




Additional Image: frontal, post-tx



Additional Image: frontal, 4y-6m post-tx



**Commentary on Case and Grading**

It should be noted that the sample case provide here is not a perfect case and only provided as a reference. We encourage you to look carefully at all the sections in the main part of this handbook, use this sample provided as a guideline, and we look forward to your successful completion of your Diplomate of the IBO.

## APPENDIX C: IBO PRACTICE ANALYSIS SUMMARY

This summary of results of the 2013 update to the Practice Analysis Survey is intended for informational purposes to help candidates better understand the development of the IBO Written Examination and how topics on the examination relate to relevant practice areas based on direct feedback from the IBO Diplomates who were surveyed.

### Practice Analysis Survey Results with Added Information from 2013 in Red

*The following survey is designed to identify which orthodontic treatment approaches are used in your office on a regular and ongoing basis. The information gathered from this survey will aid the International Board of Orthodontics in constructing a written exam for the Diplomate credentialing process. It is important that the information you provide is an accurate representation of what you do in your practice.*

*Please complete the survey and return it in the envelope provided. Thank You in advance for providing this information.*

Listed below are several diagnostic tools or processes used by practitioners to diagnose/assess patients. For each of these, please indicate whether you use them frequently, infrequently or not at all in your practice by checking the correct category.

Diagnostic Category	Frequency of Use		
	Frequently	Infrequently	Not at all
Medical History	33-7	0	0
Dental History	33-7	0	0
Clinical Photos	33-7	0	0
Panoramic Radiographs	32-7	0	1
Full Mouth X-ray Films	11-5	15-2	5-0
Cephalometric Analysis	33-7	0	0
Tomograms	2-2	15-3	14-2
Transcranials	5-1	17-2	10-4
Diagnostic Models	33-7	0	0
TMJ Evaluation	31-7	2	0
Airway Evaluation	28-6	4-1	0
Neuromuscular Evaluation	11-5	7-1	3-1
Growth Assessment			
1. Wrist Film	1-0	6-2	20-5
2. Cervical Vertebrae	8-3	4-3	17-1
3. Age and Sex	29-7	1	0
4. Direction of Growth	26-6	5-1	0

5. Racial Characteristics	24-6	4-0	1-1
Added- Soft-Tissue Profile Analysis	6	1	0
Occlusal Analysis	6	1	0

For the treatment approaches identified below, please respond using the same format as in the diagnostic categories above.

Treatment Modality	Frequency of Treatment		
	Frequent	Infrequent	Not at All
<b>Skeletal Cases:</b>			
1. Class I	33-7	0	0
2. Class II	33-7	0	0
3. Class III	21-5	12-2	0
4. Excess Vertical Dimension	18-6	12-1	3
5. Compromised Airway	23-6	9-1	0
<b>Functional Cases:</b>			
1. Primary Dentition	17-7	14	2
2. Mixed Dentition	32-7	1	0
3. Permanent Dentition	26-7	6	1
<b>Surgical Cases:</b>			
1. Tooth removal	0-5	22-2	1
2. Impactions	16-4	17-3	0
3. Orthognathic surgery	3-1	13-5	17-1
4. Implants for anchorage	1-3	10-1	21-3
<b>Limited or Compromised Treatment:</b>			
1. Relapse cases	6-5	27-2	0
2. Habit cases	15-6	18-1	0
3. Minor Tooth movement	15-6	18-1	0
<b>TMD Cases:</b>			
	9-3	10-3	3-1
Added-Partial Adontia	3	4	0
<b>Types of Mechano-Therapy used:</b>			
1. Fixed appliances	33-6	0-1	0
2. Removable appliances	24-5	9-2	0
3. Headgear	5-1	10-2	17-4
4. Facemasks	8-2	17-3	8-2
5. Retention	33-7	0	0
6. Invisalign	4-0	8-4	21-3
7. Air Rotor Reduction	11-3	19-2	2-2
<b>Choices of Fixed Mechano-Therapy:</b>			
1. Edgewise	7-1	4-0	15-6
2. Straightwire	27-6	1-0	4-1
3. Tip-Edge	6-1	2-0	18-6
4. Controlled Arch	8-2	5-1	13-4
5. Ancillary Appliances			
A. Hyrax	14-5	11-1	5-1
B. Herbst	6-1	8-1	15-5
C. Mara	3-2	5-1	20-4

D. Other

19-4

3-0

5-3

Please indicate below the frequency with which you treat patients in the age categories identified below.

Age of Patient Treated:	Frequently	Infrequently	Not At All
1. 3-5	1-2	26-3	5-2
2. 6-10	29-7	4	0
3. 11-18	33-7	0	0
4. 19 plus	27-7	6	0

In the course of providing orthodontic care in your practice, how often do you consult with each of the specialists identified below?

	Frequently	Infrequently	Not At All
1. Speech Therapist	1-0	21-6	11-1
2. Chiropractor	6-0	14-5	13-2
3. Myofunctional Therapist	5-1	15-4	12-2
4. ENT (Otolaryngologist)	11-3	19-4	3-0
<b>Added:</b>			
<b>Surgical</b>			
Implant	4	2	1
Orthopedic	3	1	3
Periodontic	4	2	1

In the box below, please add any diagnostic or treatment approaches you commonly use in the course of treating orthodontic patients in your practice. Please clearly indicate the category to which your comment applies.

#### Additional Diagnostic or Treatment Approaches

These are provided on a separate attachment.

## APPENDIX D: IBO TABLE OF SPECIFICATIONS WORKSHEET

This Table of Specifications Worksheet is intended for informational purposes to help candidates better understand the development of the IBO Written Examination and how topics, represented by item numbers in the table below, relate to relevant knowledge/content areas.

**Table of Specifications Worksheet for IBO  
Diplomate Exam 2013 – Identified by Item Number**

<b>Content Area</b>	<b>Knowledge</b>	<b>Application-Analysis Evaluation</b>
<b>General</b>	<b>29-30-33-39-42</b>	<b>61</b>
<b>Growth &amp; Development</b>	<b>28-29-42-49-58</b>	<b>1-2-10-12-14-15-61-63-74</b>
<b>Bone Physiology</b>	<b>29-38-43-44-57-58</b>	
<b>Patient Management</b>	<b>52-55</b>	<b>23</b>
<b>Occlusion</b>	<b>27-31-46-51-54</b>	<b>18-31-73-83</b>
<b>TMJ</b>	<b>52</b>	<b>45</b>
<b>Neuromuscular</b>	<b>50</b>	
<b>Mechanics</b>	<b>34-35-41-43-44-47</b>	<b>23-32-75-85</b>
<b>Functional Orthopedics</b>	<b>49</b>	<b>4-19-64-65-70-82-87</b>
<b>Content Area</b>	<b>Knowledge</b>	<b>Application-Analysis Evaluation</b>
<b>Stability/Retention</b>	<b>37-42-51</b>	<b>26-87-90</b>
<b>Clinical Records</b>	<b>28</b>	<b>6-8-24-25-53-60-66-67-68-69- 70-71-77-81-82-84-86</b>
<b>Diagnosis</b>	<b>52-53-54-56</b>	<b>1-2-3-5-7-11-12-15-16-21-24-62- 66-67-68-75-76-81-84-85-91-92</b>

<b>Treatment Objectives/Planning</b>	<b>37-48</b>	<b>4-7-10-13-20-21-45-59-64-73-78-85-88-89-93</b>
<b>Treatment Modalities</b>		<b>7-8-9-14-19-22-59-65-89-93</b>
<b>Skeletal Relation</b>	<b>27-48</b>	<b>1-2-3-5-8-9-16-22-77-80-84-92</b>
<b>Dental Relation</b>	<b>27</b>	<b>16-18-66-83</b>
<b>Functional and Parafunctional TX</b>	<b>55-71-76</b>	<b>17</b>
<b>Special/Limited Cases</b>	<b>33-38-39</b>	

**Note: Items are found under multiple categories as the distinctions associated with treatment are not always clearly separate.**



*Page intentionally left blank / Spacer*