

# **IBO Diplomate Examination Candidate Handbook**

---

## Table of Contents

### Introduction

About the IBO \_\_\_\_\_ Page 1

### About the Examination

Description of the Diplomate Exam and Exam Components \_\_\_\_\_ Page 1

Eligibility Requirements \_\_\_\_\_ Page 2

Application Process \_\_\_\_\_ Page 2

Examination Schedule and Application Status \_\_\_\_\_ Page 3

Application Fees \_\_\_\_\_ Page 3

Written Examination \_\_\_\_\_ Page 4

Clinical Examination \_\_\_\_\_ Page 7

Diplomate Notebook Template \_\_\_\_\_ Page 20

IBO Policies \_\_\_\_\_ Page 49

Confidentiality \_\_\_\_\_ Page 49

Disciplinary Action \_\_\_\_\_ Page 49

Appeals \_\_\_\_\_ Page 52

Ethical and Professional Conduct \_\_\_\_\_ Page 52

Recertification \_\_\_\_\_ Page 53

### Appendices:

Appendix A: Application Forms \_\_\_\_\_ Page 55

Appendix B: Sample Diplomate Case \_\_\_\_\_ Page 59

Appendix C: IBO Practice Analysis Summary \_\_\_\_\_ Page 88

Appendix D: IBO Table of Specifications Worksheet \_\_\_\_\_ Page 92

## **INTRODUCTION**

The International Board of Orthodontics (IBO) is the official certifying body of the International Association for Orthodontics (IAO) and consists of eight (8) Diplomate Members nominated by the IBO Board and confirmed by the IAO Executive Committee.

### *IBO Mission Statement*

To elevate Functional Jaw Orthopedics and Orthodontics to the highest standards of clinical excellence as provided by IAO members and to support IAO members in their Tier Advancement to Diplomate status.

### *Who Should Take the Diplomate Examination?*

The IBO is the final level of the IAO Tier Advancement Program. Members of the IAO, primarily licensed general and pediatric dentists who provide orthodontic treatment for their patients, and who have chosen to participate in the IAO Tier Advancement Program may choose to complete the Tier Advancement program by obtaining Diplomate Status.

The purpose of this manual is to provide clear and simple directions to all Diplomate candidates in their preparation for the Written and Clinical Case Examinations that comprise the Diplomate Examination.

## **ABOUT THE EXAMINATION**

The International Association for Orthodontics (IAO) conducts a multi-step credentialing process that assures that the individuals who qualify for Diplomate status are credible practitioners of orthodontics. The written aspect of this examination is designed to provide a reliable and a valid measure of several key knowledge areas that are related to effective orthodontic care. These areas include the following primary content domains:

- I. The underlying biomedical and clinical foundation knowledge that supports orthodontic treatment.
- II. Knowledge of the diagnostic procedures that are commonly used to assess a patient's orthodontic needs.
- III. The ability to apply diagnostic procedures to a case example including knowledge and interpretation of various diagnostic tests.
- IV. Analysis of treatment planning decisions for a variety of orthodontic cases such that the candidate may design an appropriate treatment plan or recognize deficiencies in treatment planning of existing cases.
- V. Analysis of that information which is used to facilitate diagnosis of problems with the temporomandibular joint and to design and manage treatment of those problems.

This written examination therefore provides baseline evidence of competency for the credentialing of IAO members. It is followed with evidence of effective case treatment through presentation of 10 clinical cases which demonstrate the candidates diagnostic and treatment planning skills. The process as a whole demonstrates that an individual with a Diplomate credential has both the underlying knowledge and practice capacity necessary for such recognition.

### **CANDIDATE ELIGIBILITY**

To be eligible to apply for Diplomate, an IAO Member in good-standing must have completed and submitted 500 hours of orthodontic CE to IAO Headquarters and have achieved IAO Fellow Status. Finally, a candidate must present ten (10) orthodontic finished cases that he or she treated, five (5) of which must have two (2) years post-treatment records.

#### **Orthodontists**

Specialists, who are IAO Members and seek Diplomate status are welcome to apply according to the following requirements.

##### *Board Certified Orthodontists*

An orthodontist who is an IAO Member in good standing and who has passed the boards successfully in their respective country is welcome to apply for the IBO Diplomate recognition without having to present the usual case and written examination requirements. The orthodontist must present a copy of their orthodontic certificate and board certificate with a completed specialist application for International Association for Orthodontics (IAO) Tier Advancement Diplomate recognition. The orthodontist applying for IBO Diplomate Status will be asked to publish an article in the International Association for Orthodontics' International Journal of Orthodontics. The orthodontist must present at least one (1) case at the IAO Annual Meeting.

##### *Non-Board Certified Orthodontists*

Orthodontists who are not board certified in their country of practice must meet the same requirements for obtaining the IBO Diplomate status as outlined for any other IAO Member.

### **APPLICATION PROCESS**

Candidates must apply to take the IBO Diplomate Examination no later than 30 days in advance of the next examination date. The application forms for both IAO Members and Specialist Members are available in appendix A of the Candidate Handbook. The applications are also

available upon request from IAO Headquarters and for download online at [www.iaortho.org/diplomate](http://www.iaortho.org/diplomate). Completed applications should be returned along with the required application fee and a current photo to [worldheadquarters@iaortho.org](mailto:worldheadquarters@iaortho.org) or by post to:

Attn: Jenn Baker-Batterman  
IAO Headquarters  
750 N. Lincoln Memorial Drive  
Suite 422  
Milwaukee, WI 53202 USA

### **Examination Schedule and Application Status**

The IBO Diplomate Examination is conducted each year at the IAO Annual Meeting which is held in late March/early April in the United States. For more information on the next examination date, please contact IAO Headquarters. Candidates must pass the IBO Written Examination prior to taking the IBO Clinical Case Examination. Both exams may be taken during the same Annual Meeting or they may be taken at separate meetings. Under certain circumstances, special accommodation has been made to have IBO Clinical Cases reviewed at another time and location from the Annual Meeting, but this is subject to availability of reviewers. Should you wish to request a special review of IBO Clinical Cases outside of the Annual Meeting, please contact IAO Headquarters.

After submitting a completed application candidates will receive confirmation from the IAO Headquarters that the application has been received. Prior to the Annual Meeting all candidates will be notified of the time and location of their examination.

### **Application Fees**

Application fees are the following:

- IBO Written Examination and IBO Clinical Case Examination (US \$500.00)
- IBO Written Examination ONLY (US \$100.00)
- IBO Clinical Case Examination ONLY (US \$400.00)\*
- IBO Diplomate Application for Specialists (US \$500.00)

*\*Candidates must have passed the IBO Written Examination prior to taking the IBO Clinical Case Examination.*

## **IBO WRITTEN EXAMINATION**

The first phase of the IBO Diplomate Examination is the IBO Written Examination. Every IBO Diplomate candidate must pass this examination on general orthodontic knowledge. This test can be taken after having achieved IAO Fellow status and attaining 300 hours of approved CE in Orthodontics. Once a candidate achieves a passing score of 70%, this test result remains valid for five (5) years towards your fulfilling the Diplomate requirements.

### **IBO Written Examination Development**

The IBO Written Examination was developed by identifying key knowledge areas necessary for a general dental practitioner to have for them to provide effective orthodontic care. These knowledge areas were further expanded to include specific practice areas and techniques reported to be relevant to orthodontic treatment on a Practice Analysis Survey. The survey was distributed to approximately 50 current IBO Diplomates.

### **IBO Practice Analysis**

The IBO Practice Analysis Survey results are included as Appendix C in the Candidate Handbook. The Survey Results are also published as a separate document available for download on the IAO website.

### **IBO Written Examination Knowledge Domains**

The IBO Written Examination evaluates the following knowledge domains:

- Underlying Science
  - Biological Foundation
  - Growth and Development
  - Fixed Orthodontic Mechanics
- Diagnostic Procedures
  - Diagnostic Methods
  - Airway Considerations
- Treatment Planning and Outcomes
  - Functional Orthopedics
  - Finishing Procedures
  - Retention

### **IBO Written Examination Reading List**

To aid in preparation for the IBO Written Examination, the IBO recommends all candidates study the following literature.

1. Contemporary Orthodontics (4<sup>th</sup> edition) – Proffit, et al
2. Orthodontic and Orthopedic Treatment - McNamara & Brudon
3. Clinical Management of Basic Maxillofacial Appliances –Vol. 1,2,3 Witzig/Spahl
4. Guide to the differential Straight-Arch Technique 5<sup>th</sup> edition -Peter Kesling
5. Biomechanics and Esthetic Strategies in Clinical Orthodontics -R. Nanda
6. Straightwire – McLaughlin & Bennett
7. Begg Orthodontic Theory and Technique - edited by Peter Kesling
8. Orthodontics, Current Principles & Techniques -Graber, Vanarsdall, Vig
9. Essentials of Facial Growth – Enlow and Hans

### **IBO Written Examination Sample Questions**

The IBO Written Examination may contain several different types of multiple choice questions including, but not limited to, case-based questions, paired true/false questions, Exception Item questions, and stand-alone questions. The following are sample questions that will help you become familiar with the types of questions included on the IBO Written Examination.

#### **1. Case-based questions**

For case-based questions, you will be given Cephalometric measurements, photos, models and other records

Sample Question 1 - Review of the patient's records depicts a profile that would benefit from which of the following outcomes?

- A. Deepen bite
- B. Additional lip support
- C. No modification of the esthetic plane
- D. Intrusion of maxillary incisors

#### **2. Paired True/False questions**

Sample Question 2 - The measurement, lower incisor to A-Pog indicates the need to extract in this case. The patient's soft tissue profile indicates the need to extract teeth.

- A. Both statements are true
- B. Both statements are false
- C. The first statement is true, the second false
- D. The first statement is false, the second true

#### **3. Exception item questions**

Sample Question 3 - All of the factors below would affect head posture EXCEPT one? Which is

that EXCEPTION?

- A. Maxillary frenum impingement
- B. Enlarged adenoidal tissue
- C. Deviated nasal septum
- D. Maxillary retention cyst – maxillary right sinus

**4. Stand-alone questions**

Sample Question 4 - In a mixed dentition case with a retrognathic mandible and a Class II dental relation. Which of the following radiographs allows you to assess the direction of growth?

- A. Panoramic
- B. Occlusal
- C. Bite-wing
- D. Cephalometric\*
- E. Wrist

## **CLINICAL CASE EXAMINATION**

The IBO has developed the current IBO Clinical Case Examination to ensure that all Diplomate clinical case evaluations are scored objectively and anonymously according to standardized set of evaluation criteria. A standardized case presentation format is provided as a model to all candidates when organizing and presenting cases, and will be explored in this section of the Candidate Handbook.

### *Evaluation Criteria and Scoring*

Based on the standardized case presentation format, a revised set of evaluation criteria was developed and is employed and applied to all clinical evaluations. All cases are scored out of a total of 100 points, with 100 being a perfect score. The scoring system is also explored in greater detail in this section of the Candidate Handbook.

### *Calibration of Examiners*

Diplomate is the culmination of the IAO Tier Advancement Program and is immediately preceded by Fellow Status, which also requires case presentations. To ensure consistency in scoring between IBO Examiners and the IAO Education Committee Case Examiners that score Fellow cases, a system of calibration has been developed. Calibration is intended to yield consistent reliable evaluation results among all case examiners, while at the same time reducing the risk of bias in scoring.

In calibration, a “Diplomate-quality” case is presented to the group. Each examiner grades the case according to the standardized set of criteria used for case evaluation. After grading, each examiner reveals their score for the case and any discrepancies in scoring are discussed in the group setting. Finally the group arrives at a consensus for the score of the case to provide examiners with a baseline for the scoring of future cases. IBO Examiners are calibrated once a year and IAO Education Committee Examiners are calibrated on a rotating cycle, with at least half the Examiners calibrated once a year, so that the full group of IAO Education Committee Examiners is calibrated every two years.

The following section will explore the structure and content of a successful clinical case presentation, as well as the criteria used to score each case, to help candidates better understand the expectations for a successful case presentation.

## **DIPLOMATE CASE EVALUATION**

At this juncture, it is important to emphasize that all cases presented for the IBO Diplomate clinical examination MUST have at a minimum the following pre-treatment and post-treatment orthodontic records:

1. Cephalometric radiographs (traced using the IBO cephalometric analysis)
2. Panoramic radiographs (or FMX),
3. Soaped or digital models
4. Photographs (intraoral and extraoral). Cases lacking any of the above will NOT be evaluated.

As of April 20<sup>th</sup>, 2012, the IBO approved a change in the number of required cases for the IBO Diplomate Clinical Case Examination from at least fifteen (15) cases to at least ten (10) cases; The reason for this change was recognition that modern testing methodology suggests in an examination determining high skill, such as the IBO Diplomate, ten (10) tests of proficiency are sufficient to determine this level of skill. Of the required ten (10) cases, five (5) must have two(2) years post-treatment orthodontic records. The remaining five (5) cases may be “recently” finished, meaning presenting less than two (2) two years post-treatment. Currently, the IBO encourages a variety of skeletal types in the mix of cases presented. It is strongly advised that candidates prepare IBO Board Cases for presentation by following the format presented in the Diplomate "Sample Case" (Appendix A) to ensure IBO Examiners are able to effectively review the cases.

The following is the current IBO approved case scoring sheet. This is a copy of the actual sheet used by all examiners in the evaluation of the diplomate clinical case presentations. It should be clear that it is patterned to follow the actual case presentation write-up. One important item to note is the number of points awarded to each section. All sections should be completed as thoroughly as possible, with no areas left incomplete which would result in a point deduction.

**IBO Case Presentation Scoring Sheet**

Candidate/Case Number: **\_(strict anonymity)**\_\_\_\_\_

Title Page \_\_\_\_\_

Table of Contents \_\_\_\_\_

Section One: *Problem List- 2 Points(list brief comments)* \_\_\_\_\_

Skeletal Features \_\_\_\_\_

Dental Features \_\_\_\_\_

Soft Tissue Features \_\_\_\_\_

Occlusion \_\_\_\_\_

Habits \_\_\_\_\_

Other \_\_\_\_\_

Chief Complaint \_\_\_\_\_

Pt Expectations \_\_\_\_\_

Section Two: *History- 1 Point (brief relevant comment)* \_\_\_\_\_

Med Hx \_\_\_\_\_

Dent Hx \_\_\_\_\_

**Section Three: Cephalometric Quality-2 Points** \_\_\_\_\_

Cephalogram Quality \_\_\_\_\_

All Hard Tissue Visible \_\_\_\_\_

All Soft Tissue Visible \_\_\_\_\_

**\*\*\*this section awards points based on the "quality" of the cephalogram\*\*\***

**Section Four: Other Radiographs- 1 Point** \_\_\_\_\_

Pan &/or FMX \_\_\_\_\_

TC &/or Tomogram if needed \_\_\_\_\_

Other (MRI, Occlusal xray, photo tracing, etc) \_\_\_\_\_

**\*\*\*this section awards points based on the "quality" of the panoramic or "other" radiographs\*\*\***

**Section Five: Photographic Quality-2 Points** \_\_\_\_\_

Extra-oral \_\_\_\_\_

Intra-oral \_\_\_\_\_

**\*\*\*this section awards points based on the "quality" of your photographs\*\*\***

**Section Six: Study Models- 2 points** \_\_\_\_\_

Pre-treatment \_\_\_\_\_

Post-treatment \_\_\_\_\_

2 year Post-treatment \_\_\_\_\_

**\*\*\*this section awards points based on the “quality” of your soaped models\*\*\*  
 (Up to this stage there have been a total of 10 possible points that can be awarded)**

**Section Seven: Ceph Tracings, IBO Summary and Diagnosis- 30 Points** \_\_\_\_\_

- Cephalometric Tracings (10 points): \_\_\_\_\_  
     Are the points located correctly?
- IBO Summary (each 2 points):
  - 1) Growth: Stage and Direction: \_\_\_\_\_
  - 2) Skeletal/Vertical Analysis: \_\_\_\_\_
  - 3) Skeletal/Sagittal Analysis: \_\_\_\_\_
  - 4) Dental Relations: \_\_\_\_\_
  - 5) Soft Tissue Profile: \_\_\_\_\_
- Diagnosis/case analysis (10 points): \_\_\_\_\_

\*\*\*This section will award points on the basis of **three** areas: 1) Quality cephalometric tracings, 2) A **complete** IBO Cephalometric Summary and relevant comments in **all** five areas and 3) A thorough complete case diagnosis that incorporates all aspects of the case evaluation\*\*\*

**IBO CEPHALOMETRIC SUMMARY**

1. Analysis of Growth	Pre	Post	+2yr
<b>a. CVM Stage of Growth</b>			
Stage I ( no cupping)	_____	_____	_____
Stage II (cupping of II)	_____	_____	_____
Stage III (cupping of III)	_____	_____	_____
Stage IV (cupping of IV)	_____	_____	_____
Stage V (cupping of V & VI)	_____	_____	_____
Stage VI(deepened cupping in all)	_____	_____	_____
<b>b. Direction of Growth</b>			
Y Axis to SN	66 +/-2	_____	_____
Y Axis to FH	59 +/-2	_____	_____

**2. Analysis of Airways**

a. Upper-Nasopharynx		8-18	_____	_____	_____
b. Lower-Oropharynx		10-12	_____	_____	_____
<b>3. Analysis of Skeletal Vertical</b>					
a. FMA		25 +/-4	_____	_____	_____
b. ALFH (ANS-Mn)		58-72	_____	_____	_____
c. UFH/LFH	50/50 C	45/55 A	_____	_____	_____
d. SN-GoGn		32 +/-3	_____	_____	_____
<b>4. Analysis of Skeletal Sagittal</b>					
a. Condylion to A pt			_____	_____	_____
b. Condylion to Gn			_____	_____	_____
c. Difference	6=17;9=20;12=23;14=25;16=27		_____	_____	_____
	Class I, II, III		_____	_____	_____
d. Wits: Class I = -2 to +2, Class II ≥ +3, Class III ≤ -3			_____	_____	
e. ANB: Class I = 0- 4, Class II ≥ 5, Class III ≤ -1			_____	_____	_____
<b>5. Analysis of Dento-Alveolar Relations</b>					
a. IMPA		90 +/-5	_____	_____	_____
b. 1/1		131 +/-4	_____	_____	_____
c. 1/SN		103 +/-2	_____	_____	_____
d. /1 to APg		-1 to 3mm		_____	_____
<b>6. Analysis of Soft Tissue</b>					
a. Esthetic Line (nose tip to soft tissue Pg)		+/- 2mm	_____	_____	_____
b. Naso-Labial Angle		96-118	_____	_____	_____
c. Lip Competence (Yes or No)			_____	_____	_____

**\*\*\*The IBO summary needs to be filled in with the relevant measurements\*\*\***

**Section Eight: Tx Plan- 10 Points (each area 2 pts)**

Treatment objectives \_\_\_\_\_

Treatment Plan \_\_\_\_\_

Limitations \_\_\_\_\_

Mechano-therapy \_\_\_\_\_

Evaluation of Tx progress \_\_\_\_\_

**\*\*\* This section requires a description of all five aspects of the treatment in order to receive points for each section\*\*\*\***

**Section Nine: Results- 40 Points (each area 4 pts) \_\_\_\_\_**

OJ/OB \_\_\_\_\_

Cuspid/Molar \_\_\_\_\_

Plane of Occlusion \_\_\_\_\_

7's in occlusion \_\_\_\_\_

Marginal Ridges \_\_\_\_\_

No Rotations \_\_\_\_\_

Spaces Closed \_\_\_\_\_

Soft Tissue (Intraoral) \_\_\_\_\_

Root Parallelism \_\_\_\_\_

Facial & Dental Midlines \_\_\_\_\_

**\*\*\*This section will be evaluated using photographs, models and panoramic radiographs\*\*\***

**Section Ten: Case Analysis-10 Points (2 pts each area) \_\_\_\_\_**

Facial Esthetics \_\_\_\_\_

Skeletal/Dental \_\_\_\_\_

**Superimpositions** \_\_\_\_\_

**Difficulty of Case** \_\_\_\_\_

**Tx Objectives Achieved or Not Achieved** \_\_\_\_\_

**\*\*\*This section will evaluate your finished "case analysis" include aspects that relate the case, from finished esthetic results, skeletal and dental goals, relate the superimpositions to the case pre-tx and post-tx, assess the case in degree of difficulty and finally was the objective of treatment achieved\*\*\***

**TOTAL POINTS.....** \_\_\_\_\_

**Examiner** \_\_\_\_\_ **Date:** \_\_\_\_\_

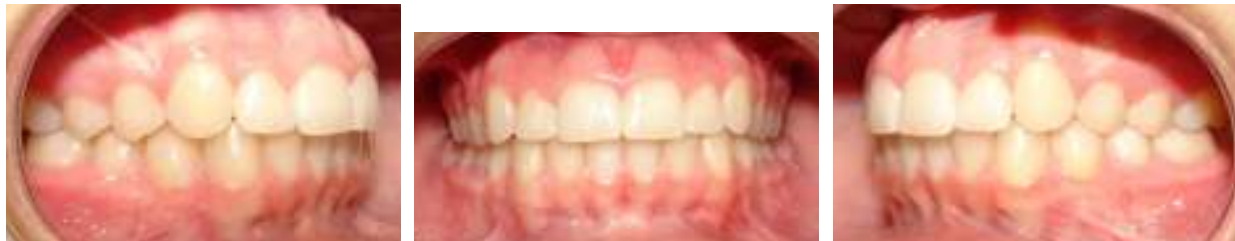You can clearly see that both Section VII (30 points) and Section IX (40 points) of a case presented are the categories that carry the most point potential (70 possible points). The IBO has developed specific criteria that are used in the evaluation of the Section IX criteria.

- Acceptable Overbite/ Overjet?
- Class I molar/canine function?
- Flat plane of occlusion?
- 2nd molars in occlusion?
- Marginal height discrepancies?
- Rotations?
- Spaces?
- Root parallelism?
- Intraoral soft tissue considerations?
- Facial and dental midlines?

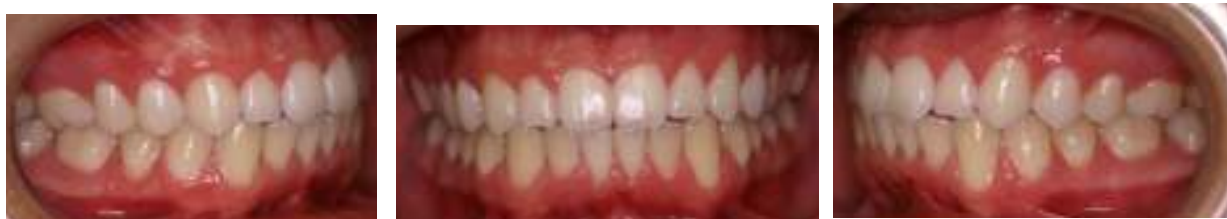## Review Criteria in Detail

We will now go over each criterion in more in detail and more clearly describe how each is graded and measured.

**OVERBITE/OVERJET:** The IBO standard accepted range is 1-3mm in either for there to be NO deductions; the **overjet** will be measured from the labial surface of the lower central incisor to the lingual incisal edge of the upper central incisor. The **overbite** will be measured from the incisal edge of the lower central incisor to the incisal edge of the upper incisor when models are in maximum intercuspation (MI); the simplest way to arrive at this is to place models in MI then carefully with a fine pencil tip mark a horizontal line across the upper incisor edge drawing onto the lower labial surface-then measure from the lower incisal edge to this line. Any deviation from that range, such as 4mm of overbite and/or overjet will incur a 2 point deduction. Conversely, a zero overbite/overjet will incur a 2 point deduction. In this section the MAXIMUM combined point deduction will be 4 points.



(These photos demonstrate acceptable overjet/overbite, Class I canine and molar relation)



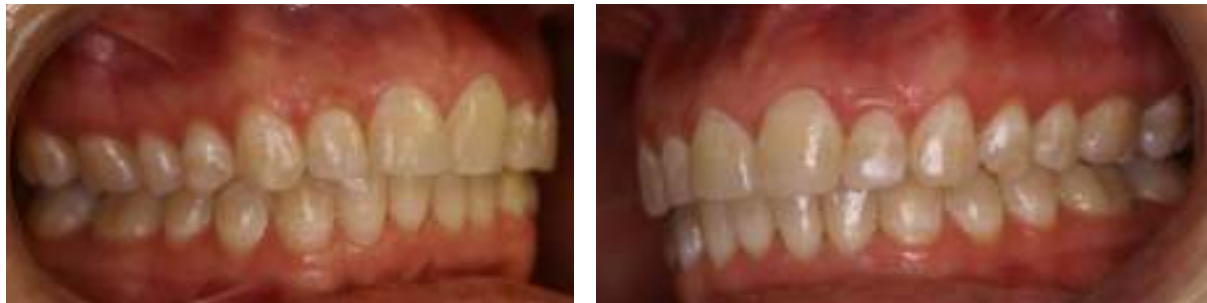(These photos demonstrate Unacceptable overjet/overbite, yet acceptable Class I canine and molar relation; this case would incur full 4 point deduction in the OB/OJ area)

**CLASS I MOLAR/CANINE RELATION:** Class I molar relation is considered ideal when the maxillary first molar mesial buccal cusp intimately intercuspates into the buccal groove of the lower first molar. A Class I cuspid relation is described as when the canine tip fits intimately between the distal incisal edge of the lower canine and the mesial surface of the buccal cusp of the lower first bicuspid. The IBO standard accepted range for either is 1mm in EITHER direction; that is the molars or canines can be 1mm in either the Class II or III direction to incur NO deductions. Any further deviation per 1mm in either direction by either canines or molars will

incur a 1 point deduction per tooth; the maximum total deductions will also be 4 points in this category.

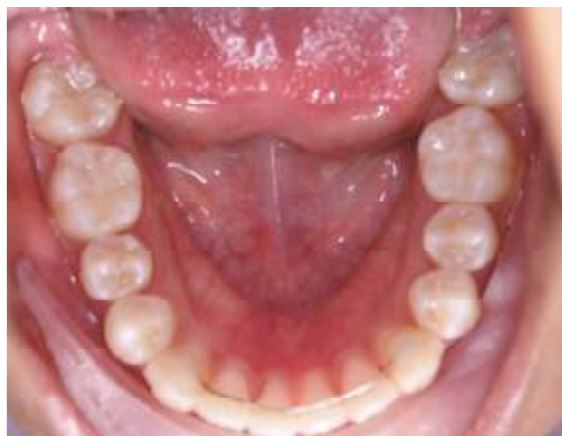**PLANE OF OCCLUSION (Curve of Spee):** The IBO accepted standard is a plane of occlusion that when measured from second molars to canines with a flat instrument (both right and left sides independently), at its DEEPEST point will be 0-2 mm to incur NO deductions. Any deviation per 1mm will incur a 1 point deduction per side to a maximum of 4 points in this category.

**SECOND MOLARS IN OCCLUSION:** The IBO considers the second molar occlusion important. The cases that have been recently evaluated have demonstrated that more often than not, the second molars are in INCOMPLETE occlusion. Therefore, any measurable disclusion in mm from the lingual cusp tip to the depth of the central fossa will incur a corresponding 1mm deduction per 1mm of disclusion; once again to a maximum of 4 points in this area.



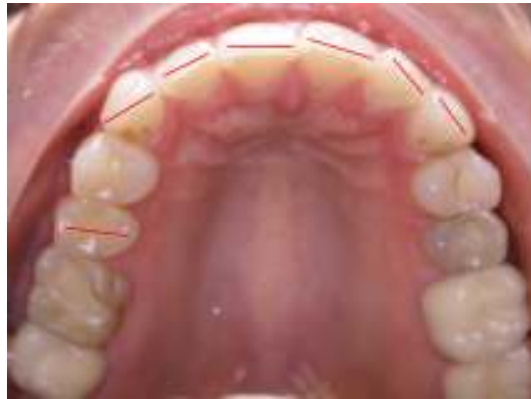(The photos demonstrate acceptable second molar occlusion)

**MARGINAL RIDGES:** The IBO standard is LEVEL marginal ridges up to 1mm to incur NO deductions. Any marginal height discrepancies beyond 1mm will incur a 1 point deduction per tooth, up to a maximum 4 points in this section. (Common areas of marginal ridge discrepancies are found in both upper and lower 6-7, 4-5 areas.)



(This lower arch demonstrates marginal ridge discrepancies between the 6-7 areas as well as unacceptable mesio-rotations of the L6's)

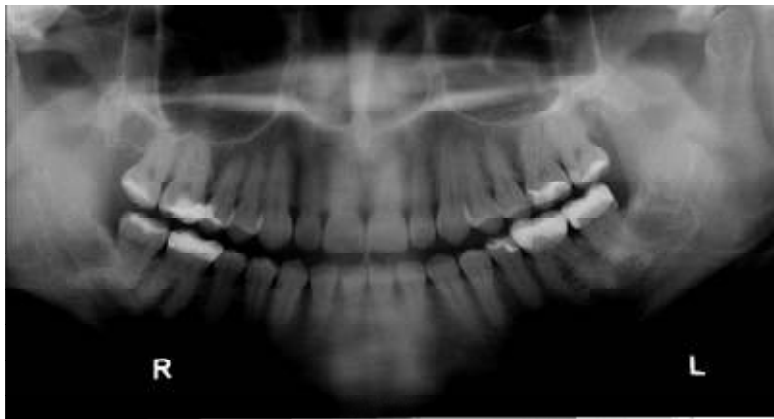**ROTATIONS:** The IBO considers as acceptable that all teeth be aligned along the long axis and centered bucolingually; this position will be referred to as ZERO degrees. Any deviation of 15 degrees in either distal or mesial direction will incur a 1 point deduction (per tooth), a 30 degree rotation will incur a 2 point deduction (per tooth), and a 45 degree rotation will incur a 4 point deduction. This section will also have a maximum 4 point deduction.



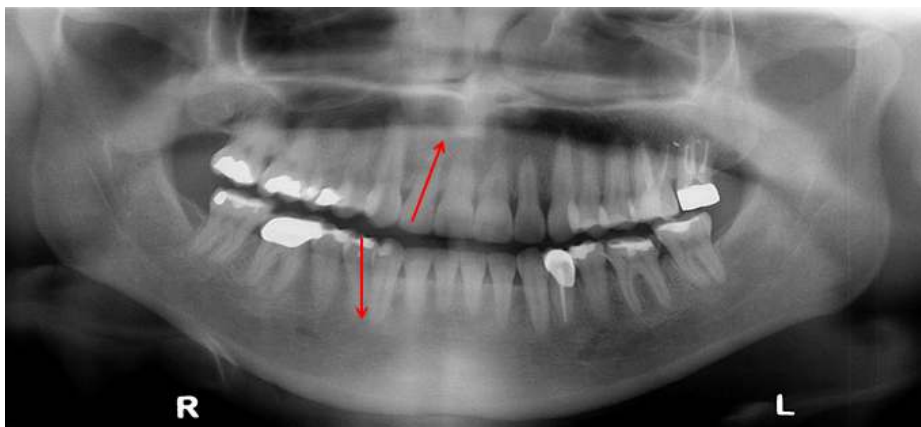(This arch demonstrates several teeth with varying degrees of rotations-this case would incur the maximum deduction of 4 points in this section.)

**SPACES:** The IBO standard is NO spaces. Any measurable space of 1mm or more will incur a corresponding 1 point deduction or more depending on the measured space. Once again this will have a maximum 4 point deduction in this category.

**ROOT PARALLELISM:** This section will be evaluated on the basis of the panoramic radiograph; the IBO recognizes the limitations of this method to clearly evaluate root alignment in the upper canine/first bicuspid and the lower canine/lateral areas. The IBO standard is parallel roots with a slight distal angulation. Any tooth which deviates from this parallel relation will incur a 1 point deduction per tooth (except the above mentioned areas); any area where there is root contact will incur a 2 point deduction to a maximum 4 point deduction in this section.

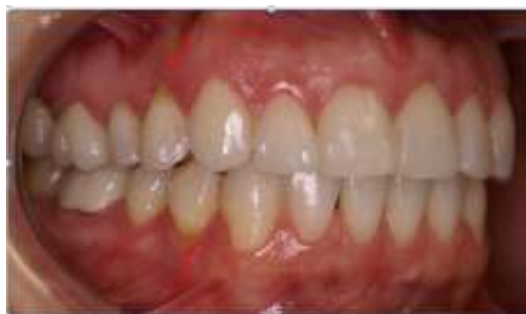

(The above panoramic radiograph demonstrates acceptable root angulation even when both the upper canine and upper first bicuspid roots appear to be in contact.)



Root angulation problems UR2 and LR4

**INTRAORAL SOFT TISSUE:** This section will be evaluated using soaped models and photographs. The IBO considers intraoral tissue to be in health when there is **NO** evidence of **POST** treatment soft tissue dehiscences (recession) anywhere. Any tooth that demonstrates a post-treatment soft tissue recession will be deducted 1 point per 1mm per area to a maximum of 4 points in this section.



**FACIAL AND DENTAL MIDLINES:** The IBO considers it a worthy treatment goal to end with both skeletal and dental midlines to be coincident; pre-treatment conditions and age of patient will be considered when evaluating skeletal midline evaluation. The IBO dental midline standard is 0-1mm in either direction to incur NO deductions. Any additional increase in deviation will incur a 1 point deduction per area to a maximum of 4 point deduction in this section.



(Based on the above photos this patient appears to have both upper dental midline deviated to the right side ~1-2mm, as well the lower dental midline deviated to the right 4-5 mm; significant skeletal midline deviation and cant to the right side- this would not be an acceptable diplomate case)

Following is the case presentation format that the IBO requires for all cases presented. There is basic information presented in each section in **red** and is meant to help clarify what is expected to be included. There is also information below each cephalometric measurement section to help familiarize the candidate with the IBO cephalometric analysis. Please try to understand that these measurements are not intended to suggest that this is the only or best way to evaluate a case, but is the consensus result of expert opinions within our present and past boards.

# **THE INTERNATIONAL BOARD OF ORTHODONTICS**

**DIPLOMATE CASE PRESENTATION  
NOTEBOOK  
TEMPLATE**

## IBO TEMPLATE SECTIONS

---

---

- **THE TITLE PAGE**
- **TABLE OF CONTENTS**
- **SECTION ONE: Comprehensive description of the Dentition, Chief Complaint and Patient Expectations**
- **SECTION TWO: Pertinent Medical and Dental History**
- **SECTION THREE: Cephalometric Radiographs**
- **SECTION FOUR: Panoramic, Full Mouth Series, Transcranial or Tomographic radiographs , other radiographs or records**
- **SECTION FIVE: Patient Photographs**
- **SECTION SIX: Study Models**
- **SECTION SEVEN: Analysis of Cephalometric Radiographs and Diagnosis**
- **SECTION EIGHT: Treatment Objectives, Treatment Planning and Treatment Modalities**
- **SECTION NINE: Case Finishing and Treatment Results**

- **SECTION TEN:** Discussion of the Case

**IBO CASE I.D. JJ 83-103**  
**AGE; 12 years, 3 months**  
**June 17, 1983 (case ID, age)**

**THE FUNCTIONAL AND FIXED ORTHODONTIC  
TREATMENT OF THIS CLASS II DIVISION 2 PATIENT (fill in  
the type of case presented)**  
**IS PRESENTED IN PARTIAL  
FULFILLMENT OF THE CLINICAL DIPLOMATE  
REQUIREMENTS OF THE INTERNATIONAL BOARD OF  
ORTHODONTICS**

**DOCTOR I.D. CODE: BR548 (fill in your code)**

## TABLE OF CONTENTS

<b>Section I:</b> Comprehensive Description of the Dentition, Chief Complaint and Patient Expectations .....	Page X
<b>Section II:</b> Pertinent Medical and Dental History .....	Page X
<b>Section III:</b> Cephalometric Radiographs and Hand Tracings .....	Page X
<b>Section IV:</b> Panoramic, Full Mouth Series, Transcranial or Tomographic Radiographs .....	Page X
<b>Section V:</b> Patient Photographs .....	Page X
<b>Section VI:</b> Study Models .....	Page X
<b>Section VII:</b> Analysis of Cephalometric Radiographs and Diagnosis .....	Page X
<b>Section VIII:</b> Treatment Objectives, Treatment Planning and Treatment Modalities .....	Page X
<b>Section IX:</b> Case Finishing and Treatment Results .....	Page X
<b>Section X:</b> Discussion of the Case .....	Page X

**Section I: Comprehensive Description of the Dentition, Chief Complaint and Patient Expectations**

**CLINICAL EVALUATION:**

Soft Tissue Evaluation:

- Facial type –
- Facial symmetry –
- Profile –
- Nose –
- Nasolabial angle –
- Lips –
- Smile line –
- Gingival Display –
- Tonsillar tissue –

Soft Tissue Evaluation (cont.)

- Mentolabial sulcus –
- Soft tissue chin –
- Other-

Skeletal Evaluation:

- Maxilla –
- Mandible –
- Facial height-
- Palate –
- Skeletal midlines –
- Genetic conditions –
- Radiographic findings-

- Bony chin-

Dental Evaluation:

- Dental classification –
- Midlines –

Dental Evaluation (cont.):

- Overbite/overjet –
- Open bite –
- Closed bite –
- Cross bite –
- Model analysis-
- Arch shapes –
- Arch length –
- Caries Index –
- Radiographic findings-

Functional Evaluation: TMJ? Occlusion?

Special Considerations:

Patient's Chief Complaint:

Patient's Expectations:

## **Section II: Pertinent Medical and Dental History**

(This document contains suggestions in hidden text. To view hidden text, on the Tools menu click Options. On the View tab, check Hidden text in the Formatting marks section. Hidden text appears in red and will not print. Make sure you enter your evaluations next to the black type, not in the hidden text areas. **Please remove this paragraph before printing your document.**)

Medical History:

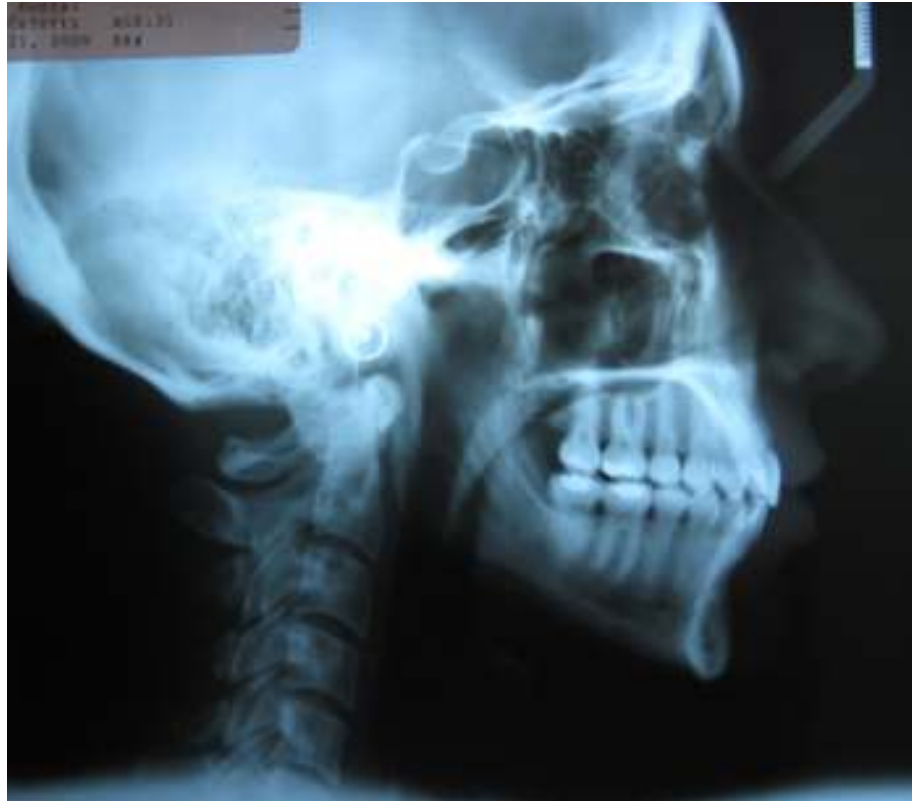Dental History:

## **Section III: Cephalometric Radiographs and Tracings**

(All cases presented must have Pre-treatment, Post-treatment and when necessary Two or more years Post-treatment cephalometric radiographs and manual tracings preferred)

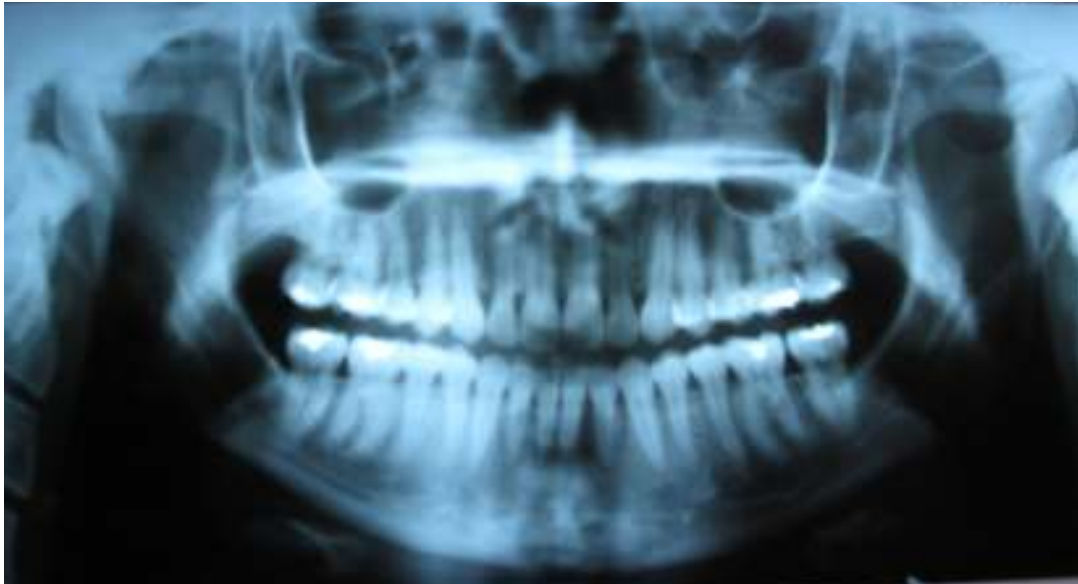
ALL of the following can be clearly seen on the exposed radiographs:

- A. Anatomic hard tissue landmarks
- B. Soft tissue landmarks
- C. Tracing
- D. These cephalometric radiographs and tracings should be mounted and identified by date on separate pages for pre-treatment, post-treatment and when needed two or more years post-treatment.



#### Section IV: Panoramic or Full Mouth Series Radiographs

- A. Cases need to have at least a panoramic or full mouth series; these should be mounted and identified by date on separate pages. Either radiographs need to be pre-treatment, post-treatment and when necessary 2 or more years post-treatment. Remove paragraph prior to printing this page.**
1. Panoramic radiograph - Anatomic hard and soft tissue landmarks clearly visible
  2. Full Mouth series – Anatomic hard tissue landmarks clearly visible including all periapical areas (if used)
  3. Occlusal Radiographs
  4. Any other pertinent diagnostic images



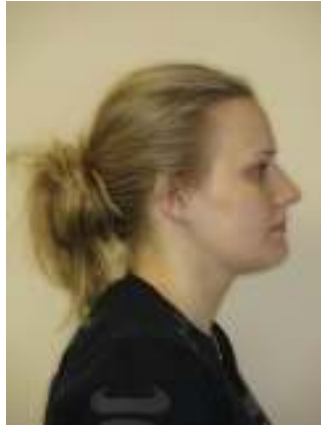#### Section V: Patient Photographs:

- A. Intra and extra-oral photographs should be arranged in the format seen in the example below; the minimum requirement is (9) photographs:
- B. THREE extra-oral Photos: Should be 3 x 5 in size and arranged on a separate page. The background must be free of distractions and the patient must have their eyes open and looking straight ahead without glasses. The photographs are: 1) Frontal view non-smiling lips at repose, 2) Frontal view smiling, 3) Right profile view of face lips in repose (all facial photos should include the shoulders in the pictures).
- C. SIX intra-oral photographs: all photographs should be taken as close to a 90 degree angle as possible and ideally all teeth in mouth should be seen in the photos except for the overjet/overbite photo. The following are required views in **centric occlusion**: frontal, left and right lateral and over- jet/overbite and maxillary and mandibular occlusal views.
- D. All cases are required to have a complete set of pre-treatment, post-treatment and two year post active treatment photos as applicable.

***IBO Photographic Standards***



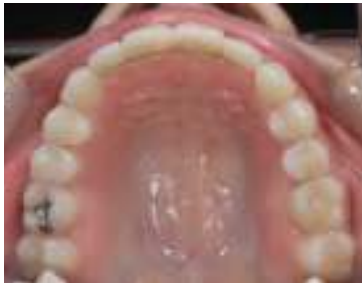Frontal view lips reposed



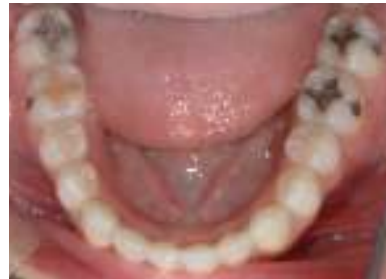Profile view lips reposed



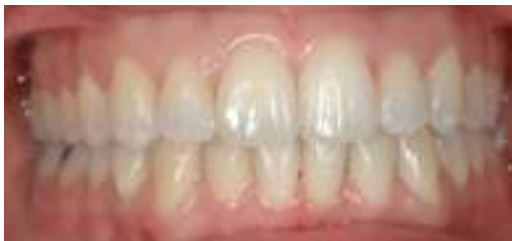Frontal view posed smile



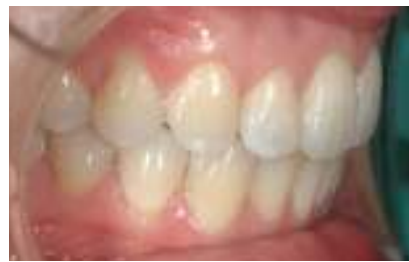Maxillary arch  
(Retracted occlusal mirror view)



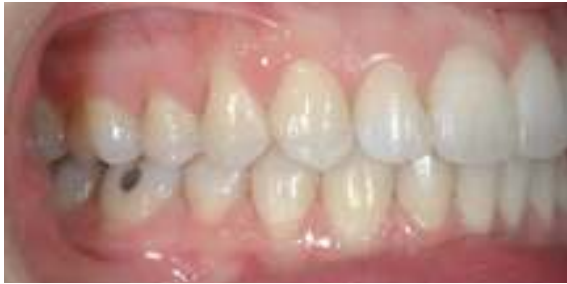Mandibular arch  
(Retracted occlusal mirror view)



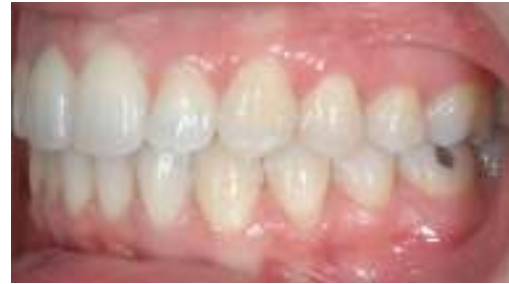Retracted frontal view (centric occlusion)



Retracted lateral view (overbite/overjet)



Retracted right lateral view (centric occlusion)



Retracted left lateral view (centric occlusion)

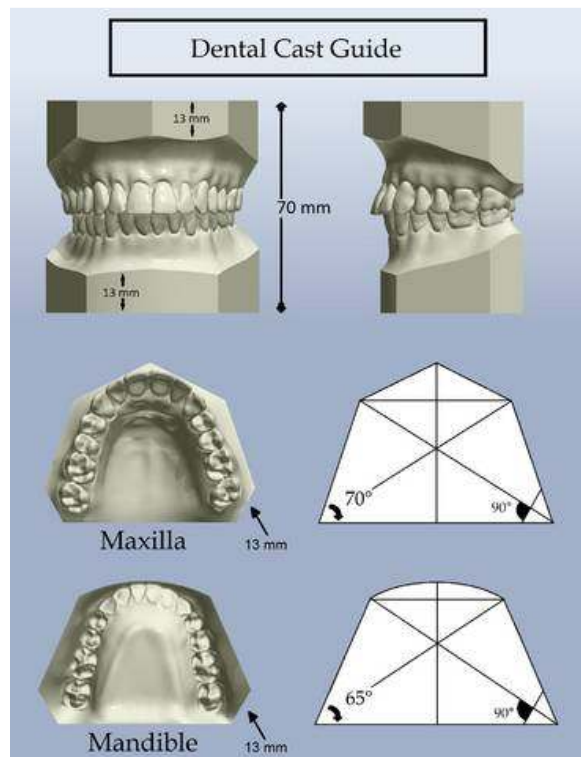
### Section VI: Study Models

All cases are required to have pre-treatment, post-treatment and when necessary 2 or more years post active treatment of all study “soaped” models. They should be clearly marked with date records taken, patient’s IBO ID number and Doctor’s IBO ID number.

The IBO Standards are as follows:

Orthodontically trimmed and finished art models in white stone including the hard and soft tissues. The dental anatomy should be clear well defined as well as the impression of soft tissue to the mucobuccal fold.

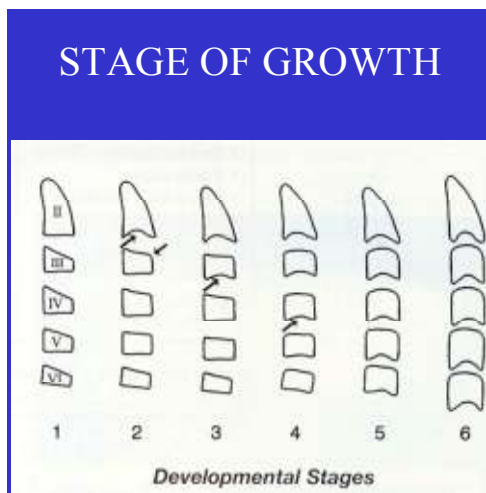
### IBO Standards for Study Models



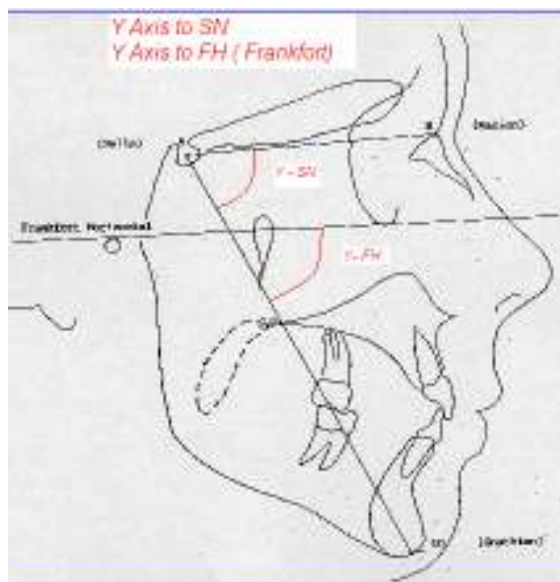
(Courtesy of Dynaflex Labs)

**Section VII: Analysis of Cephalometric Radiographs and Diagnosis:**

- B. Cephalometric Radiographs should be hand traced (digital is acceptable).
- C. Any recognized Cephalometric analysis may be used for analyzing the case, however, the **following cephalometric measurements are required:**

**1- Analysis of Growth:****a. Stage of growth - CVMS Method****SIX STAGES OF MATURATION**  
(From Franchi et al [11])

- Stage 1.** The inferior borders of the bodies of all cervical vertebrae are flat. The superior borders are tapered from posterior to anterior.
- Stage 2.** A concavity develops in the inferior border of the second vertebra. The anterior vertical height of the bodies increases.
- Stage 3.** A concavity develops in the inferior border of the third vertebra.
- Stage 4.** A concavity develops in the inferior border of the fourth vertebra. Concavities in the lower borders of the fifth and sixth vertebrae are beginning to form. The bodies of all cervical vertebrae are rectangular in shape.
- Stage 5.** Concavities are well defined in the lower borders of the bodies of all 6 cervical vertebrae. The bodies are nearly square in shape and the spaces between the bodies are reduced.
- Stage 6.** All concavities have deepened. The vertebral bodies are now higher than they are wide.

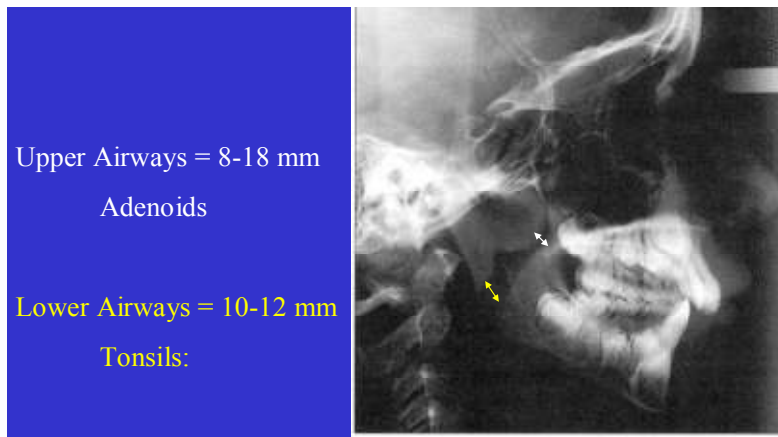
**b. Direction of growth –Y-axis to SN and Y-axis to FH**

Y-axis to SN and Y-axis to FH

A Y-axis to SN greater than 66 indicates a vertical growth direction, likewise a Y-axis to FH greater than 59. The opposite, less than 66 and less than 59 would indicate a horizontal tendency.

## 2- Analysis of the airway:

- a. Upper Airway: Naso-pharyngeal
- b. Lower Airway: Oro-pharyngeal



**8-18 mm** **Upper Airway** (Measured just distal and inferior to the Maxillary second molar area)

Norm 8-18mm If the measurement is between these numbers, with 8mm being a child and 18mm being an adult, then the patient should have adequate airways.

Application: If smaller than 8mm then there may be constriction of the upper airway. If larger than 18mm then the patient should have an open upper airway.

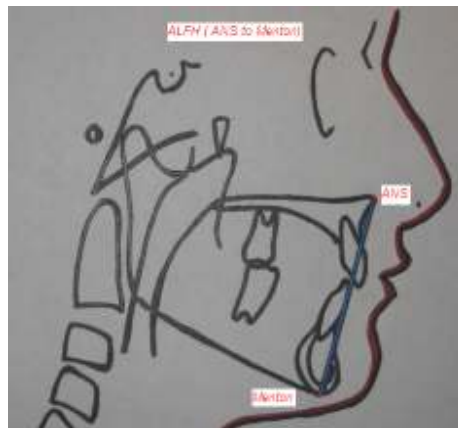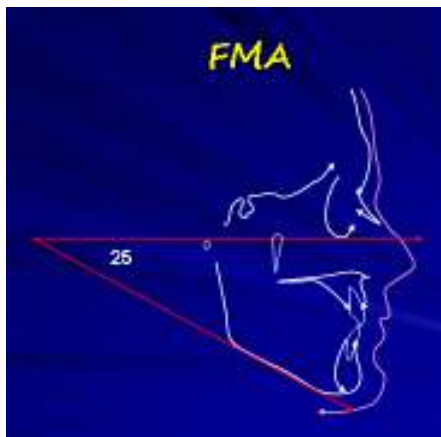
**10-12mm** **Lower Airway** (Measured at the Gonial Angle area)

Norm 10-12mm If the measurement is between these numbers, with 10mm being a child and 12mm being an adult, then the patient should have adequate airways.


Application: If the measurement is smaller than 10mm then the patient may have a lower airway constriction. If larger than 12mm then the patient should have an open lower airway.

**3- Analysis of the skeletal Vertical Dimension:**

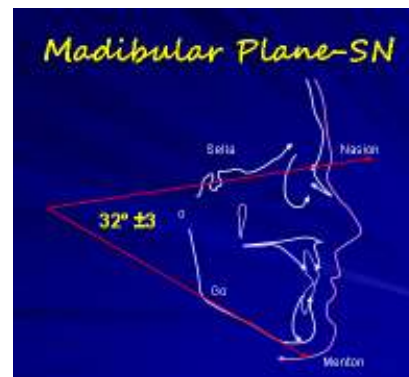
- a. FMA (Mandibular Plane to Frankfort Horizontal)
- b. LAFH (Lower Anterior Facial Height) (mm)
- c. UAFH- LAFH/TAFH (% ratio)
- d. SN- GoGn (Steiner)



**RATIO UFH/LFH**

	Child	Adult
	50%	45%
	50%	55%

**LAFH**



UAFH/TAFH x 100, LAFH/TAFH x 100

Mandibular Plane to SN

**FMA Norm  $25^{\circ} \pm 4^{\circ}$**  (Frankfort Mandibular Angle, or angle of the mandibular plane to Frankfort Horizontal Plane). FMA indicates both the steepness of the mandibular angle and the assessment of vertical skeletal development.

Application: Used to determine the degree of vertical growth occurring in the mandible. In a case with an FMA beyond 25 the growth is seen as more vertical, and the "skeletal bite" is said to be more "open" than the norm. If FMA is less than 25, then the patient is more horizontal and the case is categorized as more "closed" than the norm.

**LAFH Norm 58-72mm** ( you measure the length a the line from ANS (Anterior Nasal Spine to M (Menton). This tells if the lower anterior face height is normal for that patient. Problem with this norm: it has not been correlated with the age of the patient.

Application: A patient with less than 58mm of lower anterior face height may be associated with a closed vertical dimension. A patient with more than 72mm of lower face height may be associated with an open vertical dimension. Note that this measurement does not take age into consideration, something we do need to consider.

**UF/LF % Norm = 50/50% for children. 45/55% for adults.**

**The comparison of Upper Face to Lower Face height in percentage.** (The measurements are taken as follows: UF = Nasion (N) to Anterior Nasal Spine (ANS) in mm. LF = Anterior Nasal Spine (ANS) to Pogonion (P) in mm.)

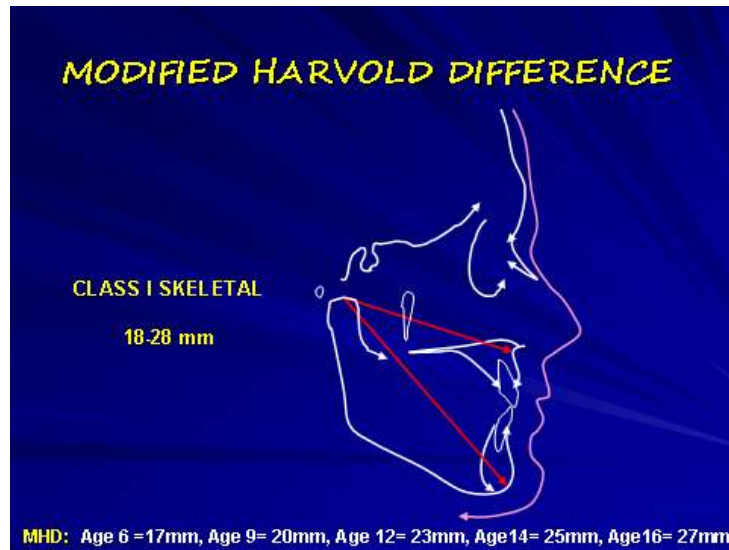
**SN-GoGn Norm  $32^{\circ} +\text{-} 3^{\circ}$**  (Angle of the Sella-Nasion plane to the Gonion-Gnathion plane.)

Measures a normal growth angle of the Mandible.

Application: When the angle is greater than  $35^{\circ}$  the Mandible is growing more vertical than the norm. If less than  $29^{\circ}$  then the mandible is growing more horizontal than the norm.

#### 4- Analysis of the Skeletal Horizontal Dimension:

- a. **Modified Harvold Analysis:** (Length of Mandible **minus** length of Maxilla: analyze the **difference** of these measurements ( **this measurement is age dependent**)).
  - A. Condylion to A (Maxillary length)
  - B. Condylion to Gn (Mandibular length)



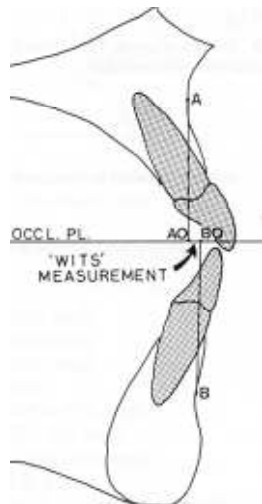
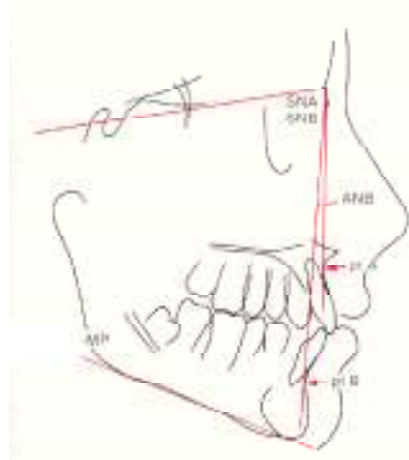
Differences by Age 6=17mm; Age 9= 20mm; Age 12= 23mm; Age14=25mm; Age16= 27mm.

### **Modified Harvold Analysis (Length of the Mandible Compared to the Maxilla by Age)**

**17mm age 6** Length of the Mandible compared to the length of the Maxilla by age of patient (measure the length of the Mandible from Condylion-Point B and the length of the Maxilla from Condylion to Point A.)

Norm based on age from 6-16: At age 6 the difference of the length of the Mandible minus the length of the Maxilla should be 17mm. At age 9\20mm at age 12\23mm at age 14\25mm and at age 16\27mm.

Application: For a patient age 6; If greater than 17mm the Mandible is either too long or Class III tendency or the Maxilla is too small and a retrusive upper arch. If less than 17mm then the Mandible is too short for the Maxilla or Class II tendency or the Maxilla is too big and you have a prognathic upper arch. *The spreadsheet calculates the norms for each age and tells you if the Mandible is too long or too short for each age.*

**b. Wits(mm):****c. ANB(Degrees):****SNA, SNB, ANB****Wits**

Jacobson, in 1976, proposed his "Wits" appraisal (named after his Witwatersrand University in South Africa). In taking this single measurement, Point A and Point B would each be projected onto occlusal plane at 90°, and a dot would be made. The distance between the dots would represent the anterior-posterior disharmony of the jaws.

**Wits: Class I Skeletal Norm = -1 to+3 mm.** When comparing the position of Point A on Occlusal Plane to Point B on Occlusal Plane.

Application: If the Wits value increases so that the maxillary dot moves forward of the mandibular dot, this indicates the Class II skeletal relation is increasing. As soon as the Wits reads minus 2 or more mm, the probability of Class III skeletal relation increases. In this analysis the Wits reading will override the ANB evaluation in most cases. Therefore, if ANB reads +4 mm (moderate Class II skeletal relation), while the Wits reads 0 mm (norm Class I skeletal relation), the Wits appraisal will be used to describe the patient's skeletal relation

**ANB**

The ANB angle is the most commonly used measurement in diagnosing the disharmony of the maxillary and mandibular jaws in the A-P plane. Steiner made it one of the basic evaluations of his analysis. However, there are problems with the use of ANB. Two common ones are: 1) If the length of anterior cranial base S-N is increased so that nasion is

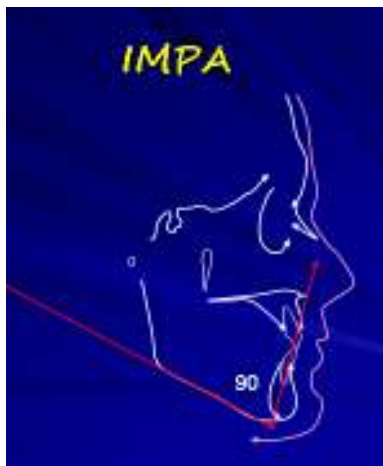
positioned more anteriorly, this has the effect of moving the ANB reading from a plus to a minus value in some instances! 2) Forward positioning (bimaxillary prognathism) of both jaws has the effect of **increasing** the value of ANB.

**ANB Class I Skeletal Norm = 0-5°** Indicates the relationship of the maxillary denture base to the mandibular denture base. A positive reading means the maxillary jaw is forward of the mandibular jaw. The easiest method of obtaining the value of ANB is to subtract SNB from SNA.

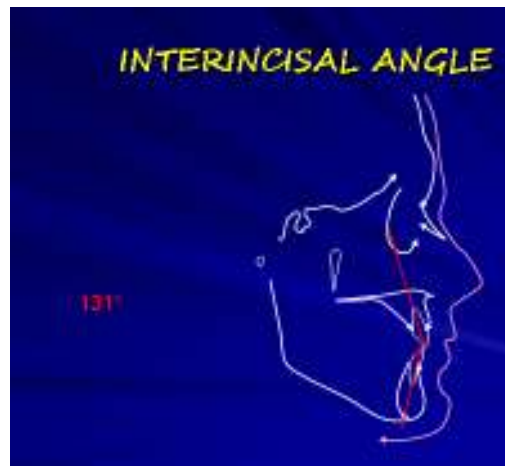Application: As the value of ANB increases above 5°, the potential for a Class II skeletal relation increases. As the value falls below 0°, the potential for a Class III skeletal relation increases.

#### 5- Analysis of the Dento-Alveolar Relations:

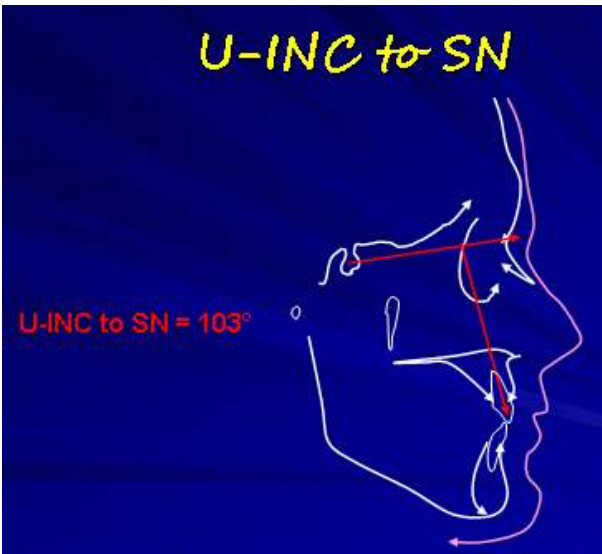
- a. IMPA
- b. Interincisal Angle
- c. Mx incisor to SN
- d. Mn incisor to A-Pog



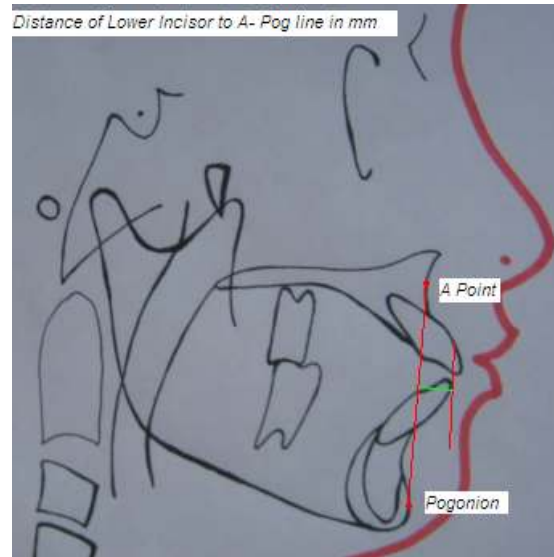
IMPA



Interincisal Angle



Upper incisor to SN



Lower incisor to A-Pog

### IMPA

**IMPA Norm  $90 \pm 5^\circ$**  (Incisor Mandibular Plane Angle, or axis of Mn1 in relation to Mandibular Plane). This is the first angle of the Tweed Diagnostic Facial Triangle.

Application: As Mandibular incisor is inclined labially beyond the norm, arch length is increased, but the incisors tend to incline forward beyond their alveolar support base, and beyond the stability point, as defined by the AP line. As the mandibular incisor is inclined lingually below the norm, the incisors are seen to crowd themselves and the canines.

**Mxl/ Mnl Norm  $131 \pm 4^\circ$**  The Interincisal Angle measures the long axis of the most labially inclined upper central incisor to the most labially inclined lower central incisor. Measure the angle of the long axis of the Maxillary Central to the Mandibular Central Incisor.

Application: The larger the angle, the less protrusive and the more vertical the teeth are in relation to each other.

**Mxl/SN Norm  $103 \pm 2^\circ$**  (Measures the angle of the long axis of the Maxillary Central Incisor to

the SN plane). Establishes the inclination of the axis of Mx1 compared to SN plane. In effect it measures how the upper central incisor is inclined labially.

Application: As the angle increases Mx 1 is flared to the labial, giving the maxilla a prognathic look to it. As the angle decreases a Division 2 central incisor relationship develops.

#### Mn1 to A-Po Line

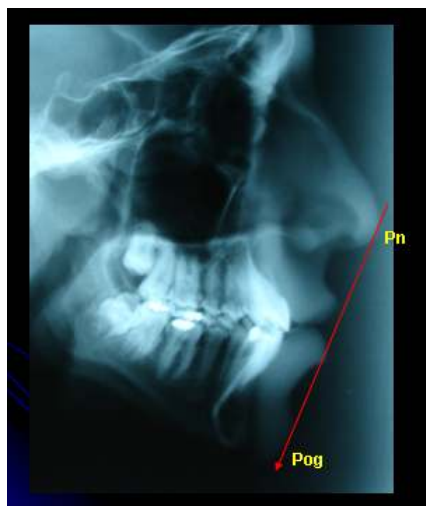
**Mn I to A-Po Line Norm: -1 to 3mm** (The position of the facial tip of Mnl in relation to the Point A-Pogonion line.)

Norm = -1 to 3mm. Indicates that the best soft tissue matrix support (lower lip) against Mnl occurs when the facial surface of Mnl is positioned exactly on the A-P line, called the Raleigh Williams Diagnostic Line.

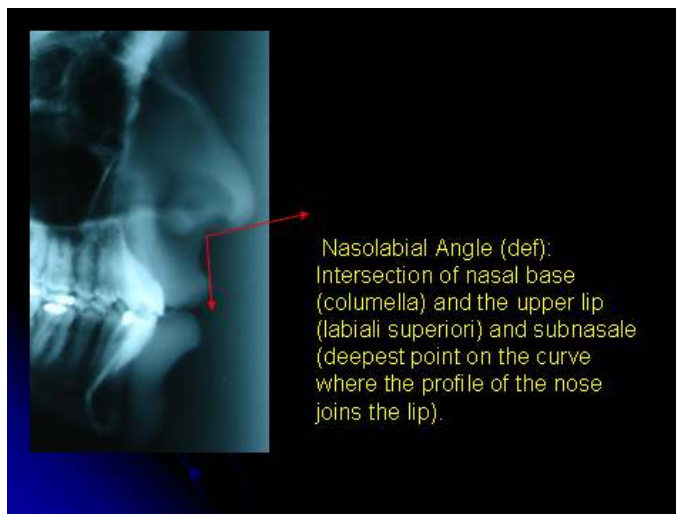Application: If Mnl is **buccal** of AP line, relapse of the incisors is likely to occur to the lingual. If Mnl is located **lingual** to the AP line, the incisors tend not to be stable and will lapse forward. This is an important measurement when stability of lower incisors following bicuspid extractions is being considered.

#### 6- Analysis of the Soft Tissues:

- a. Esthetic Line (Rickett's): Line to lower lip (mm)
- b. Naso-labial angle: 96-118 degrees
- c. Lip competence: yes or no



Esthetic Line



Nasolabial Angle

### Ricketts Esthetic Line

**E-Plane Norm 0mm +/- 2mm: Mx lip/** (Maxillary lip in relation to E-Plane) On the head film find the most anterior surface of the maxillary lip and measure it to the esthetic plane. Hopefully, the lips on the head film are at rest. Normally this is with the lips together. If patient is a mouth breather lips may be apart and that is the position you measure.

Application: The outline of each lip position is measured to a line drawn from the tip of the nose to the soft tissue pogonion on the chin, which is the E-plane. Norm lips should "kiss" this plane at rest. The same relation may be diagnosed at the chair by using a length of unwaxed dental floss held against the tip of the nose and against the soft tissue forward point of the chin (pogonion). In extraction cases it is common for the lips to lose one to three millimeters of bony and incisor support during treatment. This causes the "dished in" look seen in some extraction cases at the termination of treatment. A good looking face can have either negative or positive measurements within the norm.

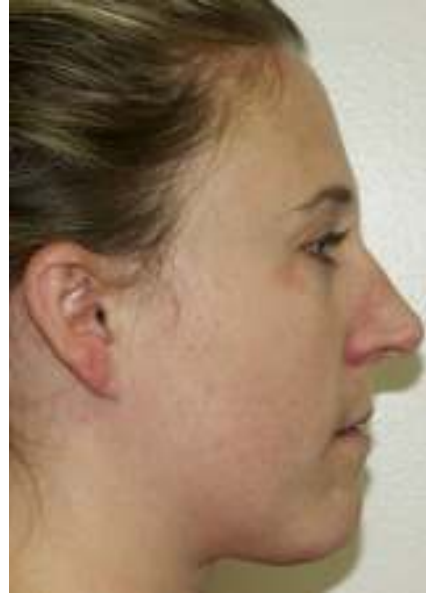### Nasio-Labial Angle

**Nasio-Labial Angle Norm 96° to 118°:** (Measure the inside angle made by lines from Soft Tissue Point A to tip of nose and tip of Maxillary lip.) Angle is measured from the buccal part of the intersection of the two lines.

Application: As the angle gets larger the Maxillary lip flattens out and might be retrusive. As the angle gets smaller the Maxillary lip is more protruded and the Maxillary teeth might be flared out to the buccal.



Nasolabial angle normal

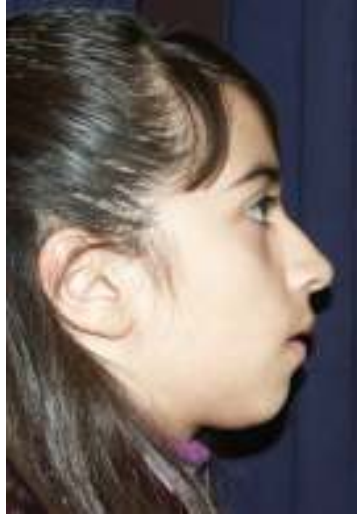

Open Nasolabial angle

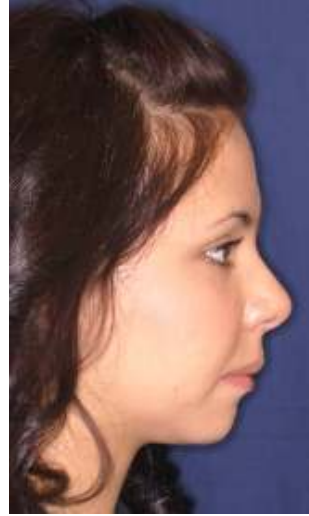**Lip Seal: Yes or No** (does the patient have competent or incompetent lips?)

Norm= Yes for Competent lips or No for incompetent lips.

Application: Two factors are evaluated when diagnosing the relation of the patient's lips. Whether the lips are competent or incompetent; in other words, are they touching and sealed at rest following a swallowing act (competent)? Or are they apart habitually (incompetent)? The more the competency of the lips increases, the better they will act as an effective soft tissue matrix to maintain the anterior tooth relations attained by orthodontic treatment. It is best to think of lip competency ranging from severe compression of the lips to open, flaccid, parted lips as seen at rest. Additionally you may see in those patients without lip seal, a tight mentalis or strain in this area, which may "hide" photographically a case of lip incompetence; this is just one reason to try to capture this pre-treatment condition in your profile photo by asking the patient to "relax" their lips.



No lip seal



Lip seal

- D. Case Diagnosis:** This section should include a **complete** diagnosis (Skeletal and dental): Include clinical findings, functional evaluation, entire IBO cephalometric summary, full mouth series or panoramic radiographs, model analysis and anything pertinent in the medical and dental histories. When referring to a specific tooth that tooth must be identified using the #1 to #32 numbering system. **Remove paragraph prior to printing this page.**

## IBO Cephalometric Data Sheet



Area	Norm	Pre Tx	Post TX	2yr+Post Tx
<b>1-Growth</b> Stage - CVMS Direction - Y Axis	Stage I-VI To SN = $66^{\circ} \pm 2^{\circ}$ To FH = $59^{\circ} \pm 2^{\circ}$			
<b>2-Airways</b> Upper Airway Lower Airway	8-18 mm 10- 12 mm			
<b>3-Vertical – Skeletal</b> FMA (Ricketts) LAFH (McNamara) UAFH- LAFH/TAFH SN – GoM	$25^{\circ} \pm 4^{\circ}$ 58-72mm 45-55 % adult, 50-50% child $32^{\circ} \pm 3^{\circ}$			
<b>4-Sagittal –Skeletal</b> a. Modified Harvold Difference (Co to Gn - Co to A)  b. Wits (mm)  c. ANB (degrees)	Class I Skeletal by age: 6 – 9 – 12 – 14 - 16 (yrs) 17– 20 – 23 - 25 - 27 (mm)  Class I = -1 to +3 Class II $\geq$ +4 Class III $\leq$ -2  Class I = 0- 5 Class II > 5 Class III < 0			
<b>5-Dental</b> IMPA Interincisal Angle Mx incisor to SN Mn incisor to A-Pog	$90^{\circ} \pm 5$ $131^{\circ} \pm 4$ $103^{\circ} \pm 2$ -1 to 3mm			
<b>6-Soft Tissue</b> Rickett's esthetic Line Naso-labial angle Lip competence	-2mm +/- 2mm (lower lip) $102 \pm 8^{\circ}$ Yes or No			

**Section VIII: Treatment Objectives, Treatment Planning and Treatment Modalities must include transverse, vertical and horizontal considerations**

(This document contains suggestions in hidden text. To view hidden text, on the Tools menu click Options. On the View tab, check Hidden text in the Formatting marks section. Hidden text appears in red and will not print. Make sure you enter your evaluations next to the black type, not in the hidden text areas. Please remove this paragraph before printing your document.)

**A. Outline treatment objectives:**

A.

**B. Treatment Plan:**

1.

**C. Limitations, complications and prognosis:**

1.

**D. Explain mechano-therapy:**

1.

**E. Evaluate treatment progress:**

**Section IX: Case Finishing and Treatment Results:**

Evaluate the final results of the case and answer the following:

(Write down a brief statement on each area below for the case you are presenting.)

- A. **Overjet/overbite**
- B. **Cuspid/Molar relation**
- C. **Plane of Occlusion**
- D. **7's in occlusion**
- E. **Marginal Ridges**
- F. **Rotations**

- G. Spaces
- H. Soft Tissue (Intraoral)
- I. Root Parallelism
- J. Facial & Dental Midlines

### **Section X: Discussion of the case:**

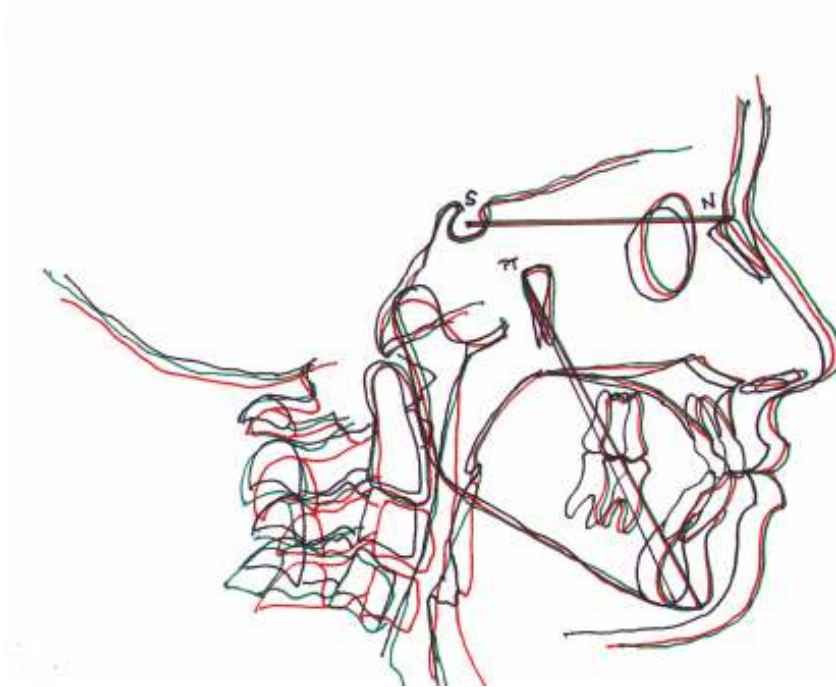
The discussion of the progress of the case from initial treatment to the end of active treatment. This discussion should include: Facial Esthetics, lips, skeletal relationship, length of treatment, difficulty of case, problems incurred, evaluation of objectives achieved, planning for post-active treatment retention, and patient's reaction to final results. **Please remove this paragraph before printing this page.**

### **CEPHALOMETRIC SUPER IMPOSITION**

Radiographic results: Need to do a Superimposition of pre-treatment, post active treatment and two or more years post active treatment cephalometric tracings as applicable and discuss the findings as they apply to the finished case. Superimposition of Pre-treatment, Post treatment and 2 or more years post treatment cephalometric radiographs as applicable. You can use either Sella-Nasion at Sella or Basion-Nasion at CC Point (Center of Cranium) as your superimposition point. **Please remove this paragraph before printing this page. Black- Pretreatment, Red- Posttreatment, Green – 2 years post treatment.**

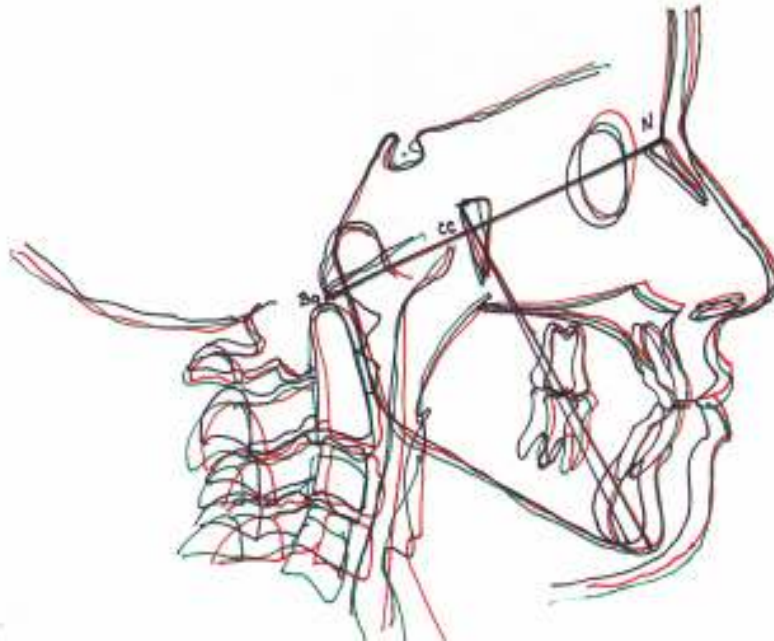
### **First Example**

(Sella-Nasion at Sella)



### Second Example

(Basion-Nasion at CC Point)



**You can choose either method to superimpose your cephalometric tracings. What the examiners will be looking for will be your comments drawn from the superimpositions. Such as orthopedic changes to the position of the maxilla or mandible, positional changes to the molars, changes in upper or lower incisor angulations, and finally soft-tissue profile changes. The changes noted should also be related to your cephalometric analysis results.**

### **Further Study**

Appendix B of this Candidate Handbook contains an real graded IBO Diplomate Examination Case Presentation to illustrate the information presented above. When reviewing the sample case it is important to remember that is not "perfect" and is not intended to be. The case is graded and the reasons for point deductions are also given.

## IBO Confidentiality Policy

### Candidate Identity

IAO publishes the list of IAO Diplomates in the annual Membership Directory and on the IAO Member's Only website.

### Test Scores

The IAO maintains candidate and Diplomate confidentiality with regards to test scores and other data. Scoring of the written examination results in a pass/fail decision and individual numerical scores are not recorded. Individual pass/fail results will only be released if prior written consent is obtained from the candidate or Diplomate.

### Test Data Analysis and Sharing

In keeping with best practices of certification, the IAO may publish aggregate statistics on testing data without sharing the identity of individual test takers. These statistics may include, but may not be limited to, pass/fail data.

## IBO Disciplinary Policy

The International Board of Orthodontics (IBO) adheres to the *ADA Principles of Ethics and Code of Professional Conduct (ADA Code)*. All IBO Officers, IBO Members, Diplomates and Diplomate Candidates are expected to comply with the *ADA Code*.

### Publication of the IBO Disciplinary Policy

The most current version of the *ADA Code* will be distributed to IBO Officers and IBO Members on an annual basis to maintain familiarity with the requirements of the *ADA Code*. This policy will be published with Diplomate candidate preparatory materials to promote compliance by candidates and Diplomates.

Should any Officer, Member, Diplomate or Diplomate Candidate be suspected of violating the *ADA Code*, the following procedures will be put into place.

### Disciplinary Procedures

#### *Disciplinary Procedure for Diplomate Candidates*

1. Should an IBO Diplomate candidate be suspected of violating the *ADA Code* by an IBO Officer, IBO Member, Diplomate, or Diplomate Candidate or another party, the first course of action is to inform the IBO President directly of these suspicions. Any supporting evidence or documentation should be presented at the time the suspected violation is disclosed. IBO President shall serve the roll of primary investigator into any suspected violations of the *ADA Code*.

2. The IBO President will confidentially evaluate the merits of any evidence or documentation of suspected violation, and perform any necessary additional investigation into the suspected violation to determine if the allegations are compelling enough to be brought to the IBO to vote on the need for disciplinary action. The IBO President will inform the IAO President at the beginning of the investigation and will continue to keep the IAO President informed of as the investigation progresses. The purpose of involving the IAO President is to help ensure an unbiased assessment of the claims of any suspected violation.
3. In the course of the investigation, should the IBO President determine the suspected violation to be unsubstantiated, no further action will be taken. Should the IBO President find the evidence of a violation to be compelling, he or she shall inform the suspected candidate of the allegations and the candidate shall have the opportunity to explain the circumstances regarding the violation.
4. Following discussion with the candidate, the IBO President shall convene a meeting or teleconference of the Board to discuss the violation. The IAO Executive Director shall participate in the meeting or teleconference in an advisory role. The IBO President shall present to the Board the nature of the violation, the sequence of events that lead to the investigation of the violation, and the response by the candidate. The Board shall vote to determine if the violation should require disciplinary action by the Board.
5. Until the IBO has voted, the name of the candidate shall be kept confidential, known only to the IBO President. Should IBO determine that disciplinary action is required, the President shall disclose the identity of the candidate. The name of the person that initially brought forward his or her suspicions of violation shall remain confidential throughout the proceedings, known only to the IBO President, and shall not be disclosed at any time.
6. Should the IBO determine that no disciplinary action is required, the candidate will be informed of the decision and no further action will be taken.
7. Should the IBO determine disciplinary action is required, the candidate's application for Diplomate shall be terminated and the candidate shall be prevented from reapplying for a period of three (3) years. After the probationary period ends, the candidate may reapply for Diplomate, but must present all new cases to satisfy the Clinical Examination requirements. the candidate shall be notified in writing.
8. The candidate may appeal a decision of disciplinary action as per the IBO Appeals Policy.

---

*Disciplinary Procedure for Diplomates*

1. Should an IBO Diplomate be suspected of violating the *ADA Code*, the same procedure for investigation and evaluation shall be employed as with the *Disciplinary Procedure for Diplomate Candidates*. As with the procedure for Diplomate Candidates, the IBO President shall serve as primary investigator and the suspected Diplomate shall be given the opportunity to explain the circumstances of the suspected violation.
2. Should the IBO determine disciplinary action is required, and this is the Diplomate's first offense, IBO Diplomate status shall be rescinded for a probationary period of one (1) to three (3) years as determined by the IBO, based on the severity of the offense. During the probationary period, the Diplomate will not be listed as an IBO Diplomate in IBO or IAO publications, the Diplomate will not be permitted to refer to his- or herself either verbally or in writing as an IBO Diplomate. After a period of three years, the Diplomate may apply to reinstate their status by submitting a written report of steps taken to rectify the violation. Reinstated Diplomates shall also be asked to sign a formal acknowledgement that should a second violation be discovered, Diplomate status shall be rescinded permanently.
3. Should the IBO Diplomate also be a currently serving IBO Officer or Member, and the IBO President determines that review by the IBO is necessary, the IBO will be informed of the identity of the Diplomate prior to evaluation of the suspected violation. The Diplomate shall recuse themselves from his or her participation on the IBO until a decision has been made. Should the IBO determine that disciplinary action is required, the Diplomate's term of office shall be terminated and the Diplomate will no longer be eligible for re-election.
4. Should the IBO Diplomate be the currently serving IBO President, the IBO Vice President shall assume the role of primary investigator.
5. The Diplomate may appeal a decision of disciplinary action as per the IBO Appeals Policy.
6. Disciplinary policies related to failure to perform IBO duties, are described in *IBO Standing Rules, Appendix A: Mechanism of Nomination, Election, & Replacement of an IBO Examiner*.

## IBO Appeals Policy

An IBO Officer, Member, Diplomate or Diplomate Candidate may seek to appeal an IBO determination for disciplinary action.

### *Procedure for Appeals*

1. An IBO Officer, Member, Diplomate or Diplomate Candidate may seek to appeal an IBO determination for disciplinary action by submitting a written letter of appeal to the IAO Executive Director. The letter should include a summary of the circumstances surrounding a violation of the *ADA Code* and an explanation of why the applicant feels the IBO determination for disciplinary action is not justified. The written notification of disciplinary action issued by the IBO should also be included with the applicant's letter of appeal.
2. Upon receipt of the letter of appeal, the IAO Executive Director shall notify the IAO President and the IBO President. The IAO President shall then convene an Appellate Committee comprised of five members including the IAO President, as chair, the IAO Education Committee Chair, one (1) IBO Member or IBO Officer, and two (2) IAO Education Committee members to be selected by the IAO President. The IAO Executive Director shall participate in the Appellate Committee in an advisory role.
3. The IBO President shall prepare a written report for the Appellate Committee on the IBO determination for disciplinary action for their consideration.
4. The Appellate Committee shall review the IBO President's report and the appellate applicant's letter to make a final determination on the need for disciplinary action. Should the Appellate Committee uphold the decision of the IBO, disciplinary action shall be enforced as outlined in the original decision of the IBO. There is no mechanism for further appeals.
5. Should a currently serving IBO Officer or Member be the appeals applicant, he or she shall not be permitted to serve on the Appeals Committee.
6. Should the currently serving IBO President be the appeals applicant, the IBO Vice President will assume the IBO President's role in the *Procedure for Appeals*.

## IBO Policy on Ethical and Professional Conduct

The International Board of Orthodontics (IBO) adheres to the *ADA Principles of Ethics and Code of Professional Conduct (ADA Code)*. The five fundamental principles of the ADA Code are\*:

1. *Patient Autonomy: the dentist has a duty to respect the patient's rights to self-determination and confidentiality*

2. Nonmaleficence: *the dentist has a duty to refrain from harming the patient*
3. Beneficence: *the dentist has a duty to promote the patient's welfare*
4. Justice: *the dentist has a duty to treat people fairly*
5. Veracity: *the dentist has a duty to communicate truthfully*

*\*These principles are excerpted from the ADA Code, pages 4-10.*

IBO Officers, Members, Diplomates, and Diplomate Candidates are expected to accept these five principles as the foundation of their professional lives and their work within the IBO. They are also expected to comply with the requirements of the *ADA Code* in their IBO-related activities. Should an IBO Officer, Member, Diplomate, or Diplomate Candidate be suspected of violating the *ADA Code*, the *IBO Disciplinary Policy and Procedures* shall be employed.

## **IBO Diplomate Recertification Policy**

### **Maintenance of Diplomate Requirements**

To enhance continued competence of Diplomates. Beginning January 1, 2015, all IBO Diplomates will be required submit to IAO Headquarters documentation of attendance of at least 40 hours of continuing education (CE) in orthodontics over a period of three years, in order to maintain their status as an IBO Diplomate. All CE hours submitted should be AGD PACE or ADA CERP approved.

### **CE Hours Submission Process**

IBO Diplomates should use the standard IAO Tier Advancement CE Hours submission process to submit their CE Hours to Headquarters. This may be done online in the Member's Only Section of the IAO website or documentation of hours may be faxed or emailed to headquarters, Attn: IAO Tier Advancement.

### **CE Hours Review Cycle**

1. Each review cycle shall span three (3) years.
2. The first cycle shall begin January 1, 2015 and end December 31, 2017.
3. All Diplomates shall be required to submit documentation of the minimum number of CE hours by December 31, 2018. Subsequent review cycles will follow the calendar year, with the required documentation due by December 31 of the third year of the cycle.
4. IAO Headquarters will review all Diplomate records for completion of this requirement and Diplomates will be notified of their status by February 15, following the end of the review cycle. Diplomates that have successfully complied with the recertification requirements shall be issued a new Diplomate Certificate.

**Failure to Comply with the IBO Recertification Policy**

Failure to submit documentation of the minimum requirement of CE hours within the stated three years shall result in Diplomate status being put on probation. Diplomates on probation shall have one (1) year to complete the missing CE hours. To be relieved of probation, Diplomates must submit missing CE hours with a formal application. Missing hours will not count toward the required hours of the new review cycle.

*Reapplication of an Invalidated Diplomate Status:*

A Diplomate on probation who has failed to fulfill the missing CE requirement in the one year time limit shall have their Diplomate Status rescinded. The doctor will no longer be listed as an IBO Diplomate in IBO or IAO publications, and will not be permitted to refer to his- or herself either verbally or in writing as an IBO Diplomate. The doctor may apply to have Diplomate status reinstated by submitting an application for reinstatement including documentation of missing CE hours that would meet the delinquency requirement that would be necessary to comply with the 40 hours/3 year commitment, an explanation of delinquency, and a small reapplication fee. All documentation should be submitted to the IAO Central Office for review and approval by the IBO.

*Appeal of an Invalidated Diplomate Status:*

There are many extenuating circumstances that may prevent a Diplomate from complying with the 40 hour requirement. An active IAO Member may appeal an Invalid Diplomate Status by submitting formal application to the IAO Central Office for consideration. All Appeals shall be reviewed and ruled upon by the IBO.



**International Association for Orthodontics**

**Application for Tier Advancement**

**Diplomate**

***Photo Required***

**Please check the examination for which you are applying:**

\_\_\_\_\_ IBO Written Examination and IBO Clinical Case Examination (US \$500.00)

\_\_\_\_\_ IBO Written Examination ONLY (US \$100.00)

\_\_\_\_\_ IBO Clinical Case Examination ONLY (US \$400.00)\*

*\*Candidates must have passed the IBO Written Examination prior to taking the IBO Clinical Case Examination.*

IAO ID \_\_\_\_\_ Date Joined (MM/YYYY) \_\_\_\_\_

**Candidate Demographic Information**

Name \_\_\_\_\_

Address \_\_\_\_\_

City \_\_\_\_\_ State \_\_\_\_\_ Zip/Postal Code \_\_\_\_\_

Country \_\_\_\_\_ Phone \_\_\_\_\_ Fax \_\_\_\_\_

Email \_\_\_\_\_

Date of Birth (optional) \_\_\_\_\_ Citizenship (optional) \_\_\_\_\_

**Candidate Practice Information**

Please Check \_\_\_\_\_ General Dentist \_\_\_\_\_ Pediatric Dentist \_\_\_\_\_ Otho Limited

Please Check \_\_\_\_\_ Private Practice \_\_\_\_\_ # of Years in Private Practice

\_\_\_\_\_ Solo \_\_\_\_\_ # of Years, Solo

**Educational History**

Undergraduate University:	_____	Degree	_____	Date Awarded (MM/YYYY)	_____
Dental School:	_____	Degree	_____	Date Awarded (MM/YYYY)	_____
Postgraduate School:	_____	Degree	_____	Date Awarded (MM/YYYY)	_____

**Professional Affiliation**

University (Faculty) Affiliations: \_\_\_\_\_

Professional Memberships: \_\_\_\_\_

Honors, Awards: \_\_\_\_\_

Published Articles: \_\_\_\_\_

Community Activities: \_\_\_\_\_

**Payment Information**

Please check payment type:

MASTERCARD     VISA     AMEX     DISCOVER     US MONEY ORDER / US CHECK

Card Number \_\_\_\_\_ Expiration Date (mo/yr) \_\_\_\_\_

Security/CVV Code \_\_\_\_\_

Signature \_\_\_\_\_ Today's Date \_\_\_\_\_

**Please return this form, with your payment to:**

International Association for Orthodontics  
750 N Lincoln Memorial Dr., Ste 422  
Milwaukee, WI 53202 USA  
+1 414/272-2757 Fax:+1 414/272-2754  
E-mail: jennba@iaortho.org



**International Association for Orthodontics  
Specialist Application for Tier Advancement – Diplomate**

*\*Photo & Official written documentation of Board Certification is Required\* (This information may be attached.)*

First Name: \_\_\_\_\_ Last Name: \_\_\_\_\_ Title: \_\_\_\_\_

Address: \_\_\_\_\_

City: \_\_\_\_\_ State: \_\_\_\_\_ Zip/Postal Code: \_\_\_\_\_

Country: \_\_\_\_\_ Phone: \_\_\_\_\_ Fax: \_\_\_\_\_

E-Mail: \_\_\_\_\_ IAO ID #: \_\_\_\_\_ Year you joined IAO: \_\_\_\_\_

Please check: Ortho Limited Practice\_\_\_ Private Practice\_\_\_ (# years \_\_\_) Solo\_\_\_ (# years \_\_\_)

Today's Date: \_\_\_\_\_ Date of Birth: \_\_\_\_\_ Citizenship: \_\_\_\_\_

\*I am Board Certified in good standing with my national Orthodontist Association\*: Yes \_\_\_ No \_\_\_

*(Official written documentation of Board Certification is Required.)*

Undergraduate University / Degree / Date Awarded: \_\_\_\_\_

Dental School / Degree / Date Awarded: \_\_\_\_\_

Postgraduate School / Degree / Date Awarded: \_\_\_\_\_

University (Faculty) Affiliations: \_\_\_\_\_

Professional Memberships: \_\_\_\_\_

Honors, Awards: \_\_\_\_\_

Published Articles: \_\_\_\_\_

Community Activities: \_\_\_\_\_

Total Amount Due: **USD \$500.00** (please check payment type)

MASTERCARD    VISA    AMEX    DISCOVER    US MONEY ORDER / US CHECK

Card Number \_\_\_\_\_ Expiration Date (mo/yr) \_\_\_\_\_

Security/CVV Code \_\_\_\_\_

Signature \_\_\_\_\_ Today's Date \_\_\_\_\_

Please return this form, with your payment to:  
International Association for Orthodontics  
750 N Lincoln Memorial Dr. Suite 422 | Milwaukee, WI 53202 USA |  
E-mail: [worldheadquarters@iaortho.org](mailto:worldheadquarters@iaortho.org)  
+1 414/272-2757 | Fax: +1 414/272-2754



# THE INTERNATIONAL BOARD OF ORTHODONTICS

## DIPLOMATE "SAMPLE CASE" PRESENTATION

Please Note: It is strongly advised that candidates prepare IBO Board Cases for presentation by following the format presented here in the Diplomate "Sample Case" to ensure IBO Examiners are able to effectively review the cases.

---

## IBO TEMPLATE SECTION

---

- **THE TITLE PAGE**
- **TABLE OF CONTENTS**
- **SECTION ONE: Comprehensive description of the Dentition, Chief Complaint and Patient Expectations:**
- **SECTION TWO: Pertinent Medical and Dental History**
- **SECTION THREE: Cephalometric Radiographs**
- **SECTION FOUR: Panoramic, Full Mouth Series, Transcranial or Tomogram x-rays or other radiographs and records**
- **SECTION FIVE: Patient Photographs**
- **SECTION SIX: Study Models**
- **SECTION SEVEN: Analysis of Cephalometric Radiographs and Diagnosis**
- **SECTION EIGHT: Treatment Objectives, Treatment Planning and Modalities**
- **SECTION NINE: Case Finishing and Treatment Results**
- **SECTION TEN: Discussion of the Case**

**IBO CASE I.D. "SAMPLE"  
AGE: 25 YEARS 9 MONTHS**

**THE FUNCTIONAL AND FIXED ORTHODONTIC TREATMENT OF THIS  
CLASS I SKELETAL PATIENT IS PRESENTED IN PARTIAL  
FULFILLMENT OF THE DIPLOMATE CLINICAL REQUIREMENTS OF THE  
INTERNATIONAL BOARD OF ORTHODONTICS**

**DOCTOR I.D. CODE: "SAMPLE CASE"**

**TABLE OF CONTENTS**

**Numbers in ToC still need to be updated**

**Section I:****Comprehensive Description of the Dentition, Chief Complaint****And Patient Expectations: 5-7****Section II:****Pertinent Medical and Dental History: 7****Section III:****Cephalometric Radiographs and Hand Tracings: 8-9****Section IV:****Panoramic radiograph: 10****Section V:****Patient Photographs: 11-12****Section VI:****Study Models: 13-14****Section VII:****Analysis of Cephalometric Radiographs and Diagnosis: 15-16****Section VIII:****Treatment Objectives, Treatment Planning and Modalities: 17****Section IX:****Case Finishing and Treatment results: 18-19****Section X:****Discussion of the case: 19**

**Section I: Comprehensive Description of the Dentition, Chief Complaint and Patient Expectations (2 of 2 points)**

## CLINICAL EVALUATION:

Soft Tissue Evaluation:

- Facial Type – Mesocephalic.
- Facial Asymmetry – Facial asymmetry with skeletal midline deviation to right side.
- Profile – Straight profile.
- Nose – Normal nose size.
- Nasolabial angle – Within the norm.
- Lips – Normal lower lip, thin upper lip with competency, acceptable lip seal.
- Smile line – Normal smile line.
- Gingival Display – Acceptable gingival display.
- Tonsillar and Adenoidal tissue – Tonsillar tissue type I, adenoidal tissue WNL per radiographic evaluation of airway.
- Mentolabial sulcus – Within the norm
- Chin – Moderate soft tissue pogonion.
- Other –

Skeletal Evaluation:

- Maxilla –Retrognathic and constricted.
- Mandible – Appears slightly prognathic and broad
- Facial Height –Slightly long.
- Palate –Moderately deep palatal vault due to poor tongue swallow and cross bite.
- Genetic Conditions – None.
- Radiographic findings – No extraordinary findings.

- Chin – Moderate bony chin.
- Skeletal midlines –Mesocephalic asymmetric facial form, and facial asymmetry (skeletal midlines off 2mm to the right) due to cross bite of the right side.
- Skeletal Bite –Skeletally “low” angle.

Dental Evaluation:

- Dental Classification – Class III molars, Class III cuspid right side and class I cuspid on the left, no missing teeth, normal tooth size, 3 mm curve of Spee, no decay. No spaces, upper incisors slightly flared according to upper incisor at 109 degrees to NS; lower anterior teeth also slightly flared (IMPA 96 degrees and L-inc to A-Pog 3mm).
- Midlines – Off to right side 2mm a reflection of the skeletal midline deviation.
- Overbite/overjet – Overbite 3mm, overjet 2mm
- Closed bite –No, relatively normal.
- Cross bite – Antero-posterior cross bite (UR 2-UR 6).
- Model analysis – 2mm Curve of Spee, tooth-size discrepancy (U2’s)
- Arch shapes – Asymmetric arch forms, “broad” lower arch.
- Arch length – Normal arch length
- Caries Index – Low caries index, 11 amalgam restorations.
- Radiographic findings – Asymmetric condylar heads, longer left ramus.

Functional Evaluation: “Low” tongue position (inadequate swallow). TMJ: Full range of motion, max opening 53mm, both lateral movements ~11mm, protrusive 8mm, no deviation or deflection, no pain, no clicking, no crepitus, no popping, no palpable trigger points.

Special Considerations: Unsure as to long-term cross bite correction in this adult patient.

Patient’s Chief Complaint: Correction of cross bite.

Patient’s Expectations: Cross bite correction.

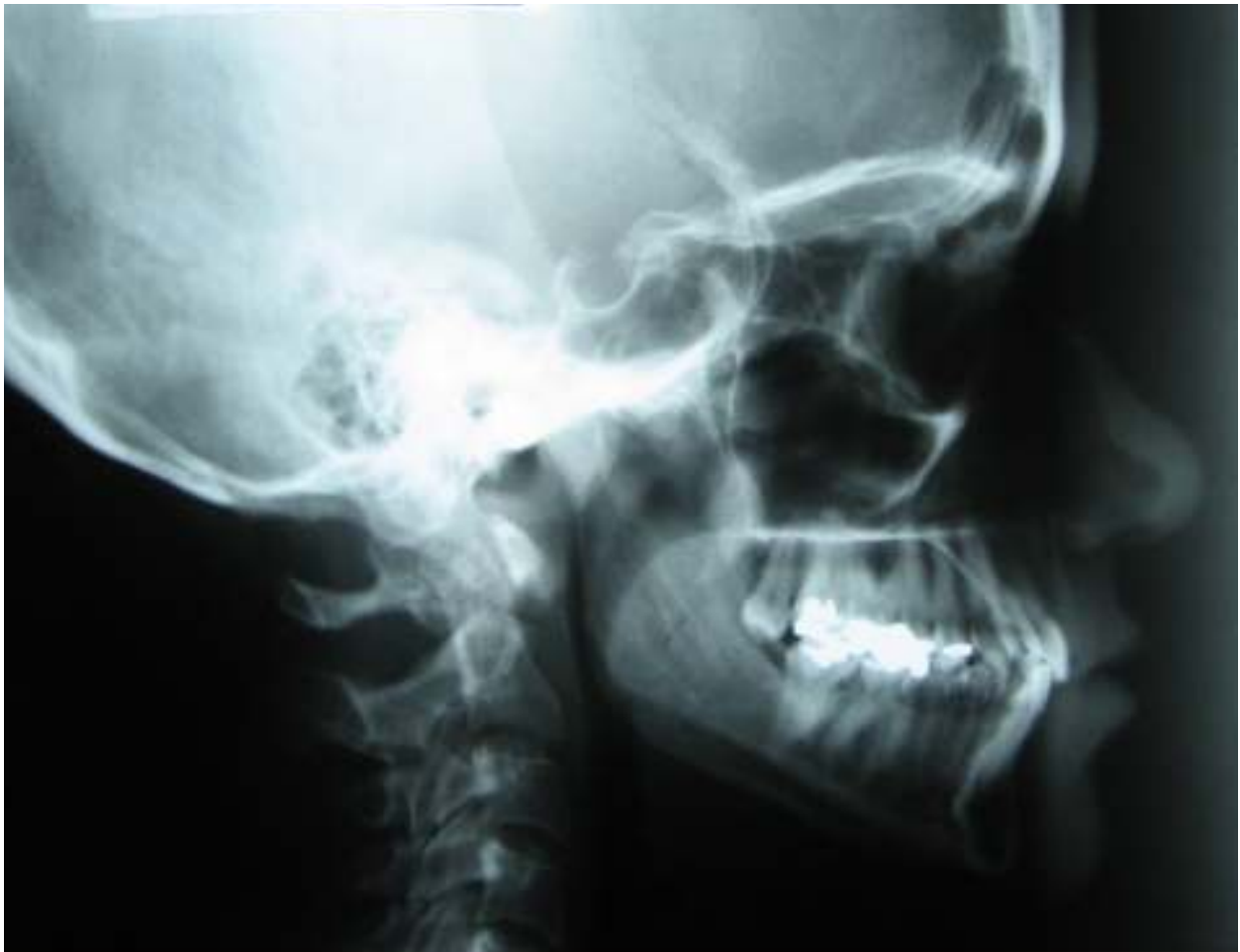**Section II: Pertinent Medical and Dental History (1 of 1 point)**

Medical History: No known medical problems other than seasonal allergies.

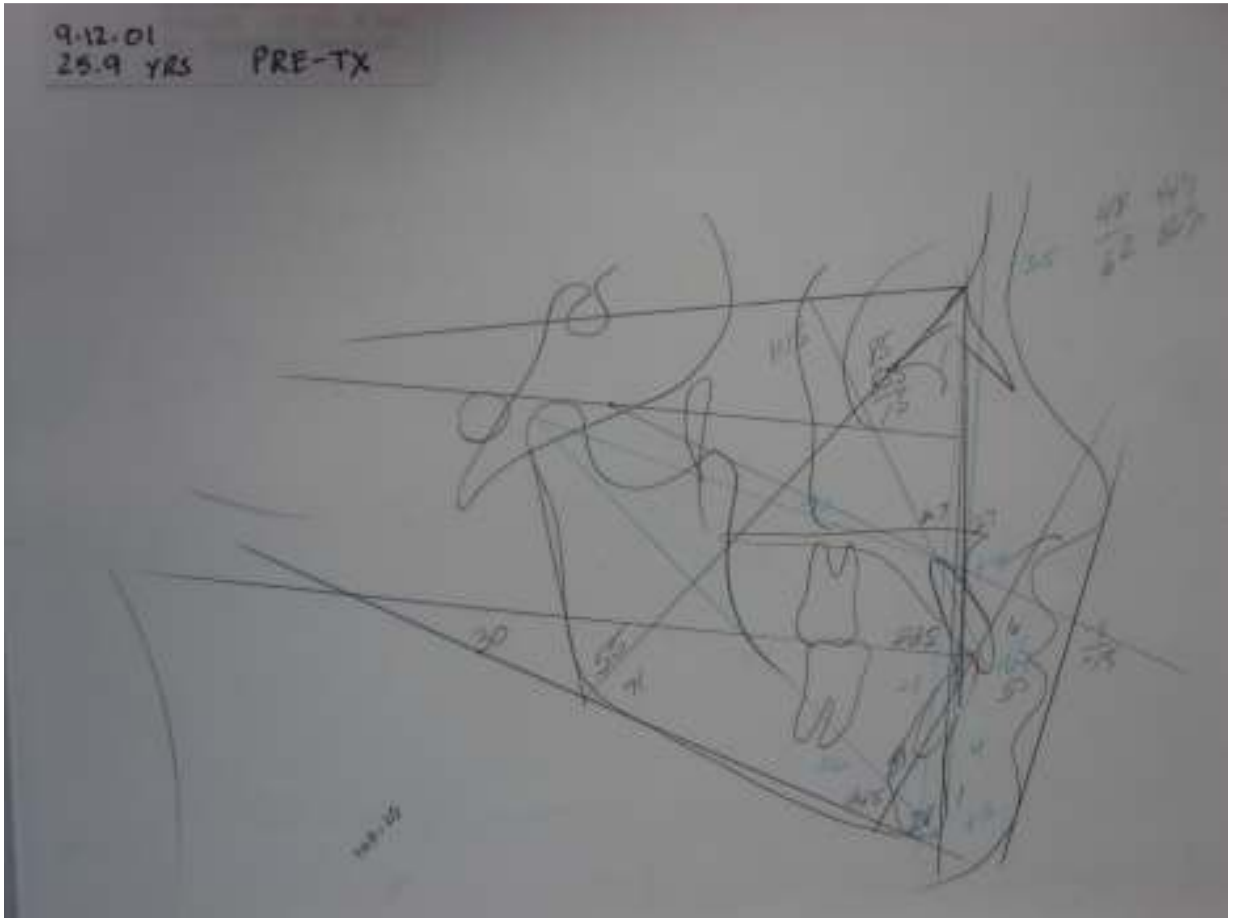
Dental History: Regular visits to dentist. There are several amalgam restorations. No periodontal concerns.

**Section III: Cephalometric Radiographs (1 of 2 points)**

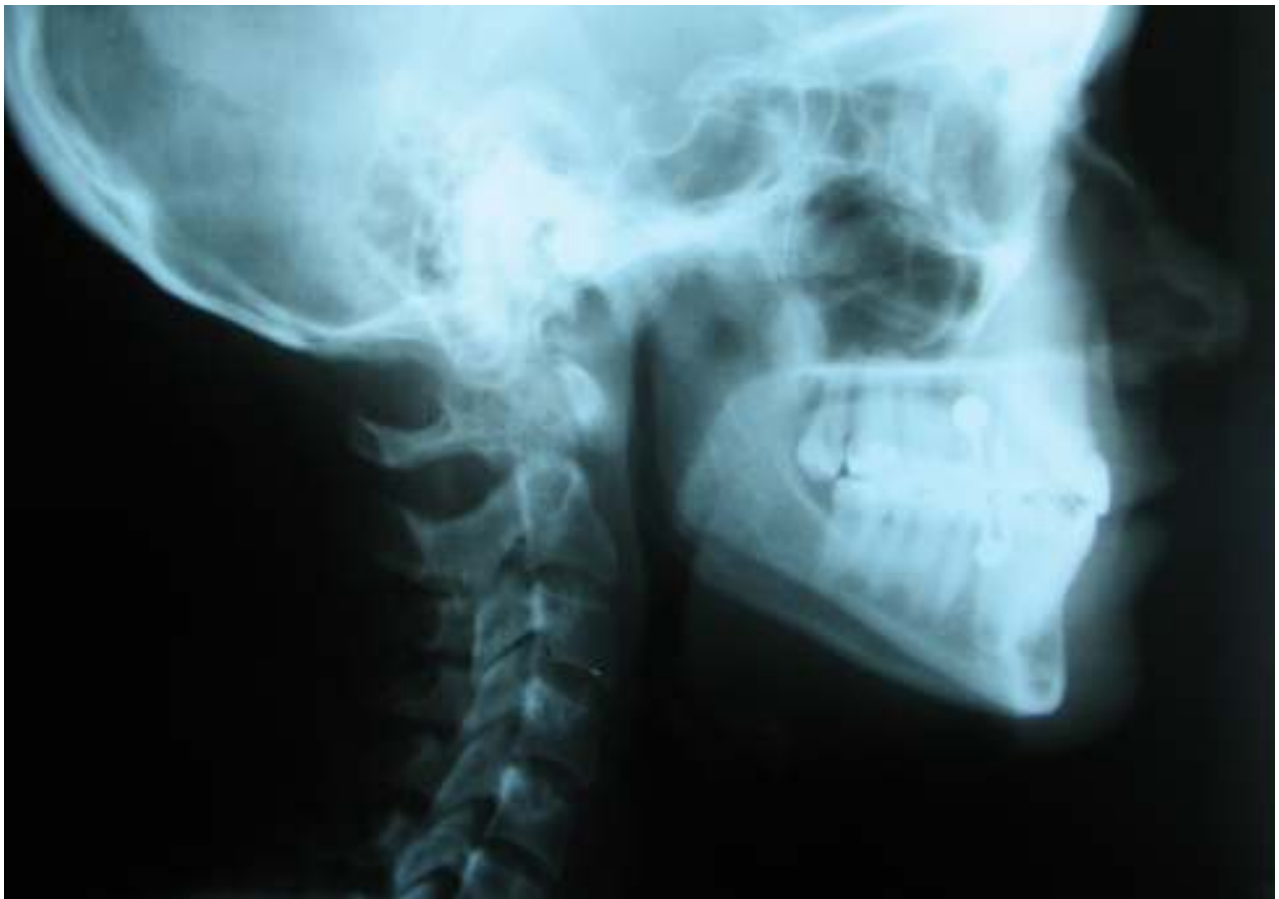**PRE-TX CEPHALOGRAM**



PRE-TREATMENT TRACING

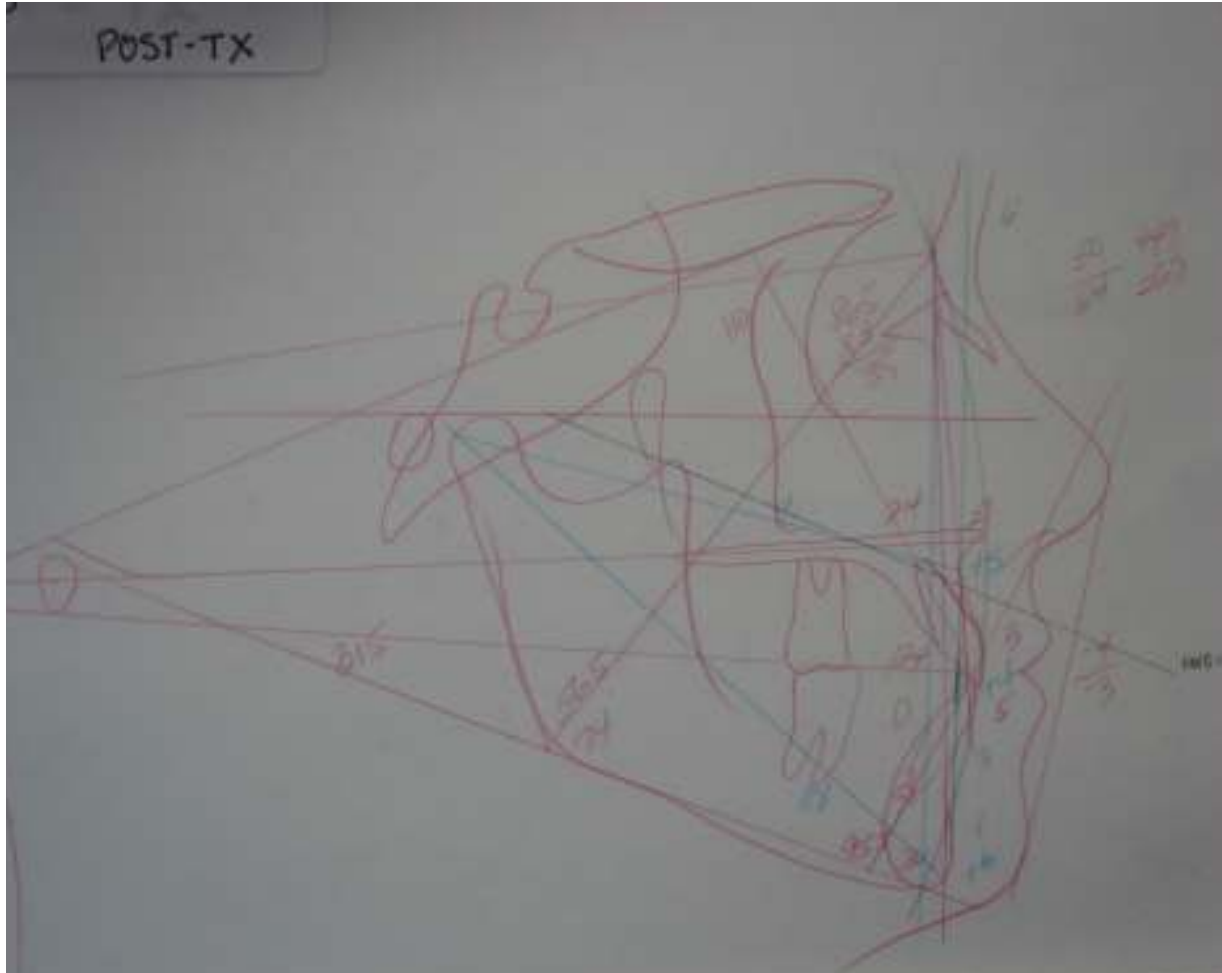


### POST-TX CEPHALOGRAM

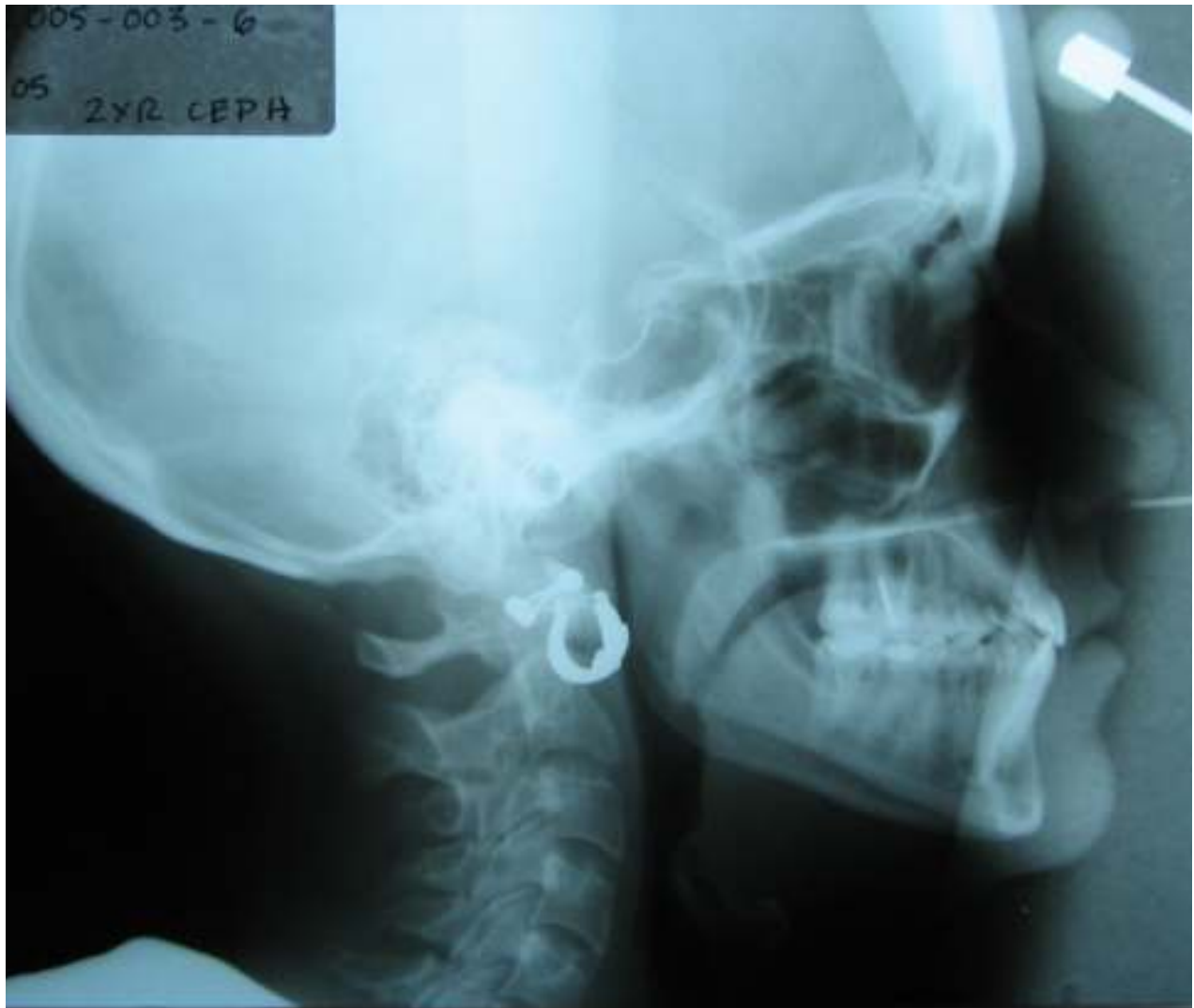

Note: Tongue ring not removed will affect “quality” score of cephalogram.

POST-TX TRACING

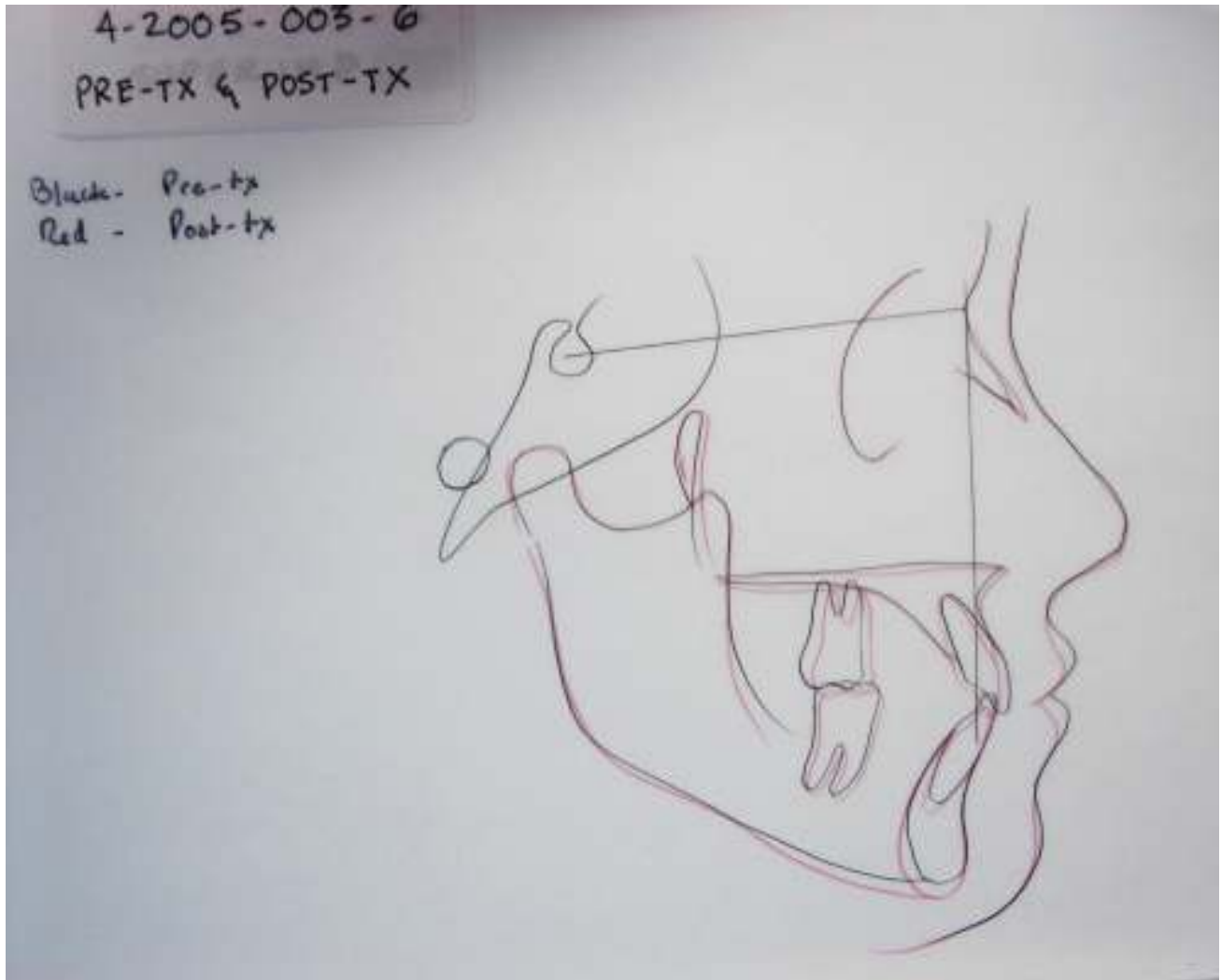


2-YEAR POST-TX CEPHALOGRAM




Note: earrings not removed will affect “quality” score of cephalogram

SUPERIMPOSITION: PRE AND POST TREATMENT



PRE-TX (black) and POST-TX SUPERIMPOSITION (red)

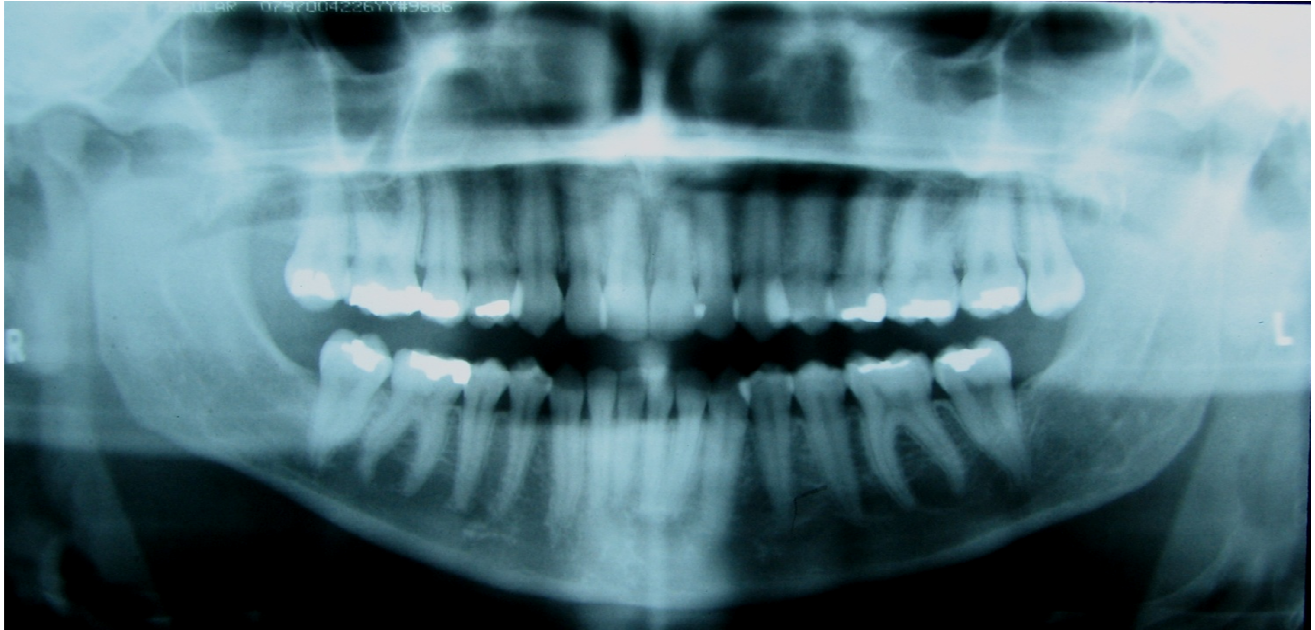
**SUPERIMPOSITION: POST-TX AND 2-YEAR POST-TX**



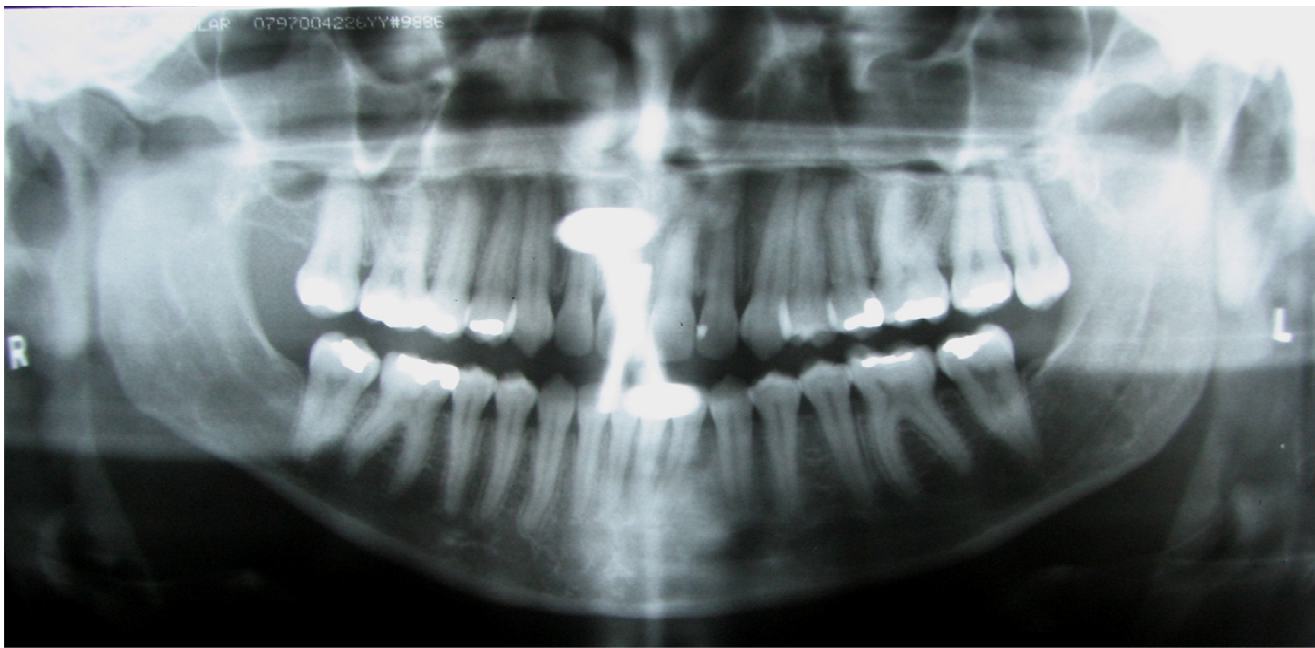
**POST-TREATMENT (red) AND TWO-YEAR SUPERIMPOSITION (black)**

**Section IV: Panoramic radiographs (.5 of 1 point)**

PRE-TX PANORAMIC

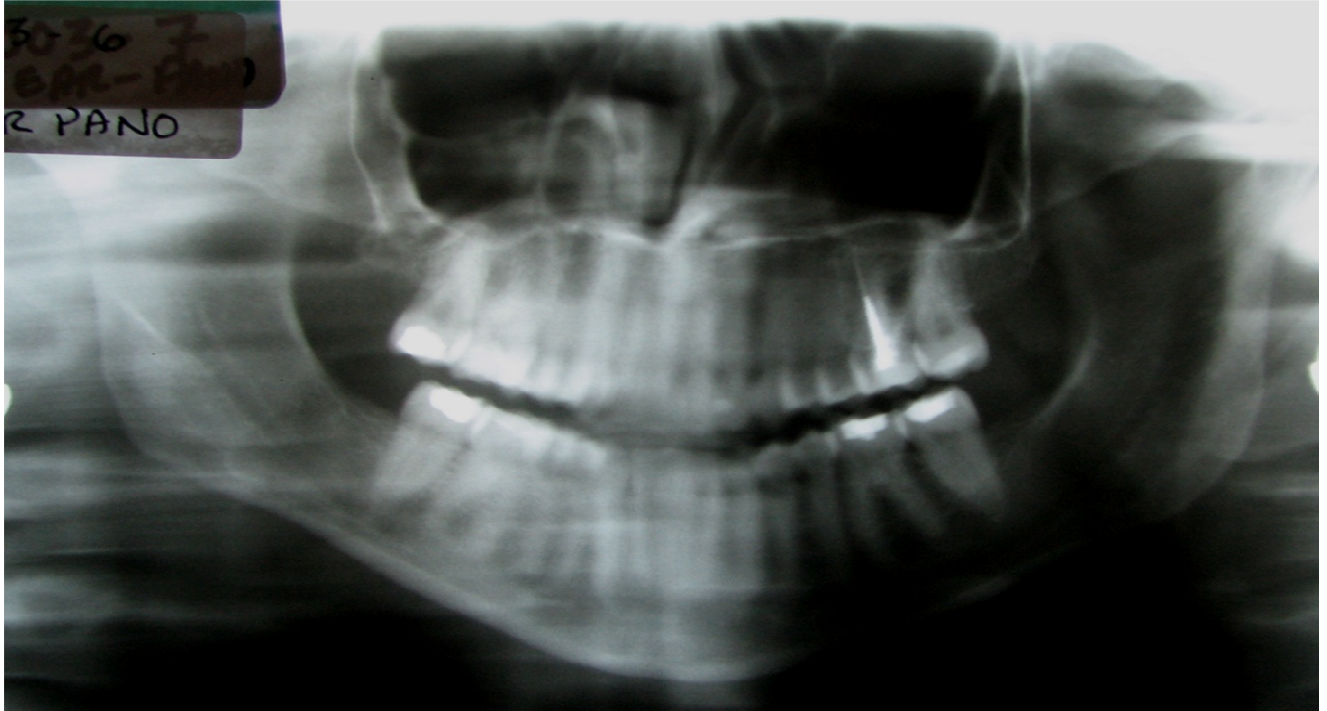


POST-TX PANORAMIC



(Note: metal object not removed, will affect “quality” score of radiograph)

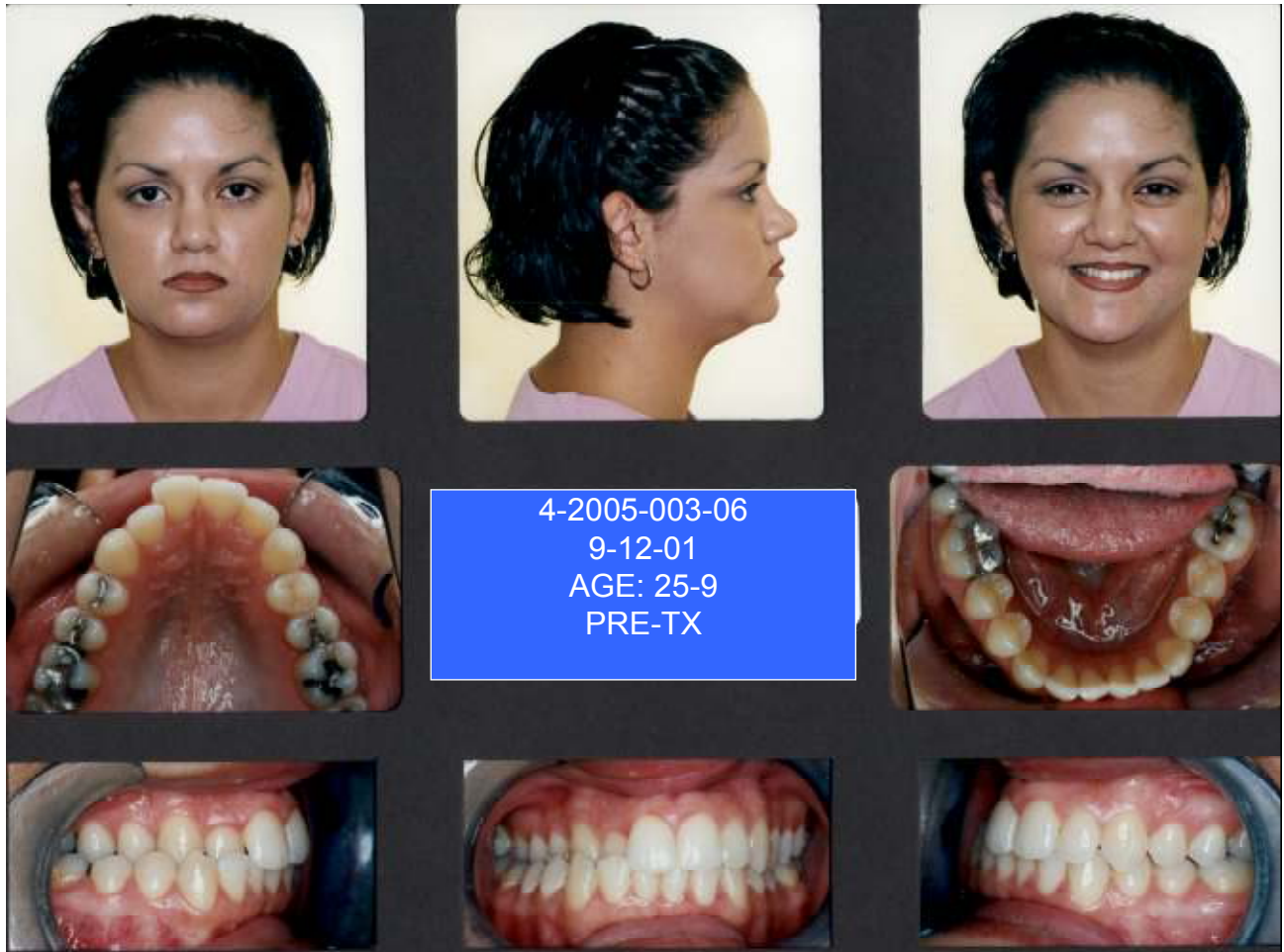2-YEAR POST-TREATMENT



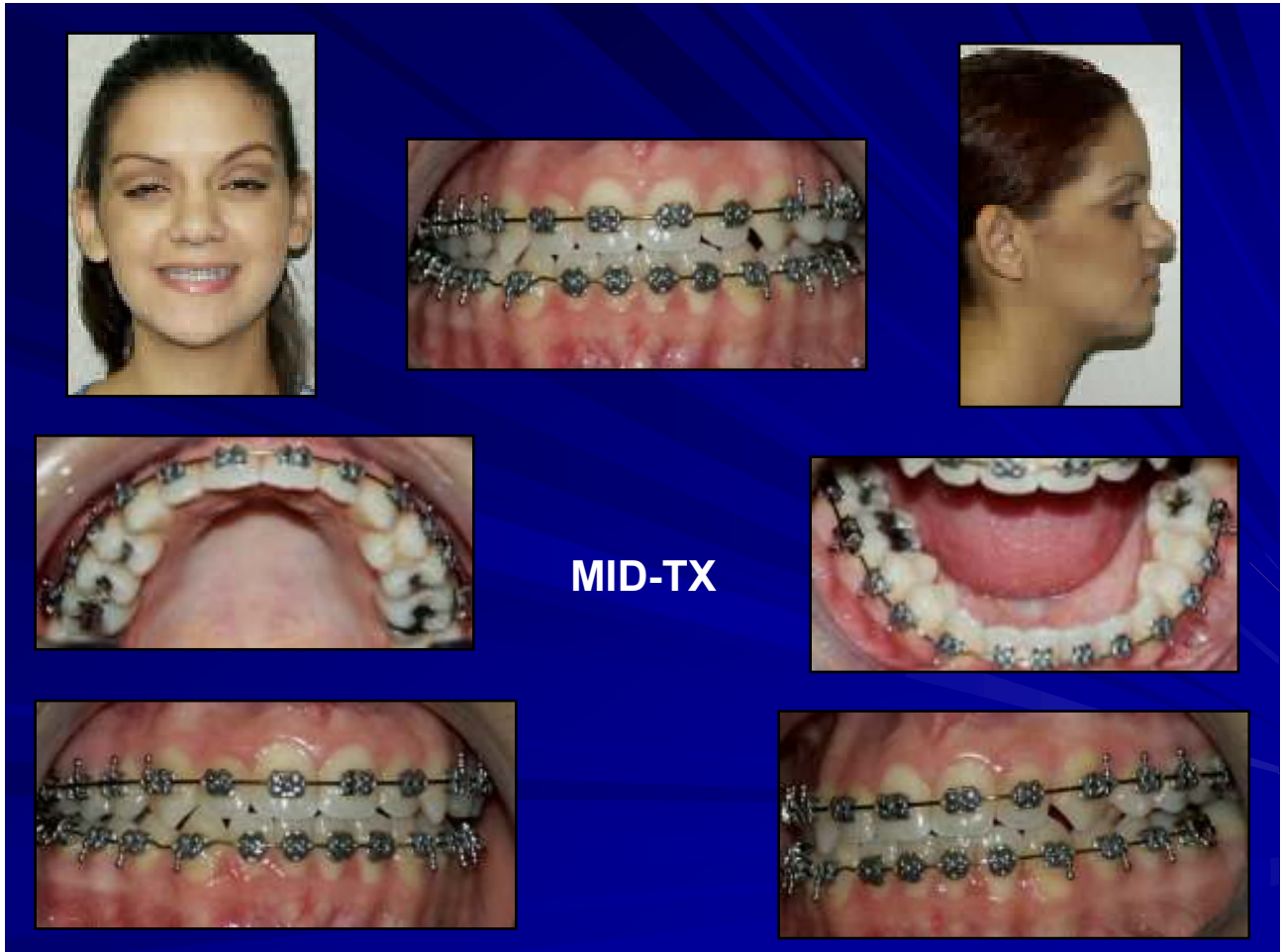(Note: poor angulation of patient resulted in poor quality of radiograph)

**Section V: Patient Photographs (1 of 2 points)**

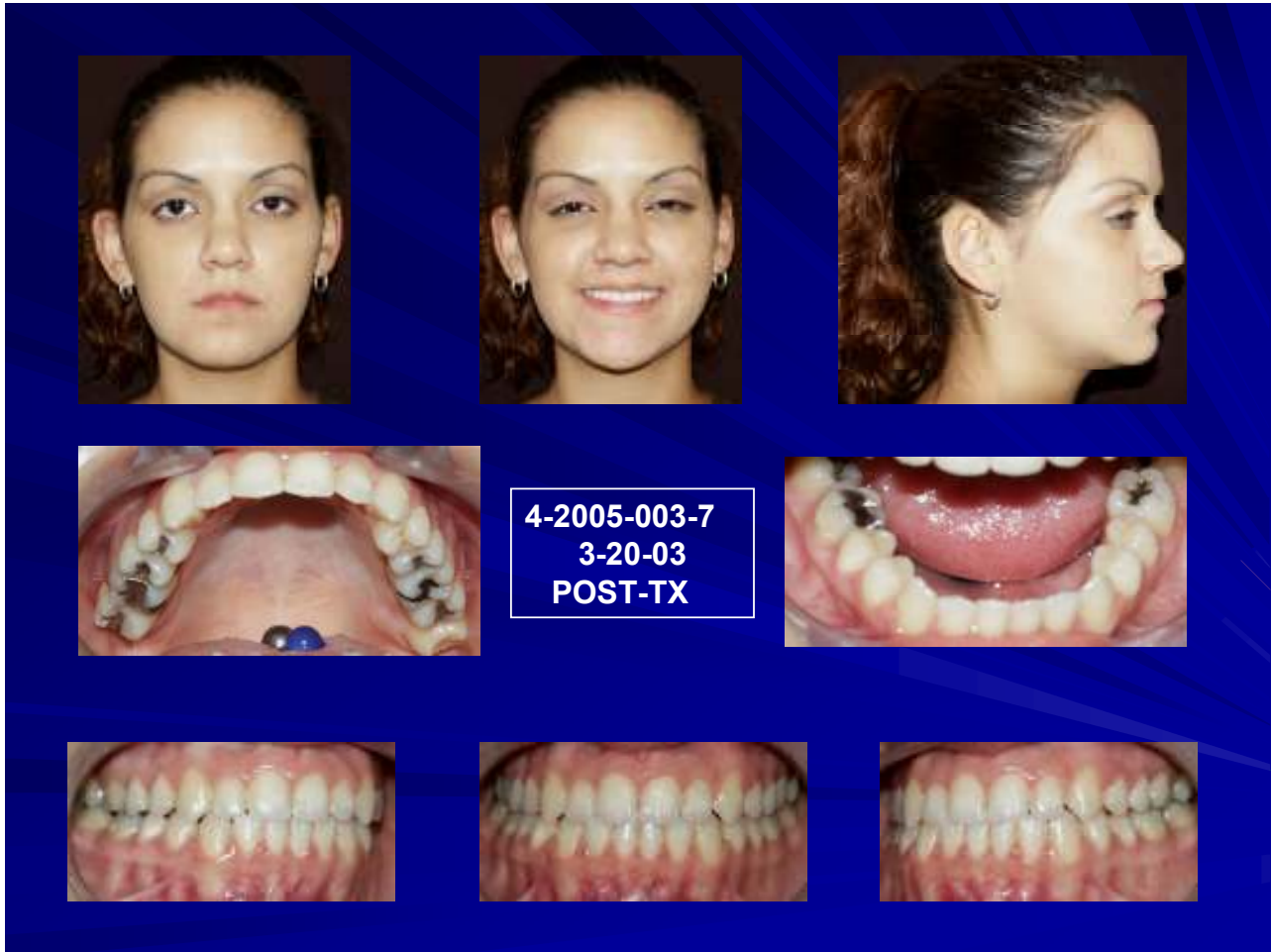PRE-TREATMENT



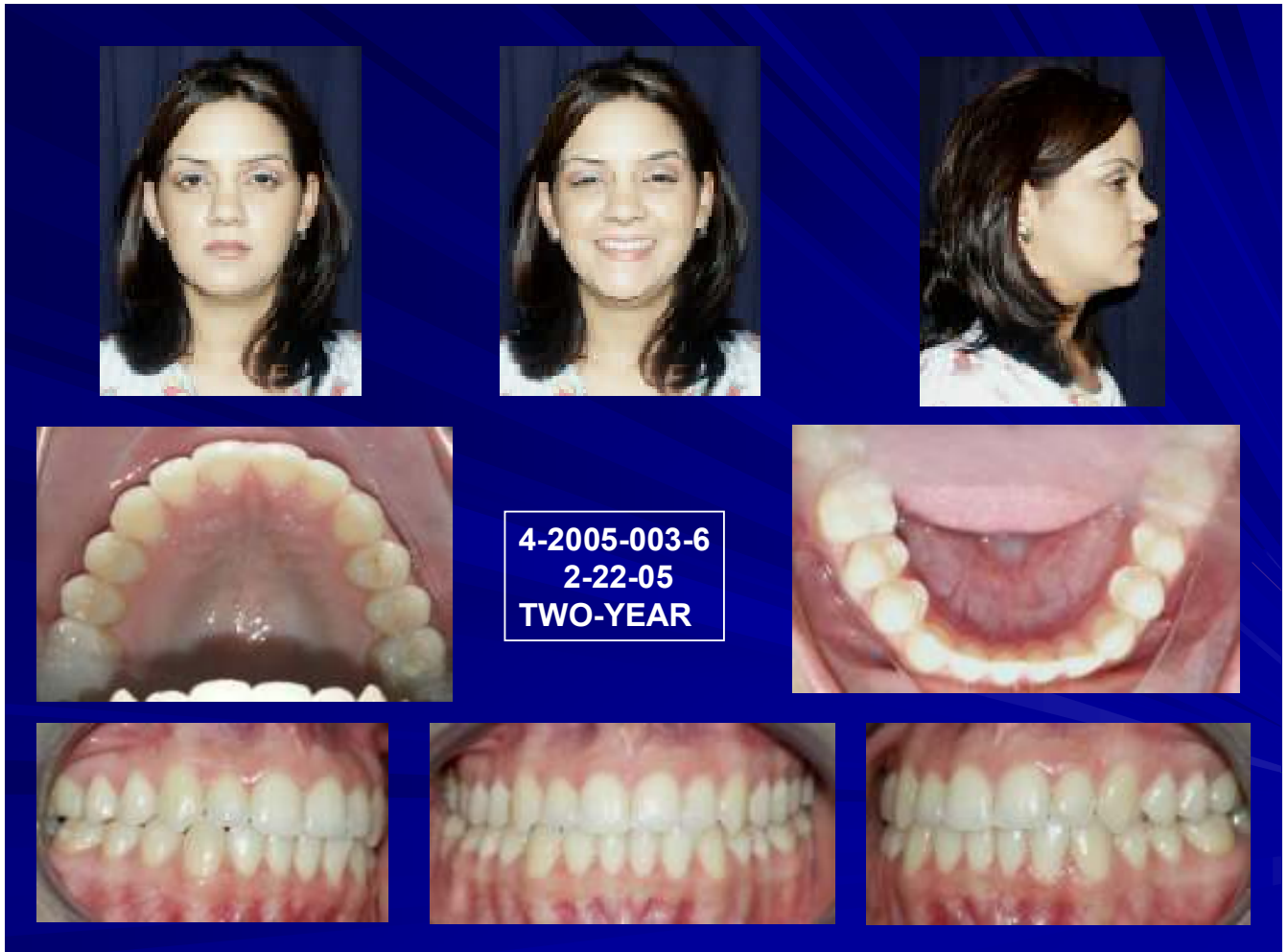MID-TREATMENT



POST-TX PHOTOGRAPHS

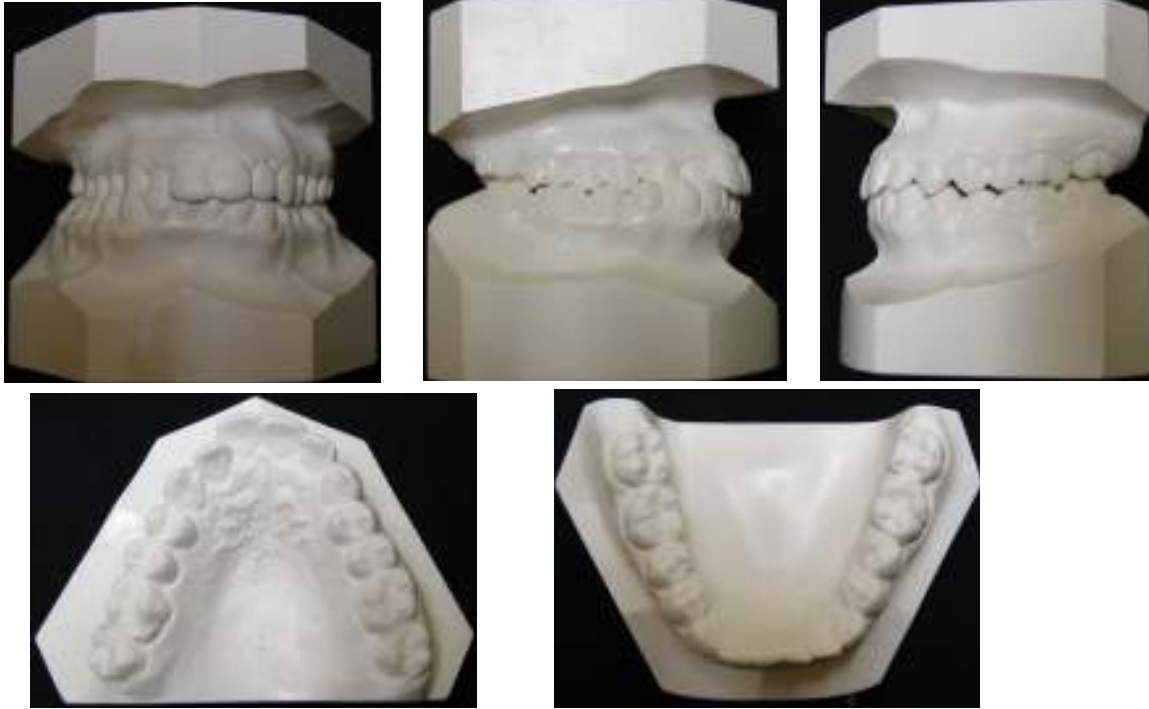

2-YEARS POST-TX PHOTOGRAPHS

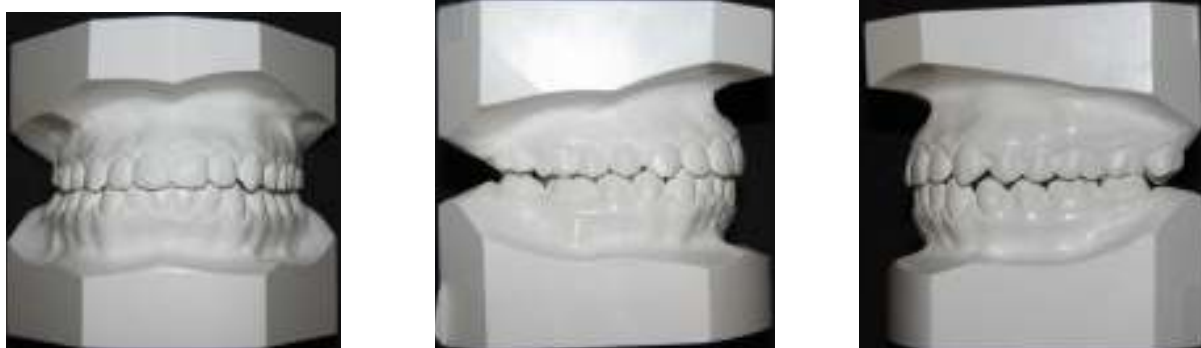

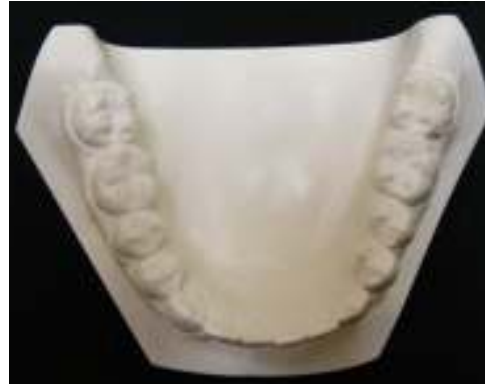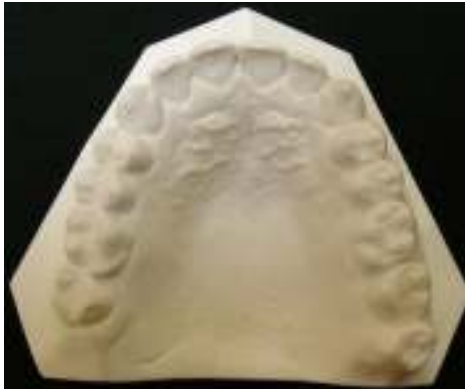**Section VI: Study Models (2 of 2 points)**

PRE-TX

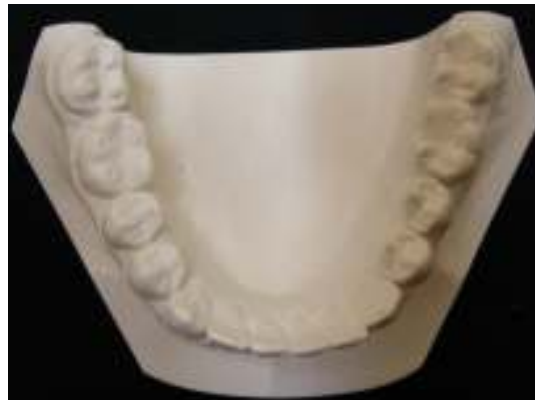
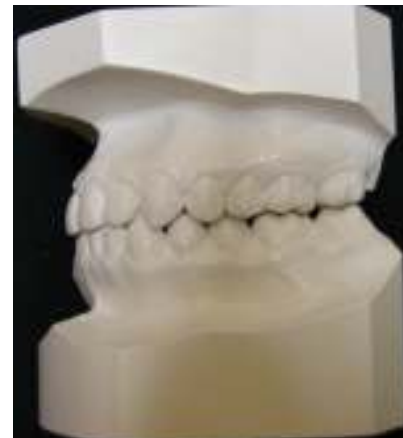
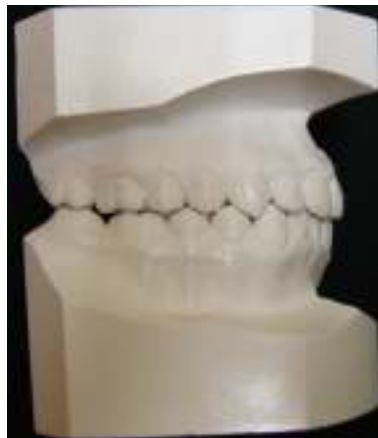POST-TX





2-YEAR POST-TREATMENT

**Section VII: Section Seven: Ceph Tracings, IBO Summary and Diagnosis (30 of 30 points)**

- Cephalometric Tracings (10 points):
- IBO Summary (each 2 points): (10 points)
- 3) Growth: Stage and Direction: Stage VI-no growth

- 4) Skeletal/Vertical Analysis: Mandibular low angle, slightly long lower face.
- 3) Skeletal/Sagittal Analysis: Class I skeletal
- 4) Dental Relations: Class III molars and left canine, Class I right canine.
- 5) Soft Tissue Profile: Straight



### IBO Cephalometric Data Sheet

Area	Norm	Pre Tx	Post Tx	2yr+Post Tx
<b>1-Growth</b> Stage - CVMS	Stage I-VI	Stage VI	Stage VI	Stage VI
Direction - Y-Axis	To SN = 66° +/- 2° To FH = 59° +/- 2°	SN=60° FH=59°	62 60	63 61
<b>2-Airways</b> Upper Airway Lower Airway	8-18 mm 10- 12 mm	14 mm 12 mm	14 12	14 12
<b>3-Vertical – Skeletal</b> FMA LAFH UFH/LFH SN – Go Gn	25° +/- 4° 58-72mm 45-55 % adult, 50-50% child 32° +/- 3°	20.5° 61 mm 43-57 % 28°	20 61 44/56 27	22 62 44/56 29
<b>4-Sagittal –Skeletal</b> a.Length Mnd - Max (Cond to Gn) - Cond to A Difference(mm): By Age  b. Wits (mm)  c. ANB(°)	Age: 6 – 9 – 12 – 14 - 16  17– 20 – 23 - 25 - 27mm  Class I = -1 to 3 mm Class II ≥ 4 mm Class III ≤ -2mm  Class I = 0-5° Class II > 5° Class III < 0°	25.9 Yr (115-90)  26 mm  Class I = +1 mm  Class I =+4	  28  -1  +2	  26  0.5  +3
<b>5-Dental</b> IMPA Interincisal Angle Mx incisor to SN Mn incisor to A-Pog	90° ±5 131° ±4 103° ±2 -1 to 3mm	96° 126.5° 109° 3 mm	91.5 128 111 3	90.5 127 109.5 2.5

6-Soft Tissue				
Rickett's esthetic Line	-2mm +/- 2mm (lower lip)	- .5mm	-2	-2
Naso-labial angle	102° ±8	103°	108	110.5
Lip seal	Do they have one?	Yes	Yes	Yes

### Case Diagnosis

1. GROWTH STAGE and DIRECTION: This is an adult patient (no growth potential, CVM Stage VI), this patient exhibits a history of a more horizontal growth direction (Y-axis SN 60)
2. AIRWAY: Normal airways (upper 14mm, lower 12mm).
3. SKELETAL: Mesocephalic asymmetric facial form (skeletal midlines off 2mm to the right) due to cross bite of the right side; constricted Mx arch form, broad lower arch (due to low tongue position and cross bite).
4. VERTICAL: FMA of 20.5° and SN-GoGM of 28° suggest a case on the "low" angle side together with a LAFH of 61 mm also indicate a short lower face. However, based on the ratio UF/LF (Upper Face to Lower Face 43% to 57%) this would suggest that the lower face is slightly long, but this patient appears to have a "short" upper face and thus the wrong "numbers" suggestion.
5. SAGITTAL: Class I Skeletal (ANB +4.0), Modified Harvold differential (26mm) and Wits +1.
6. DENTAL: Class III molars, class III cuspid right side and class I on the left, antero-posterior cross bite (UR 2-UR 6), no missing teeth, normal tooth size, 3 mm curve of Spee, no decay. No spaces, upper incisors slightly flared at 109 degrees to NS, lower incisors also slightly flared (96 degrees IMPA and 3mm to A-Pog), the Interincisal angle (126.5°) corroborates this slightly flared pre-treatment condition.
7. SOFT TISSUE: Facial features WNL, normal lip shape and lip seal (nasolabial angle 103), favorable lower lip support (normal labiomental angle), and no gingivitis. Both soft tissue profile evaluations (E-plane and S-line) would agree lip support is slightly deficient in this case.

8. TMJ: Full range of motion, max opening 53mm, both lateral movements ~11mm, protrusive 8mm, no deviation or deflection, no pain, no clicking, no crepitus, no popping.

### **Section VIII: Tx Plan- (10 of 10 Points) (each area 2 pts)**

#### **A. TX OBJECTIVE:**

- 1) Upper arch: A prime objective was to eliminate the cross bite, and in the process see how much the facial asymmetry could be corrected.
- 2) The lower arch primarily needed to have rotations corrected with proper torquing of the lower anteriors, this presented a special challenge because of the lower broad arch form (particularly on the right side, the cross-bite side), impacted directly what we needed to do to the upper arch; so this would require not only to try to develop the upper arch transversely but also try to “narrow” the lower arch, especially on the cross bite side.

#### **B. TREATMENT PLAN:**

- 1) Straight wire mechanics, in conjunction with a bonded Hyrax to disclude occlusion for bite correction and at a later time use Australian wire .020 to maintain “expansion” as we torqued posterior roots labially with SW Appliances. We aimed for skeletal midline congruence at the end of treatment obtained as we corrected cross bite. Treatment sequence will entail cementing upper appliance and simultaneously bond fixed appliances .022 Rx bracket system in development of the upper arch form; wires starting from .014 Niti, .018 Niti and .017x.025 NITI and SS, except on the lower arch due to the anterior open bite tendency will finish in .018 SS lower round wire.
- 2) Retention: Upper through the use of a Wraparound Hawley retainer to maintain palatal transverse development; lower through the use of an individually bonded lower 3-3 retainer with .0195 SS twist wire.
- 3) Estimated treatment time: 30 months.

- 4) Limitations, complications and prognosis: Prognosis will be guarded for this adult case, the limitation is due to the cross bite correction as an adult patient, most of these cases are treated with surgical separation of the palatal suture which this patient did not want to consider.
- 5) Evaluation of treatment progress: As in most treatment we propose to our patients we hope and expect cooperation and willing participation, the first resistance I had was with the “bonded” Hyrax cementation- appliance went “unbonded” due to patient concerns with OH, why I allowed it I can’t remember, nevertheless it accomplished the uncrossing, may have worked better had it been cemented. Once this expander no longer “fit” due to the tipping that was taking place on the right side, it was removed and a .020 SS wire I use called “Australian” to maintain the “expansion”; these were the only two methods I used to first expand and then maintain the arch development.

### **Section IX: Case Finishing and Treatment Results (33 of 40 points)**

- A. OJ/OB: 2mm/2mm
- B. Cuspid/Molar: Molars acceptable Class I, right cuspid Class I, **left cuspid Class II (-1 point)**
- C. Plane of Occlusion: Within norm
- D. 7's in occlusion: Yes
- E. Marginal Ridges: **UR4, LR7 (-2 points)**
- F. Rotations: **LR6, UL3 (-2 points)**
- G. Spaces: Closed
- H. Soft Tissue (Intraoral): Within norm
- I. Root Parallelism: **UL3, UL5 (-2 points)**
- J. Facial & Dental Midlines: Dental ok, Facial still off
- K. **SKELETAL**: No skeletal change according to Steiner she remains Class I (ANB +2.0 to ANB +3.5), also according to Wits +1 at start to Wits 0 at end, there was no skeletal change. The Modified Harvold differential of 25mm at the start and 27mm at the end (2mm

difference) is not a significant difference to make any comment on. The arch forms were nicely improved and broadened allowing us the desired bite uncrossing both anteriorly and posteriorly. Even though successful in our overall treatment goal, I do not like the final appearance of the buccal bone plate on the right side; it appears that our “expansion” was really molar tipping, not in any way real change to the bony housing. Both the Modified Harvold (26 mm difference at start between maxilla and mandible and 28mm at the end) as well as the McNamara (Nasion-perpendicular-Pg +5mm at start and +6mm at the end) suggest no real mandibular length change. The most important skeletal improvement is the improved facial symmetry.

- L. DENTAL:** Our attempt to uncross the bite was fairly successful (we had a difficult time with the UR area, obtaining more horizontal over jet). We ended with slightly more posterior horizontal over jet on the left side. This probably due to the difficulty in developing (“expanding”) the maxilla in adults; look at the bony contour of the right side vs. the left side, once again, it would appear that the teeth on the right side are “tipped” buccally. The overall occlusal scheme seems stable and will hopefully hold over time. Facial symmetry and esthetics were improved yet complete symmetry was not attained due to the fact that asymmetric development had already been set for years; another of the reasons why I support early treatment, when development is still taking place.
- M. TMJ:** No signs or symptoms, full range of motion at the end of treatment.
- N. RETENTION:** Maxillary QCM and bonded lower and nighttime parafunction appliance. At two-year evaluation patient now wears the same upper QCM and a lower parafunction appliance (lower Farrar-type).
- O. TX TIME:** Started 10-24-01, finished 3-20-03, active time ~17 months.

### **Section X: Case Analysis (10 of 10 points)**

**Facial Esthetics:** Improved; look at post-tx photos for improved facial asymmetry.

**Skeletal/Dental:** Other than the improvement in skeletal midline correction-no additional change.

**Superimpositions:** The Post-tx and Two-year superimpositions also appear to indicate this soft tissue profile change, interestingly all superimpositions seem to suggest a skeletal “closure” that cannot be quantified cephalometrically in any way.

**Difficulty of Case:** Case exhibited a moderate degree of difficulty.

**Tx Objectives Achieved or Not Achieved:** Do the results match the original treatment objectives? Yes, patient pleased at the end of treatment including the 2year follow-up results. Evaluation of the superimpositions Pre and Post treatment clearly demonstrate an apparent loss of lip support which could be explained as a result of the de-torqueing of the lower incisors. Two-year evaluation: Case appears to be “holding up” satisfactorily. Some slight relapse can be seen in the lower incisor area, but case intercusped well. At this point patient wears a lower nighttime parafunction appliance (full occlusal coverage) to control bruxism and serve as a lower retainer.

**Total points for this case: 90.5 of 100**

---

### Commentary on Case and Grading

It should be clear that even though this case has a few finishing details (marginal ridges, root parallelism) in the end it was still an acceptable diplomate case. Had the candidate neglected to “fill in” all of the necessary sections, conceivably this case may have not passed. So we encourage you to look carefully at all the sections use this sample provided and look forward to your successful completion of your Diplomate of the IBO.

This summary of results of the 2013 update to the Practice Analysis Survey is intended for informational purposes to help candidates better understand the development of the IBO Written Examination and how topics on the examination relate to relevant practice areas based on direct feedback from the IBO Diplomates who were surveyed.

---

**Practice Analysis Survey (*Results*) with Added Information from 2013 in *Red***

*The following survey is designed to identify which orthodontic treatment approaches are used in your office on a regular and ongoing basis. The information gathered from this survey will aid the International Board of Orthodontics in constructing a written exam for the Diplomate credentialing process. It is important that the information you provide is an accurate representation of what you do in your practice.*

*Please complete the survey and return it in the envelope provided. Thank You in advance for providing this information.*

Listed below are several diagnostic tools or processes used by practitioners to diagnose/assess patients. For each of these, please indicate whether you use them frequently, infrequently or not at all in your practice by checking the correct category.

Diagnostic Category	Frequency of Use		
	Frequently	Infrequently	Not at all
Medical History	33-7	0	0
Dental History	33-7	0	0
Clinical Photos	33-7	0	0
Panoramic Radiographs	32-7	0	1
Full Mouth X-ray Films	11-5	15-2	5-0
Cephalometric Analysis	33-7	0	0
Tomograms	2-2	15-3	14-2

Transcranials	5-1	17-2	10-4
Diagnostic Models	33-7	0	0
TMJ Evaluation	31-7	2	0
Airway Evaluation	28-6	4-1	0
Neuromuscular Evaluation	11-5	7-1	3-1
Growth Assessment			
1. Wrist Film	1-0	6-2	20-5
2. Cervical Vertebrae	8-3	4-3	17-1
3. Age and Sex	29-7	1	0
4. Direction of Growth	26-6	5-1	0
5. Racial Characteristics	24-6	4-0	1-1
Added- Soft-Tissue Profile Analysis	6	1	0
Occlusal Analysis	6	1	0

For the treatment approaches identified below, please respond using the same format as in the diagnostic categories above.

### Treatment Modality

### Frequency of Treatment

	Frequent	Infrequent	Not at All
Skeletal Cases:			
1. Class I	33-7	0	0
2. Class II	33-7	0	0
3. Class III	21-5	12-2	0
4. Excess Vertical Dimension	18-6	12-1	3
5. Compromised Airway	23-6	9-1	0
Functional Cases:			
1. Primary Dentition	17-7	14	2
2. Mixed Dentition	32-7	1	0
3. Permanent Dentition	26-7	6	1

## Surgical Cases:

1. Tooth removal	10-5	22-2	1
2. Impactions	16-4	17-3	0
3. Orthognathic surgery	3-1	13-5	17-1
4. Implants for anchorage	1-3	10-1	21-3

## Limited or Compromised Treatment:

1. Relapse cases	6-5	27-2	0
2. Habit cases	15-6	18-1	0
3. Minor Tooth movement	15-6	18-1	0

## TMD Cases:

9-3	10-3	3-1
-----	------	-----

## Added-Partial Adontia

3	4	0
---	---	---

## Types of Mechano-Therapy used:

1. Fixed appliances	33-6	0-1	0
2. Removable appliances	24-5	9-2	0
3. Headgear	5-1	10-2	17-4
4. Facemasks	8-2	17-3	8-2
5. Retention	33-7	0	0
6. Invisalign	4-0	8-4	21-3
7. Air Rotor Reduction	11-3	19-2	2-2

## Choices of Fixed Mechano-Therapy:

1. Edgewise	7-1	4-0	15-6
2. Straightwire	27-6	1-0	4-1
3. Tip-Edge	6-1	2-0	18-6
4. Controlled Arch	8-2	5-1	13-4
5. Ancillary Appliances			
A. Hyrax	14-5	11-1	5-1
B. Herbst	6-1	8-1	15-5
C. Mara	3-2	5-1	20-4
D. Other	19-4	3-0	5-3

Please indicate below the frequency with which you treat patients in the age categories identified below.

<b>Age of Patient Treated:</b>	<b>Frequently</b>	<b>Infrequently</b>	<b>Not At All</b>
1. 3-5	1-2	26-3	5-2
2. 6-10	29-7	4	0
3. 11-18	33-7	0	0
4. 19 plus	27-7	6	0

In the course of providing orthodontic care in your practice, how often do you consult with each of the specialists identified below?

	<b>Frequently</b>	<b>Infrequently</b>	<b>Not At All</b>
1. Speech Therapist	1-0	21-6	11-1
2. Chiropractor	6-0	14-5	13-2
3. Myofunctional Therapist	5-1	15-4	12-2
4. ENT (Otolaryngologist)	11-3	19-4	3-0

**Added:**

**Surgical**

<b>Implant</b>	4	2	1
<b>Orthopedic</b>	3	1	3
<b>Periodontic</b>	4	2	1

In the box below, please add any diagnostic or treatment approaches you commonly use in the course of treating orthodontic patients in your practice. Please clearly indicate the category to which your comment applies.

### **Additional Diagnostic or Treatment Approaches**

These are provided on a separate attachment.

This Table of Specifications Worksheet is intended for informational purposes to help candidates better understand the development of the IBO Written Examination and how topics, represented by item numbers in the table below, relate to relevant knowledge/content areas.

**Table of Specifications Worksheet for IBO  
Diplomate Exam 2013 – Identified by Item Number**

<b>Content Area</b>	<b>Knowledge</b>	<b>Application-Analysis Evaluation</b>
<b>General</b>	<b>29-30-33-39-42</b>	<b>61</b>
<b>Growth &amp; Development</b>	<b>28-29-42-49-58</b>	<b>1-2-10-12-14-15-61-63-74</b>
<b>Bone Physiology</b>	<b>29-38-43-44-57-58</b>	
<b>Patient Management</b>	<b>52-55</b>	<b>23</b>
<b>Occlusion</b>	<b>27-31-46-51-54</b>	<b>18-31-73-83</b>
<b>TMJ</b>	<b>52</b>	<b>45</b>
<b>Neuromuscular</b>	<b>50</b>	
<b>Mechanics</b>	<b>34-35-41-43-44-47</b>	<b>23-32-75-85</b>
<b>Functional Orthopedics</b>	<b>49</b>	<b>4-19-64-65-70-82-87</b>
<b>Content Area</b>	<b>Knowledge</b>	<b>Application-Analysis Evaluation</b>
<b>Stability/Retention</b>	<b>37-42-51</b>	<b>26-87-90</b>
<b>Clinical Records</b>	<b>28</b>	<b>6-8-24-25-53-60-66-67-68-69- 70-71-77-81-82-84-86</b>

<b>Diagnosis</b>	<b>52-53-54-56</b>	<b>1-2-3-5-7-11-12-15-16-21-24-62-66-67-68-75-76-81-84-85-91-92</b>
<b>Treatment Objectives/Planning</b>	<b>37-48</b>	<b>4-7-10-13-20-21-45-59-64-73-78-85-88-89-93</b>
<b>Treatment Modalities</b>		<b>7-8-9-14-19-22-59-65-89-93</b>
<b>Skeletal Relation</b>	<b>27-48</b>	<b>1-2-3-5-8-9-16-22-77-80-84-92</b>
<b>Dental Relation</b>	<b>27</b>	<b>16-18-66-83</b>
<b>Functional and Parafunctional TX</b>	<b>55-71-76</b>	<b>17</b>
<b>Special/Limited Cases</b>	<b>33-38-39</b>	

**Note: Items are found under multiple categories as the distinctions associated with treatment are not always clearly separate.**